CATARACT

THE TREATMENT OF CATARACT

AND SOME OTHER COMMON OCULAR AFFECTIONS

BY

LIEUT.-COLONEL HENRY SMITH, C.I.E., B.A., M.D., M.CH.

INDIAN MEDICAL SERVICE (RETIRED), LONDON

Late Civil Surgeon of Jullundur and Amritsar, (Punjab, India).

WITH THE COLLABORATION OF

LT.-COL. A. E. J. LISTER, F.R.C.S., I.M.S. (Retd.), LONDON

DR. ARNOLD KNAPP, NEW YORK

AND

DR. J. RUSSELL SMITH, LONDON.

ILLUSTRATIONS BY

DR. DERRICK T. VAIL

Professor of Ophthalmology, University of Cincinnati

AND

DR. J. RUSSELL SMITH, LONDON.

CALCUTTA :

BUTTERWORTH & CO. (INDIA), LTD., 6, HASTINGS STREET.

MADRAS BRANCH : 317, LINGA CHETTY STREET.

BOMBAY BRANCH : JEHANGIR WADIA BUILDING, ESPLANADE ROAD.

1928

PREFACE

If he were alive, I would have had to thank the late Dr. Herman Knapp of New York, who wrote to me, on receiving the paper published in his *Archives of Ophthalmology*, Feb. 6th, 1905: "If you can establish a safe method of intracapsular extraction of cataract, you will be a greater benefactor to mankind than Daviel. If I were not over 70 years of age and in infirm health, I would go round the world to see how to do it."

This was the first word of encouragement I had received from any Ophthalmologist of standing, the general attitude I had met with elsewhere being represented by the words of the President of the Opthalmological Section of the Meeting of the British Medical Association held in Swansea in 1903. In calling for discussion of substantially the same paper as that referred to above, he said: "I believe there is a deep-rooted opposition to this procedure in the meeting." The result was silence—a douche of cold water. With the lapse of time this attitude—though held to for long with tenacity—is, I am happy to say, rapidly changing.

The first edition of this monograph, published in 1910, was not as well rounded off as I would have liked it to be, had I had more time at my disposal. The views expressed in it were entirely my own, based on an experience at the time of some 25,000 cases, and appeared perhaps a trifle dogmatic to those who are accustomed

to read what are essentially compilations—productions which, by their very nature, cannot express opinions strongly. It, however, served its purpose—that of setting the Ophthalmological profession to think seriously on the subject of intracapsular extraction of cataract. The outcome was the introduction of various types of capsule forceps in an endeavour to simplify the technique of the operation, the method originally described by me being found to be beyond the scope of those working under Western conditions, with their limited opportunities of acquiring the necessary manipulative skill.

This second edition has been entirely rewritten and brought up to date. The latest development of the Indian method (described on pages 102-123) constitutes a revolution of the greatest importance. It reduces the procedure to a simplicity hitherto undreamt of, enabling it to be performed in relatively unskilled hands—not merely with a lower incidence of prolapse of vitreous than the capsulotomy operation when, in the latter, adequate attention is paid to clearing the eye of cortical lens matter, but even without that rupture of the hyaloid membrane, which is an inevitable result of interfering with an after-cataract. It is, in my opinion, destined to supersede all other methods at present in vogue, and eventually to relegate Daviel's operation in the rest of the world to the position which it now occupies in the Punjab—that of a memory of the Fathers—a matter which is fully discussed in Chapter IV.

In this connection the translation, contained in the Appendix, of Daviel's original paper on cataract (from the *Memoirs* of the Royal Academy of Surgery in Paris) should be of interest. For this I am indebted to the late Dr. D. W. GREEN of Dayton, Ohio.

I have much pleasure in thanking Lt.-Col. A. E. J. LISTER, F.R.C.S., I.M.S. (*Retd.*) and Dr. ARNOLD KNAPP of New York for their papers in the Appendix, Dr. DERRICK T. VAIL of Cincinatti and Dr. J. RUSSELL SMITH for the illustrations, and Dr. J. RUSSELL SMITH for the section dealing with Barraquer's operation. I am indebted to the *Archives of Ophthalmology* and the *British Journal of Ophthalmology* for permission to reprint certain papers originally published by them, and to Messrs. DOWN BROS. for the loan of the blocks for the illustrations of the instruments.

HENRY SMITH, C.I.E., B.A., M.D., M.CH.,
LT.-COL., I.M.S., (*Retd.*)

"Blenheim,"
SIDCUP, KENT.

CONTENTS

PAGE

CHAPTER I

Clinical Examination of the Eye — — 3
Classification and Diagnosis of Cataract — — 8
The Treatment to which Each Variety is Suited — 38

CHAPTER II

Operative Technique — — — 59

CHAPTER III

Routine After-Treatment — — — 171

CHAPTER IV

A Short Account of Lens Couching as Performed by the Rawals: Some Observations on the Historical Aspect of the Surgical Treatment of Cataract — — 201
A Consideration of the Relative Merits of Intracapsular Extration and the Capsulotomy Operation — 210

CHAPTER V

The Treatment of Glaucoma and Some Other Common Ocular Affections — — — 219

PAGE

APPENDIX

Details of Vision in 132 Cases of Intracapsular Extraction of Cataract on Discharge from Hospital—By Lt.-Col. Henry Smith, C.I.E., I.M.S. (*Retd.*) — 237

The After-effects of Escape of Vitreous during the Operation of Extraction of Cataract in the Capsule by Smith's Method, with an Analysis of 98 Cases so Complicated—By Lt.-Col. A. E. J. Lister, F.R.C.S., I.M.S. (*Retd.*) — — — — 242

Late Results of Intracapsular Extraction—By Dr. Arnold Knapp, New York — — — 258

On a New Method of Curing Cataract by Extraction of the Crystalline.—M. Daviel's Original Paper in the *Memoirs* of the Royal Academy of Surgery, Paris, Tome II, 1748 (Translated by the late Dr. D. W. Greene of Dayton, Ohio) — — — 264

LIST OF ILLUSTRATIONS

Fig. 1—Taking the Ocular "Tension."

Fig. 2—States and Lines of Development in Senile Cataract.

Fig. 3—Instruments.

Fig. 4—The Correct Grasp for Introducing the Speculum.

Fig. 5—Exposing the Conjunctival Fornices for Irrigation.

Figs. 6, 9—Position of the Assistant's Hands in Controlling the Lids during Expression of the Lens.

Fig. 10—Eyebrow Stitch to Control Orbicularis.

Fig. 11—Adjustable Head Band Support for Upper Lid Hook.

Fig. 12—Position of Left Hand in Steadying the Eye for Section.

Figs. 13, 16—Grasp of the Knife and Movements of the Hand in Making the Section.

Figs. 17, 19—Showing Effects of Entering Knife Correctly and Incorrectly at Puncture and Counterpuncture.

Fig. 20-26—Movements of the Knife and Fixation Forceps in Making the Section.

Fig. 27—Sizes of Incision.

Fig. 28—End Results as regards Shape of the Pupil after Extraction.

Fig. 29—Types of Iridectomy.

Fig. 30—Grasping the Iris for Complete Iridectomy.

Fig. 31—Cutting off the Iris.

Fig. 32—Hess Peripheral Iridectomy Forceps.

Fig. 33—Correct Method of Making Hess Iridectomy.

Fig. 34—To Show How as much Violence is Inflicted on the Eye when the Lens is Dislocated by Direct Traction on the Capsule as when it is done by Pressure from Without.

Fig. 35—Upright Delivery of an Easily Dislocated Hard Cataract.

Fig. 36—Upright Delivery of a Less Easily Dislocated Hard Cataract.

Fig. 37—Use of the Spoon when Vitreous Presents in Upright Delivery.

Fig. 38—Delivery of the Morgagnian (Soft) Cataract as a "Tumbler," *i.e.*, Lower Edge Foremost.

Fig. 39—Separating the Final Attachments of the Suspensory Ligament in a Cataract which has been a "tumbler."

Fig. 40—Misapplication of Pressure (as in Fig. 38) in an Attempt to Make a Hard Cataract "Tumble."

Fig. 41—Pressure on the Sclerotic Below.

Fig. 42—Tumbling the Hard Cataract by Combined Pressure with Spoon and Lens Hook.

Fig. 43—Misapplication of Combined Pressure.

Fig. 44—Reposition of the Iris.

Fig. 45—Trimming off an Escape of Vitreous.

Figs. 46, 47—Removing a Burst Capsule.

Figs. 48-50—Barraquer's "Erisifaco" or Vibratory Vacuum Pump and Pneumatic Forceps.

Figs. 51-53—Diagrams to Illustrate Method of Production of the Vibrations.

Fig. 54—Physical Experiment by Prof. T. Esreche, on the Basis of which are Founded the Claims for the "Vibrations" (*Reproduced from Barraquer*).

Fig. 55—Illustrating what the "Vibrations" are Claimed to Do (*Reproduced from Barraquer*).

Fig. 56—State of the Eye after "Facœrisis" Daviel's Operation and Intracapsular Extraction by Smith's Method (*Reproduced from Barraquer*).

Fig. 57—Down's Mercury Vacuum Apparatus.

Fig. 58—Alleged Effect of Applying Vacuum (*Reproduced from Barraquer*).

Fig. 59—Actual Sequence of Events when Vacuum is Applied.

Fig. 60—Natural Planes of Cleavage in the Structures which Anchor the Lens to the Fibrous Coats of the Eye.

Fig. 61—The Vitreous Removed from the Eye (*Reproduced from Barraquer*).

Fig. 62—Dislocating the Lens with the Vacuum Forceps by Pushing it into the Vitreous.

Fig. 63—*Reproduced from Barraquer.*

Fig. 64—Upright Delivery of the Lens wtih the Pneumatic Forceps (*Reproduced from Barraquer*).

Fig. 65—Delivery of the Lens as a "Tumbler" with the Pneumatic Forceps (*Reproduced from Barraquer*).

Fig. 66—Pneumatic Forceps of Stoewers (1906).

Fig. 67—Use of the Mechanical Capsule Forceps.

Fig. 68—The Iridectomy for Glaucoma.

CHAPTER I

1. Clinical Examination of the Eye
2. Classification and Diagnosis of Cataract
3. The Treatment to which Each Variety is Suited

CHAPTER I

CLINICAL EXAMINATION OF THE EYE.

The student should, by careful and repeated observation, impress on his mind a picture of the naked eye—the appearance in health of the conjunctiva, the sclerotic, the cornea, the sclero-corneal junction, the depth of the anterior chamber, the iris and its lustre, the pupil, its size and its reaction to light.

It is just as necessary for the ophthalmic surgeon to have an exact mental impression of these points as seen in health, and to notice any departure therefrom with the quickness and ease of intuition, as it is for the physician to have fixed in his mind the normal sounds of the chest.

The student of this subject should be obliged to do a course of observation with the naked eye. It should be seen that he is thoroughly competent in observing all that is to be seen with the naked eye in health and in disease before he proceeds to use instruments for further observation.

The information which is to be gained at a glance in this way by a trained eye is more far-reaching than is commonly thought. It should be used as a mental guide to what the observer is to expect on examining with instruments. In this way the observer

CHAPTER I

CLINICAL EXAMINATION OF THE EYE.

The student should, by careful and repeated observation, impress on his mind a picture of the naked eye—the appearance in health of the conjunctiva, the sclerotic, the cornea, the sclero-corneal junction, the depth of the anterior chamber, the iris and its lustre, the pupil, its size and its reaction to light.

It is just as necessary for the ophthalmic surgeon to have an exact mental impression of these points as seen in health, and to notice any departure therefrom with the quickness and ease of intuition, as it is for the physician to have fixed in his mind the normal sounds of the chest.

The student of this subject should be obliged to do a course of observation with the naked eye. It should be seen that he is thoroughly competent in observing all that is to be seen with the naked eye in health and in disease before he proceeds to use instruments for further observation.

The information which is to be gained at a glance in this way by a trained eye is more far-reaching than is commonly thought. It should be used as a mental guide to what the observer is to expect on examining with instruments. In this way the observer

gets all initial facts available except those told him by the patient and by his finger tips. The training of the finger tips in determining tension is equally important. They confirm much of what his eye tells him, and he can make a delicate estimate if they are trained in the art. (Fig. 1.)

My experience of men who have just completed a course of study at ophthalmic teaching hospitals is that at the end of it they are often unable to notice with the naked eye gross deviations from the appearances of health. They can use the ophthalmoscope and the retinoscope. They can describe conditions of the fundus and correct errors of refraction. They know all about ophthalmic instruments and could do any examination on paper. But if put before a patient with only their naked eye and without being allowed to ask questions, their capacity for seeing what is at once evident to a trained eye is often very little.

The naked eye, if trained, leaves exceedingly little, in cataract, for other instruments of observation to discover. In mature cataract I have seldom occasion to reinforce the naked eye with any weapon other than the finger tips, and even then the degree of tension can be predicted from the general appearance. In the case of immature cataract it may be necessary to examine by oblique illumination or by reflected light to see the degree to which the opacity has developed.

In examining any cataractous eye the first and most important point upon which to make up one's mind, before deciding on the line of treatment, is as

Fig. 1

Showing the method of taking the "tension" by means of the tip of the index finger laid directly against the eyeball below the cornea

This is a painless method and gives a very accurate idea of what the tension is, more especially if the finger nail itself is used, being kept long, not cut short, as shown in this drawing.

to the condition of the fundus. In estimating this we have two guides—the perception of the recognition of projection of light and the reaction of the pupil to light.

The recognition of light should be tested in mature cataract by drawing the fingers of the opened hand across in front of the eye in a good light. The patient will recognise that something is moving, or may be able to count the fingers. And even more important is to watch the eye itself as this is done, when it will be seen to move from side to side following the movement of the hand. Once this is recognised it can never be confused with the aimless twitching of a blind eye. In India this is important, for patients will often endeavour to cheat us in ascertaining the recognition of light, in the hope that we may be induced to operate upon an eye which has gone completely blind.

The reaction of the pupil, provided the iris is not bound down by adhesions nor dilated by mydriatics, is in general as good an indication of the visual function of the retina as the galvanometer is of the strength of an electric current. It has the advantage over the recognition of light that it is completely independent of the patient's control. In many cases this is to be desired, for the patient's subjective estimate, even when he is not deliberately cheating, often lacks scientific accuracy. If the iris is bound down by adhesions completely, we have to depend on the recognition and the projection of light reinforced alone by the general appearance of the eye, and especially of the lustre of the iris.

To evaluate the reaction of the pupil requires, however, some training, and local conditions are to be taken into account. For instance the reaction in Morgagnian cataract might be confusing to the novice. It is normal in range, but often sluggish owing to mechanical obstruction from the pressure of a swollen lens. The contracted pupil of the opium-eater at first sight seems not to react at all. This is because its range of contraction and dilation is very small, and at the same time when the actual contraction occurs the observer must be himself quick to see it, for it reacts with characteristic lightning quickness.

Moreover, it must not be assumed, that the reaction of the pupil is an infallible guide to the condition of the fundus any more than the ophthalmoscope. I have often seen a large central scotoma in which the reaction of the pupil was perfectly normal. Put this fact alongside the progressive slowing of the pupillary reaction in night-blindness, proceeding *pari passu* with the spread of the disease from the periphery towards the macula, and in consequence with the diminution of the field of vision. We then see that the sensory side of the reflex arc which subserve the pupillary reaction is situated in the periphery of the retina, and that the macula has but little importance in this respect. I am aware that this is not orthodox teaching, but it is the only theory which will explain the facts of night-blindness and a central scotoma. These are clinical facts which are beyond dispute. No theory will hold water for a moment which does not take them into account.

Night-blindness has always been a constant source of malingering among Indian troops. Knowledge of the close correspondence between the degree of sluggishness of the pupillary reaction and of contraction of the field of vision at any stage of the disease enabled me, when Consulting Ophthalmic Surgeon to His Majesty's Forces in Mesopotamia during 1916, to wipe out malingering from this source completely among certain Indian troops. So cleverly had they been coached by some dishonest medical subordinates, into whose hands had fallen a circular which I had issued, that they were feigning extreme contraction of the field of vision. But when they were brought to me, the reaction of the pupil to light as well as the condition of the fundus were absolutely normal. When told the verdict, they promptly admitted the bill.

In the discussion following a paper which I read on this subject, at the annual meeting of the American Ophthalmological Association, held in Boston in 1921, it was stated that they had rejected 150,000 of the American conscripts for service during the Great War on account of night-blindness. Consider with this the fact that during the Great War this condition accounted for 8.2 per cent. of the medical rejects in France, and 10.9 per cent. in Germany, while during peace time the normal incidence among the young men called up for their period of training, had been 1 in 12,000.

It is clear that this must have been a fruitful source of malingering in all those countries. It is also clear that the profession were ignorant of this close relation-

ship between the slowing of the pupillary reaction and the narrowing of the field of vision. Had they been aware of it, they would have made use of it.

I should here like to pay a well deserved tribute to Thomas Atkins. I did not come across a single case either of malingering with night-blindness or of the disease itself among the British troops in Mesopotamia. And I think I am correct in stating that it figured equally little among the British troops in other centres of war.

CLASSIFICATION AND DIAGNOSIS.

Having dealt fully with these preliminary diagnostic points I now come to a general classification of cataract. The one which I adopt is as follows :—

A. PRIMARY CATARACT is cataract of whose ætiology and causation we are ignorant.

B. SECONDARY CATARACT is that dependent on local disease of the eye or general constitutional disease.

C. COMPLICATED CATARACT is primary cataract complicated by local or general disease.

A. PRIMARY CATARACT.

I. CONGENITAL.

II. ACQUIRED—

(*a*) *Juvenile.*

(*b*) *Senile.*

I will consider Primary Senile Cataract first as being the most important. The following is the line of sub-classification I adopt :—

SUB-CLASSIFICATION OF PRIMARY SENILE CATARACT.

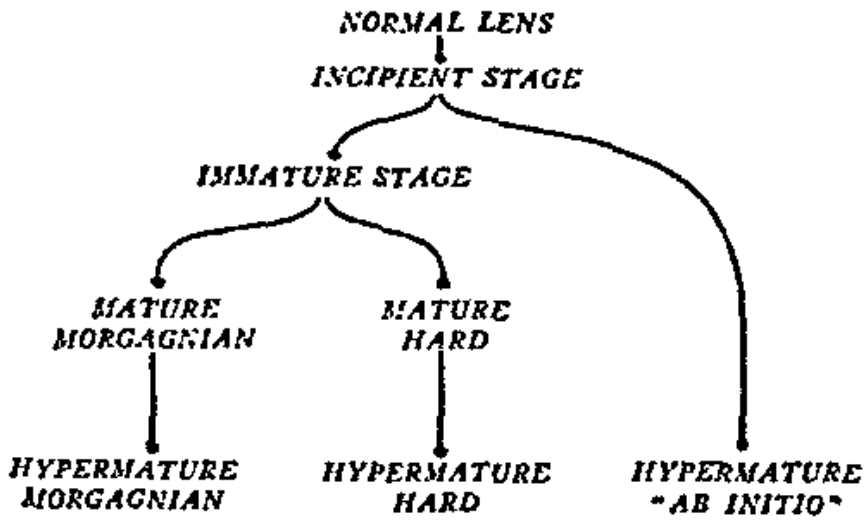

The classification which is adopted here is drawn up entirely on a physical basis, with a view to assisting the prediction of how a given lens will behave at operation. Senile cataract may be considered on the lines of a family tree. The parent trunk is the normal lens which extends upwards into the Incipient or Prodromal stage. Here the first and a small branch parts off which I clasify under the head of "Hypermature *ab initio*." The main trunk still continues till the stage of IMMATURE CATARACT is reached, where another branching takes place. The largest branch is represented under the type HARD, the smaller under the type MORGAGNIAN, and each of these passes through a mature and a hypermature stage. (Fig. 2.)

I. The Incipient or Prodromal Stage.

Cataract is a degenarative process in the lens, whose causes are a matter of pure speculation. But these causes are at work and leave their trail for those who look to see, long before any definite opacity develops. The optical effect in this incipient stage is a slight uniform reduction in the power of the lens to transmit light, not affecting any one part more than another. This optical deterioration manifests itself in a very definite set of symptoms and signs.

The main subjective symptom is a gradual failure of *distant* vision. Near vision is not reduced to an extent which gives rise to any inconvenience until the stage of immaturity is reached with the presence of a definite opacity. And in many instances the work of the patient is such that he suffers no inconvenience from loss of distant vision and its onset is so gradual that he is not aware that it has taken place. It is only in the case of men to whom good distant vision is essential, such as sportsmen, big game hunters, railwaymen or seamen, that this loss brings them early to the doctor. It was in the capacity of medical officer to the staff of Jullundur and Amritsar railways that my experience in the treatment of this case was mainly gained.

The diminution of vision is steadily progressive, loss of distant vision alone being noticed subjectively and the reduction of near vision giving rise to little inconvenience till it is less than 6/10. When the stage of immaturity is reached, a certain opacity is developed,

which is reponsible for the apparent paradox that the patient sees better in a dull than a bright light, owing to the pupil dilating in the former and uncovering the more transparent peripheral portion of the lens. In the incipient stage no such paradox is present. He still sees better in a bright than in a dull light.

The sole objective sign in the very early stage, while vision is above 6/10, is to be found by indirect ophthalmoscopy after dilating the pupil with a weak mydriatic, using a +10D or +13D spherical lens in front of the eye to see the fundus. There are as yet no opacities present anywhere in the lens. The details of the fundus are seen; but if there is a healthy eye beside for comparison, it is at once evident that they are not as obvious in the cataractous eye as in the latter. The appearance is as if we were examining a normal fundus with a very poor source of illumination, though we are using a good light.

As the condition progresses, the general loss of transparency of the lens increases, and the first small circumscribed opacities appear. These take the form of a few black sand-like particles, usually situated in the periphery of the lens, and are to be seen by indirect ophthalmoscopy using a +4D lens in front of the eye. These are common when vision falls below 6/10, they are very common if it is below 6/12, and from that time on, develop into the form of fine black striæ passing from the periphery towards the centre of the lens. They seldom, however, actually invade its central portion until the stage of immaturity is reached, when opacity

formation proceeds apace in this situation and outstrips the same process in the periphery.

If the general practitioner will remember that the common visual complaint of old people, due to the onset of presbyopia, is failure of *near* vision, distant vision remaining unaffected, and that in the incipient stage of cataract these symptoms are reversed, *distant* vision being lost while there is no complaint about near vision, with presbyopic spectacles of course he will be led to suspect its onset at a much earlier stage than is nowadays the case. He should then either endeavour to confirm the diagnosis by instilling a weak mydriatic and examining the eye with the ophthalmoscope, or send the patient to a specialist to do this. There will thus be many patients brought for treatment at a stage when the process can be arrested without operation, and when a result can be obtained that is obtainable by no form of operative treatment in the later stages.

II. Immature Cataract.

This type has the size and shape of the normal lens. There is present in it a central opacity, generally nuclear in situation. The cortex is, from the operative point of view, normal lens substance which is in no way liquefied nor has lost its normal attachment to the capsule. It still retains much of its original transparency, and this is responsible for the sign of the shadow of the iris being visible on the central nuclear opacity when the eye is illuminated obliquely. This

greater opacity of the central than of the peripheral portion of the lens is responsible for the paradox which has already been explained, that the patient sees better in a dull than a bright light. *It is also responsible for the eagerness of the opium-eater to have his cataract extracted in the immature stage.* The opium pupil is characteristic. It reacts to light with such lightning quickness, and its range of contraction and dilation is so small that the surgeon must be himself quick to observe it. It fails to dilate sufficiently in a dull light to uncover the transparent peripheral portion of the lens, and this accounts for the early stage at which the opium-eater has trouble.

The anterior chamber in this type is normal in depth, the reaction of the pupil normal, and there is a faint bluish sheen about the lens which to the trained eye is perfectly distinct from and in no way confusable with the marked green tinge of the secondary glaucomatous cataract.

The immature lens is suitable for extraction by the intracapsular method, its attachment to the suspensory ligament not being of undue strength at any stage at which optical conditions render it advisable to operate.

The older generation of capsulotomy operators deemed it unfit for operation by Daviel's method, demanding abolition of the iris shadow as a sign that the cortex was opaque, the cataract being then ripe or mature. In this they were perfectly right, for the nature of the cortex, its close adhesion and vital attach-

ment to the capsule renders it impossible by any method to separate it completely from the capsule and remove it from the eye. And when left behind, as left it must be, it is still living. By its proliferation, and by the inflammatory reaction set up by cortical remains, there is produced a dense after-cataract of a nature such that no process of needling can deal with it. The only satisfactory procedure is deliberate extraction of the after-cataract as laid down in a later chapter.

III. Mature and Hypermature Cataract.

The natural process of maturing in senile cataract may be considered as a combination of spread of the nuclear opacity and liquefaction or otherwise of the cortex, and in some cases the subsequent absorption of the latter—the different direction which these processes take being responsible for dividing off the majority into the ordinary Hard cataract and the Morgagnian types.

III-A. The Morgagnian Type.

Here, the nucleus is small throughout, but the cortex rapidly liquefies, absorbs moisture and swells up. This is the type often known as intumescent, from the way in which the great increase in the antero-posterior thickness of the lens pushes the iris forward, rendering shallow the anterior chamber. Its pressure on the iris may be such as to interfere mechanically with the pupillary reaction to light. Occasionally, though very seldom, it may even cause obstruction of the filtration

angle and set up an acute glaucoma. For this reason a patient with this type of cataract should always be kept under observation if for any reason immediate operation is not being done. If this accident occurs, immediate operation will be required, and the line to be adopted is discussed under " Complicated Cataract." (*Vide* page 32.)

Thus a shallow anterior chamber and a pupillary reaction which is sluggish, but normal in range, are typical of the extreme MATURE MORGAGNIAN TYPE. It has a flocculent as distinct from a striated appearance, best compared to the sheen of mother-of-pearl against a dark background. This gives place to a more smooth even texture with the liquefaction of the flocculi. Its colour is white in the flocculent stage, with a markedly bluish tinge after the disappearance of this stage.

When maturity is reached, absorption of the cortex begins and progresses till the lens resumes its normal size. It then consists of a nucleus surrounded by a small amount of fluid matter enclosed in the capsule. The anterior chamber returns to its normal depth, the hindrance to the pupillary reaction is removed. The cataract has still a markedly bluish white tinge.

The process of cortical absorption may continue till there is none left, but this is very rare owing to the length of time required. The examples seen are mainly after a Morgagnian Cataract has been couched, when all that is left of the lens is a minute nucleus enclosed in

a shrunken capsule, which years later floats up again into the pupil. This might be called the HYPERMATURE MORGAGNIAN TYPE.

The Morgagnian type has at any stage a very weak attachment to the suspensory ligament, so weak in many cases that it can almost be dislocated by an angry look. It is thus very suitable for intracapsular extraction by an expression method, though from the completeness of liquefaction of the cortex it gives the least unsatisfactory results of any type in the capsulotomy operation.

The weakness of its anchorage is due to the stretching of the capsule in the stage of swelling, to which also is due the thinning and fragility of the latter which persists in the shrunken hypermature stage.

The size of the lens in the mature stage combined with the fragility of the capsule renders an adequate incision of supreme importance in dealing with it by any intracapsular method, in order to avoid bursting the capsule. These same facts render it the least favourable type for any of the traction methods of intracapsular extraction.

III-B. The Hard Type.

In this type the nucleus reaches a larger size. The cortex is not liquefied nor increased in volume and retains a considerable degree of adhesion to the capsule. The shape and size of the normal lens is retained, the capsule is never stretched and so is not unduly fragile.

This is the stage of maturity. Thus the anterior chamber is of normal depth and the reaction of the pupil unimpeded. It has a radially striated texture and in colour varies from white to light amber, and even black.

The Hypermature Hard Cataract differs only from its predecessor in that the cortex has been largely absorbed.

The Hard Cataract at any stage is very suitable for intracapsular extraction. Its attachment to the suspensory ligament, though not so weak as that of the Morgagnian type, is reasonably so, the degree depending solely on the age of the patient. In extraction by capsulotomy the results are more unsatisfactory than with the Morgagnian type, owing to the viscid nature of the cortex which adheres with more tenacity to the capsule.

III-C. The Type Hypermature *ab initio* or Disciform.

This variety occurs between 30 and 45 years of age, earlier in life than the previously described varieties of senile cataract, and represents a transition type between them and juvenile cataract. Liquefaction and separation of the cortex are in abeyance, so that there is no definite nucleus formation. The lens substance becomes transformed into a viscid homogeneous material, firmly adherent to the capsule, whose consistency one of my friends has aptly compared to that of chewing gum. The capsule is very dense and strong, more so than in any other type of cataract.

This type is of very slow development. It undergoes gradual absorption of its antero-posterior diameter, while the transverse diameter remains unaltered. Its circumference is thus thin and sharp.

It will be seen in this variety that the anterior chamber is much above normal depth, and the iris tremulous if the case has reached a late stage of development. In appearance it has a smooth even texture without either flocculation or striation, and its colour is that of white soap or polished bone.

It is most important that this type should be diagnosed by performers of the capsulotomy operation. In the first instance the capsule is so dense and tough that the operator frequently fails to tear it with the cystotome but succeeds in dislocating the lens. The statement made by most writers on this subject that the attachments of this variety to the suspensory ligament are weak is not a fact. Its attachments are stronger than those of the ordinary hard senile cataract, in which respect it is more closely related to the juvenile type. The relative strength of the capsule to that of the suspensory ligament is immensely greater than in any other type, senile or juvenile.

It is these facts which are responsible for another erroneous statement frequently made by the writers of text-books, that of stating that hypermature cataract is often partially dislocated by nature. In my large experience I have never come across one such. In my opinion the reporters of these cases have overlooked the

fact that they have dislocated the lens in the attempt to tear the capsule with the cystotome.

Further, even if the capsule is successfully torn, without dislocating the lens, the operator is faced with the task of evacuating its viscid adherent contents. There is no method by which this can be done with any degree of satisfaction. Unless the operator is prepared to tear out the capsule with forceps after the escape of most of its contents, he will later have to deal with the most dense and most troublesome of all the varieties of after-cataract. He will not be successful by any process short of deliberate extraction of the after-cataract as described in a later chapter.

In my experience this variety is suitable for intracapsular extraction in skilled hands, but it is not the type of case on which to teach a beginner. If he attempts his first intracapsular extraction on this type, he will certainly decide that intracapsular extraction is impossible.

BLACK CATARACT.

The colour of a cataract depends on two factors. The first and most important is the amount and consistence of the cortex. In the Morgagnian type this is abundant and is responsible for the blue-white hue. In the hard senile type it is scantier, and of a different consistence. It allows more of the colour of the nucleus to show through, accounting for the light amber tint often seen. The pigmentation of the nucleus may be for some reason very great, and if not obscured by cortical material will manifest itself in all stages from light amber to

black. In practice black cataract is found only in fairly advanced age, and it will be seen, must be, from the operative point of view, a hard cataract. Pigmentation of the nucleus is often found in the Morgagnian type but this is recognisable by no method of examination before operation, and is of no diagnostic importance.

Black cataract is interesting in that the inexperienced will find reflected light necessary to recognise that it is a cataract, for its colour is that of a normal pupil. And it is so great an obstruction to the transmission of light that it interferes not only with the patient's recognition of light but prevents the retina receiving the stimulus necessary to produce a sharp pupillary reaction. Hence poor recognition of light and a sluggish pupil are not to be taken as indications of a diseased retina to the degree to which this applies in the non-pigmented varieties, the eye appearing otherwise healthy.

CALCIFICATION.

This occurs only in a very late stage of hypermaturity in the Morgagnian and Hard types of cataract. It is of no prognostic importance in intracapsular extraction, but is a definite contradiction to capsulotomy owing to the nature of the after-cataract which follows.

CONGENITAL CATARACT.

Primary Cataract occurring in children and young persons may be divided into congenital and acquired varieties. The dividing line is by no means sharp, there is frequently in the congenital varieties associated retinal defect, and in the acquired types the hereditary

element is in my experience large. There are also, as may be expected, often associated congenital defects elsewhere in the body, of which the brain is the most important. A small proportion have or develop an epileptic history. Hence operation on cataract in young children should be undertaken with a guarded prognosis.

The clearly congenital types are four in number :—

(1) *Anterior Polar Subcapsular.*—This has to be distinguished from the Anterior Polar Capsular, having its origin in the perforation of a small corneal ulcer, which may subsequently have healed without leaving a trace. The recuperative power of the cornea in childhood is marvellous.

(2) *Posterior Polar.*—This has its origin in the remains of the Hyaloid Artery.

(3) *Circumscribed Congenital Stationary Opacities*, occupying the central portion of the lens substance. There are frequently associated retinal defects.

(4) *Lamellar Cataract*, in which there is a central opacity showing radial striation like the spokes of a wheel, surrounded by a ring of perfectly clear lens.

The first three varieties and the Anterior Polar Capsular variety are all stationary. Lamellar Cataract is generally, but not always, stationary. If progressive, it is the slowest of all cataracts in maturing. The treatment for all stationary varieties is to do an optical iridectomy when necessary. If more than this is necessary, treatment should be on the lines laid down in the chapter on Cataract in Children and Juveniles.

CATARACT IN JUVENILES.

These are the most common cataracts found in youth, and are in my opinion always congenital, though they are not necessarily fully developed at birth, and young adult life may be reached before they become apparent. The important thing about them from the clinical point of view is that there are three main types :—

(1) A membrane consisting of opaque thickened capsule, with little or no contents.

(2) A capsule whose contents are of the consistency of milk.

(3) A capsule whose contents are of the consistency of thin jelly.

The first variety is the hypermature stage of a soft cataract in which the contents have become absorbed. It is very similar to an after-cataract and should be treated as such.

The second has a uniform white or bluish white appearance and is the only variety on which needling has any effect.

The third has a flocculent appearance and is important to recognise, for its contents fail to become absorbed even after repeated needlings.

CATARACT IN YOUNG ADULTS.

The thing of importance about these cataracts is that one must be prepared to meet a hard nucleus after 15 years of age. It is infrequent till 20 years, it is

very frequent after 25, and if present at any age will not be absorbed after needling, and in extraction it will give trouble if the incision is not adequate.

B. SECONDARY CATARACT.

By this is meant cataract which has developed as a consequence of injury, local disease of the eye, or special constitutional disease.

I. Traumatic Cataract.

This is of two types. In the first a blow which was insufficient to injure the cornea, has partially dislocated the lens, which becomes cataractous. The coats of the eye are often ruptured posteriorly. As the capsule of the lens is uninjured there is no necessity for haste in treatment. When the inflammatory reaction has completely subsided and the eye is perfectly quiet, but not before, the cataract should be extracted in the capsule if there is useful vision left in the organ.

In the second type there has been a penetrating wound of the coats of the eye, in which the lens may or may not have been dislocated, but its capsule has been ruptured. The lens matter absorbs moisture, becomes opaque and swells up, making its way into the anterior chamber, and one of the most serious emergencies of ophthalmic surgery may ensue.

If the wound involves the ciliary region, in my experience, sympathetic ophthalmia is almost certain to follow. To adopt an expectant policy in this case is to gamble with all the dice loaded against us, the excep-

tions to the rule being very rare. The eye should therefore be enucleated without hesitation.

If the wound does not involve the ciliary region, the case requires nice judgment, and no stereotyped rules can be laid down. The eye is often so much damaged that it is very unfavourable for immediate operation and extraction of the lens.

Atropine is a very valuable drug in these cases provided the principles underlying its use are understood. Its sole useful function in *any inflammatory condition* of the eye is to prevent adhesion of the margin of the iris to the lens taking place in its central portion by dilating the pupil or to burst such adhesions if they have formed but are *quite* recent. If they are not recent, it will fail to separate them and is then actually harmful. The statement made in the text-books that atropine places the eye at rest, is utter nonsense and is responsible for gross abuse of the drug. It is an irritant and congestive agent which is only of value if it is *successful* in dilating the pupil. Its advantages then outweigh its disadvantages. If it is not successful, the reverse is very much the case. In conditions such as corneal ulcers in which there is no involvement of the iris or ciliary body in the inflammatory process, there is no advantage of any kind to be gained by its use, and every disadvantage. If there is risk of perforation, it raises the tension and greatly increases the risk. It is irritating to the conjunctiva and greatly increases any inflammation thereof.

Cocaine, used for the relief of pain in these conditions, is second only to atropine in its power for evil.

The combination of the two is as deadly a prescription as that of morphia to relieve the pain and stop the diarrhœa of acute bacillary dysentery.

When atropine has to be used in an emergency, there must be no waste of time in getting it to act. The best method is to inject 1/50 gr. in a few minims of distilled water under the conjunctiva. The instillation of drops of a watery solution is useless unless combined with cocaine, for they are irritant and are washed out of the eye as fast as they are put in. If there is no open wound, the subconjunctival injection should be followed up by the introduction of an atropine ointment inside the lids. It will then quickly be apparent whether the drug is going to dilate the pupil or not.

The sheet anchor for the relief of pain and congestion in the eye is the use of leeches, combined with hot fomentations. The natural leech is far more effectual than the artificial one, but one alone is useless. Not less than half a dozen should be employed. They seem not only to relieve the pain but to help the atropine and the other drug—mercury, which we should give by the mouth to take effect. Mercury in my experience is of great value in speeding up the absorption of free lens matter.

Careful watch should be kept during the first few days for the onset of glaucoma. If the intra-ocular tension rises, it should be relieved by slipping a Graefe's knife into the anterior chamber under cover of the conjunctiva, and letting the aqueous out. There should be no hesitation about repeating this daily if necessary

for a few days. The inflammatory conditions will usually subside, and the after-cataract can be dealt with at leisure when the eye is once again quiet, if the visual function of the retina has not been destroyed by dislocation.

In some cases the swelling of the lens matter may be so great that we are compelled to make a sclerocorneal incision, do an iridectomy, and squeeze it out with the nucleus (if one is present).

If we have to interfere in either of these ways, we should first touch the wound and any corneal ulcers present with a strong solution of silver nitrate (gr. 60 to the ounce), and then flush out the conjunctival sac with some antiseptic solution.

These are cases which require much judgment and experience in dealing with them.

II. Anterior Polar Capsular Cataract.

This cataract has been already mentioned under the heading of Children. It is secondary to the perforation of a corneal ulcer in early childhood, the lens coming in contact with the margin of the perforation with the collapse of the cornea and adhering to it. In most cases with the closure of the perforation and reformation of the anterior chamber the adhesion separates. Very often the ulcer heals and leaves no trace behind, for the recuperative power of the cornea in childhood is marvellous. All stages are met with between this and a heaped up opacity with a fine filament of adhesion between it and a corneal opacity, though actual persistence of the adhesion is extremely rare.

This variety is stationary and an optical iridectomy is all that is ever necessary.

III. Glaucomatous Cataract.

By this is meant the cataract which is a sequel of untreated glaucoma or of glaucoma which has failed to respond to treatment. It is but an incident in the degenerative process which affects all the structures of the eye, and by the time it has developed, the visual function of the retina has been completely destroyed.

It is important that the surgeon should recognise and differentiate this type from the other conditions, enumerated hereafter, in which cataract and glaucoma are associated. For in them there is some hope of useful vision being gained after extraction of the cataract at the appropriate time. But in glaucomatous cataract, not only is there no object to be gained by doing so, but the diseased state of the choroidal vessels renders an expulsive hæmorrhage from them inevitable if it is done; if not on the table, then shortly afterwards.

The naked eye appearances are characterestic. The patient has a peculiar vacant stare and an aimless twitching of the eyeballs which are indicative of a blind eye. The pupil is dilated and unresponsive to light, and the iris has lost its lustre. The cataract has a typical sea-green tinge, which with the greenish blue appearance of the sclero-cornea have given the disease its name. The vessels of the sclerotic stand out congested and tortuous, often encircling the cornea, which may still be painful if the stage of raised tension has not

been passed. During this stage the patient invariably complains of a wearing pain in the temple, and to a less extent in the orbit, which passes off when the eye becomes soft.

The conditions from which this has to be differentiated come under the heading of cataract complicated by glaucoma, of which there are three types, enunciated later. (*Vide* page 32.)

IV. Cataract following Iridocyclitis.

In these cases there is often useful visual function left in the retina. For its estimation we have to rely alone on the perception and projection of light, for the iris is generally so bound down by adhesions to the cataract that the reaction of the pupil is absent.

Extraction of the cataract in its capsule may be undertaken with confidence if the iridocyclitis is quiescent, the most valuable guide to this being the recovery of the normal lustre of the iris, and if the naked eye appearance is otherwise healthy. But needling or extraction by capsulotomy will be certain to provoke a recrudescence of the iridocyclitis, and will achieve no success. This is discussed more fully later.

V. Cataract Consequent upon Undue Exposure to Ultra-Violet Light or to Heat.

This is usually a soft or a Morgagnian cataract depending on the age of the patient. It should be dealt with as such.

VI. Cataract in the Diabetes of Youth.

This is, in my opinion, the only type of cataract truly secondary to general constitutional disease. It is a matter of common knowledge that diabetes in youth is much more malignant than the disease in later life and shows a much better response to treatment with insulin and a dietary regime. In fact it is a different disease.

It is of the same soft consistency as the other cataracts met with in adolescence, and like them sometimes contains a small nucleus. It should be treated on the same lines as laid down elsewhere for other cataracts occurring in patients of the same age, differing only from them, in that there is more liability to post-operative complications such as iritis. It is necessary to get the blood sugar reduced to the minimum before operation and to keep it so during convalescence. The great complication to be feared is a violent and intractable iritis if the blood sugar remains high.

C. COMPLICATED CATARACT.

By this is meant cataract of one of the ordinary varieties complicated by local or general disease, of the eye or elsewhere.

I. Nasal or Oral Sepsis.

Contrary to one's expectations, these have not the sinister significance imagined when intracapsular extraction is practised. In the Punjab the conditions of the old people who come with cataract for operation beggars description. Yet the infrequence of complications in

cases treated by the intracapsular method astonishes surgeons who have been trained in the school of capsulotomy in Europe or America. Assertion of this infrequence is often received with incredulity by men in these countries who have not had the opportunity of seeing for themselves. But the proof of it lies in facts behind which there is no getting. Over 20,000 cataracts are extracted in the Punjab yearly, and the vast majority in the capsule. When one realises that this work is done in the main by less than half a score of men, with but a skeleton staff of assistants, it is obvious that complications must be very infrequent.

At the time when I was doing over 50 cataracts daily in the season at Jullundur, I had a staff of one assistant surgeon, one sub-assistant surgeon, and half a dozen dressers. The assistant surgeon when asked one day by the Inspector General how he got round the cases, replied that, if they had been cases treated by the capsulotomy operation as was the fashion in the Mayo Hospital in Lahore when he was there as House Surgeon, he would have required 72 hours in the day to do the work. As it was, the dressings needed no disturbance for there was no after treatment to do. It is certainly good practice to treat nasal or oral sepsis prior to operation if the conditions permit. But if undertaken at all, it must be done long enough before the cataract operation for the gums to heal *completely*. It is far better not to touch a mouthful of septic teeth than to clear them out and operate while the sockets are still discharging.

II. Inflammatory Lesions of the Ocular Appendages.

(*a*) *Dacryocystitis*, stye or other local suppurative lesions lead to almost certain disaster if present at the time of operation. They must be dealt with radically and the wound given time to heal soundly before operation is undertaken.

(*b*) *Chronic Conjunctivitis.*—Here trachoma must receive most consideration, for it is present in a very large proportion of our Indian patients. If it is in the chronic quiet stage, it does not appear to predispose to infection and we operate on these patients without hesitation. When it is of the acute form, or has a flare-up, the matter is otherwise. It is probable that in these types the flare-up is due as much to secondary invasion by pyogenic micro-organisms of a conjunctiva whose *resistance is lowered, as to the actual trachomatous* process.

If the conjunctiva appears unhealthy (with the proviso that this need not apply to chronic quiet trachoma) the surgeon should treat it till he is satisfied that it is healthy. If he has any doubts about it, bandaging the eyes for a few days is an excellent method of increasing any inflammation present so that he has then no doubts.

III. Corneal Opacity.

The lens should be extracted by such method as is suited to the age of the patient, if there is any transparent cornea, the *iridectomy being done behind it.* It is remarkable how well patients will see through a *very* small piece of clear cornea after cataract extraction.

It should be done even if the iris is adherent to the cornea, all the way round, when we have only the recognition of light to guide us as to the visual function of the retina. We should in this case be especially careful to see that glaucoma is absent, or if present, to deal with it *before attempting to extract the cataract.*

IV. Posterior Synechiæ.

These are usually the sequel of an old iritis, and the treatment of cataract so complicated is closely allied to that cataract secondary to iridocyclitis. Needling or extraction by capsulotomy is certain to be followed by a violent reaction or recrudescence of the iritis. If the visual function is good, the cataract should be extracted in the capsule on lines laid down later.

V. Glaucoma.

Cataract complicated by glaucoma falls into one of three types, which must be distinguished from each other and especially from glaucomatous secondary cataract.

(*a*) *Acute glaucoma as a consequence of mechanical obstruction of the filtration angle by the swelling of a Morgagnian cataract which pushes the root of the iris forward.*

In this case one is compelled to do an iridectomy to relieve the immediate emergency, and owing to the shallowness of the anterior chamber, a wound sufficient to do this is the largest that can be possibly made. For the iris is pushed forward and lies in actual contact with the cornea.

Were it possible to avoid tearing the capsule of the lens in doing this iridectomy, I would advocate leaving matters at that, and extracting the cataract in the capsule a few weeks later when it had diminished in size. But in practice the capsule is always torn for it is very thin, and the wound should be enlarged slightly with scissors to let out the nucleus. The resulting after-cataract will have to be dealt with later, but owing to the fluid nature of the cortex in this type of cataract, it will be relatively thin. There is every prospect of a successful result, for there is no risk of choroidal hæmorrhage, and but little of iritis.

The other two types are :—

(*b*) *Acute or chronic glaucoma setting in during the development of an ordinary senile cataract.*

(*c*) *An ordinary senile cataract developing after an iridectomy or trephining has been successful in arresting glaucoma on a previous occasion.*

A fourth type can be included, though it borders on splitting hairs, when both the cataract and the glaucoma are secondary to an old iridocyclitis. The treatment of these three types is discussed later. They are not hopeless cases if useful vision is left in the retina, though they are bad operative risks owing to the liability of an expulsive choroidal hæmorrhage following. This increases *pari passu* with the extent of the damage that has been done by the glaucoma before its arrest.

VI. Diseases of Retina and Choroid.

(*a*) *Night-Blindness.*—This disease is common in India. In the Punjab the pigmentary deposits which are described as typical of the disease are generally absent. The ophthalmoscopic appearance is that of simple progressive retinal atrophy, commencing at the periphery and spreading slowly but steadily with the passage of years towards the macula. The point of interest is that *pari passu* with the diminution of the field of vision the reaction of the pupil becomes more and more sluggish, even though macular vision may be perfectly good.

Hence, in a case with a typical history of the disease, the presence of a sluggish pupillary reaction must not be taken to indicate that there is no prospect of useful vision. If the reaction is half as sharp as that in a normal eye under the same conditions, one is safe in assuming that the visual field is reduced by half, and so on in proportion.

If cataract occurs in the late stages of the disease, it is in my opinion an ordinary senile cataract. For the large proportion of cases of night-blindness never develop cataract. Hence I include it under the head of "complicated" and not of secondary cataract as is done in most text-books.

Since the disease is slowly progressive, many years of useful macular vision may be obtained by extraction of a cataract if one develops, even in the later stage, and a fact which should be more widely known is that there

is no danger in doing so. Such eyes do as well as and suffer no more post-operative complications than normal eyes, though this is not yet recognised by the profession.

The following example will suffice to shew what can be done for these cases, at present regarded by the profession as hopeless.

A Canadian lady, of about 60 years of age, came to me with night-blindness and double cataract. She had been turned down by a number of men in Canada, the U.S.A., and Europe, as hopeless.

I gave her a note to her ophthalmologist, saying that in my opinion she had many years of useful vision if one or both of these cataracts were extracted, and that the operative risk was not greater than in normal eyes. He wired to her not on any account to have it done, but she took the law into her own hands and I extracted one of her cataracts. The result was perfect from the operative point of view and she left me at the end of three weeks with vision of 6/6. This was no surprise to me, being what I expected. Her night-blindness, of course, continues its normal course.

(b) *Other Retinal or Choroidal Diseases.*—Retinal Scotomata or Disseminated Choroiditis may be present behind a cataract which cannot be diagnosed or even suspected. So long as the peripheral portion of the retina is sound, the reaction of the pupil to light is perfect and the eye in every respect looks healthy. We occasionally get choroidal detachment after cataract extraction in eyes which we classed, from their appearance, as first-

class operative risks. In my opinion these are cases of extensive choroidal disease, and such hæmorrhage is no more frequent after intracapsular extraction than after the capsulotomy operation.

(*c*) *High Myopia.*—In these cases detachment of the retina is to be feared in the normal course of events, and may be provoked by any operation. Hence the fewer times we have to interfere the better and if a cataract has to be extracted it should be done by the intracapsular method. The patient should be warned that his eye is, in insurance phraseology, a "third-class risk," but that if his luck is in, he will probably be able to do without glasses and to see better than he ever did before.

(*d*) *Couched or Dislocated Lens.*—In my experience dislocation of a cataractous lens by nature is extremely rare, the cases being mainly reported in error, owing to the failure of the surgeon to recognise that he has dislocated a senile cataract in his attempt to tear its capsule with the cystotome. Congenital defect of the suspensory ligament or congenital partial dislocation of the lens is another matter, but these lenses do not necessarily become cataractous.

The common types are dislocated by injury, or in India, by the lens couchers.

Dislocation by injury into the anterior chamber is rare, but if it occurs, is responsible for much mischief. The lens should be removed at once.

After dislocation behind the iris, whether by injury or by the coucher, the lens frequently floats in again

behind the pupil. These cases are easily recognised whether the lens is visible on not, owing to the iris being tremulous.

An inevitable sequel of dislocation of the lens backwards is the onset of progressive retinal atrophy, *retinitis pigmentosa sine pigmento*, as explained in the chapter on lens couching. If they are not blocking the pupil, couched lenses should be left alone, as difficulty will be experienced in extracting them. If they are blocking the pupil, they should be extracted, the technique to be adopted being laid down in the section on "Operative Technique."

VII. Bright's Disease, Gout, Diabetes of Later Life.

In my opinion, cataract occurring in these diseases is not secondary to them. It is of the ordinary senile type and is no more common in the Punjab in patients suffering from them than in patients free from them. Post-operative complications are, however, much more frequent than in healthy patients, and the eye does not heal as well or as quickly. Hence when we are compelled to operate, thorough preliminary preparation is necessary. This should take the form of getting him well under the influence of mercury and atropine. Mercury has in my experience a powerful influence on iritis of all kinds, and in any case in which I have found it necessary to use it or atropine after such complications have occurred, I have always regretted that I did not have the patient under their influence before operation.

For in such circumstances every hour wasted is of importance.

The atropine must be used thoroughly so that there will be no necessity to interfere with the dressings after operation, in the manner discussed later.

Finally, the bowels must be well cleared out, a few days before operation, and the patient put on a proper diet, while at the operation itself, the intracapsular method of extraction should be adopted. For it is incomparably less liable to provoke complications than is the capsulotomy method, owing to the irritant nature of lens matter if remaining in the eye.

As regards after-treatment, these patients should not be lost sight of for at least three weeks after the operation.

THE TREATMENT TO WHICH THE VARIOUS TYPES AND STAGES ARE ADAPTED.

INCIPIENT CATARACT, ITS ABORTIVE TREATMENT.

The diagnostic features of this stage have been fully discussed, but it is well to recapitulate them. The symptom is *failing distant vision*, which is noticed before the failure of near vision has been sufficient to cause inconvenience. In contrast with this is the situation in presbyopia, *where it is loss of near vision that gives rise* to complaint, distant vision remaining unaffected. The local signs are limited at first to a uniform loss of transparency of the lens, followed later by circumscribed

opacities spreading from the periphery towards the centre. With the formation of a definite localised central opacity this stage passes into the next, the stage of immaturity.

An account of the manner in which I was led to undertake active treatment of cataract in this stage should be of interest.

I was consulted by a lady who came to me from a long distance on account of a thin corneal nebula in both eyes, in front of the pupils. When I examined her with the ophthalmoscope, I found in addition clear signs of the incipient stage of cataract with which I was already familiar.

I had for a long time been obtaining great success in the treatment of these corneal nebulæ by subconjunctival injections of cyanide of mercury solution, a line of attack which was originally brought to my notice by the writings of Darien of Paris. I told the lady that she had this early stage of cataract in addition to the corneal nebula, and that while I could cure the latter, I could not influence the former. In India the people reckon the amount of vision they possess in terms of annas in the Rupee. This lady estimating hers at the moment as four annas, I told her that I could promise her eight annas, that is to say, 6/12, but not more. To my great surprise she wrote to me some months later that she could now see as well as ever she did. I published her case along with others a short time afterwards.

Considering this matter over, I came to the conclusion that the hyperæmia, set up by the subconjunctival

injection of an irritant substance and maintained by the application of yellow oxide of mercury ointment, which is the rationale of the treatment, must have improved the conditions of nutrition of the lens as well as that of the cornea. Otherwise the result was inexplicable.

On the strength of this observation, I started to treat all incipient cataracts in this way as a routine, and to watch the result. The conclusions to which I came are as follows: if the distant vision has not fallen below 6/12, there is a good prospect of its restoration to normal. With vision between 6/12 and 6/14, there is often considerable improvement but the response is very erratic and not so enduring. I have even had a good result with vision below 6/15.

The technique I adopt is to inject under the conjunctiva (under cocaine anæsthesia) 25 m. of a $\frac{1}{5,000}$ solution of cyanide of mercury, containing 1 per cent. of acoin, in cases under 60 years of age. Over that age a weaker solution is necessary, such as $\frac{1}{6,000}$, as the severity of the reaction increases with the age of the patient. This strength applies to the cyanide of mercury only. I have more than once been supplied with the oxycyanide in error by firms of considerable repute, and been at a loss to account for the extreme severity of the reaction produced. The oxycyanide is an infinitely more potent irritant than the cyanide and not as satisfactory.

The acoin controls the pain resulting from the injection better and for a longer time than any other local anæsthetic I have met. It allows the hypodermic of ⅓

grain of morphia, which is given simultaneously, time to *come into full action before the effect of the acoin* passes off. If these precautions are adopted, the patient will *not complain of pain; if these are not, he will do so* bitterly for some three hours after the injection. The surgeon must not be surprised if there is a little vomiting at the outset, which is due to the morphia.

The hyperæmia set up by the injection is maintained, when it begins to subside after about 14 days, by the use of yellow oxide of mercury ointment, inserted into the conjunctival sac and rubbed in by massage through the lids once daily. The patient's friend or relative should be taught how to do it. The strength of the ointment necessary will have to be found by experiment *in the particular case, and varies from gr. I to gr. IV to* the ounce.

The response to this treatment is in general along the lines laid down previously, but the patient should be warned that no dogmatic prognosis can be given for his particular case. A small proportion, to all appearances identical with those that respond, will completely fail to benefit by the treatment which itself is evidence that there is more than one cause of senile cataract. Improvement will usually be very apparent within three weeks, and will be progressive for a further month. If it is slow in manifesting itself, hope should not be abandoned until active treatment has been continued for at least a month.

If this is explained to the patient, and he is assured that there is *no* possibility of harm ensuing, there will

usually be little difficulty in persuading him to give the treatment a trial.

I have written papers on this subject often, and I am well aware that it is regarded sceptically. I would refer those who doubt me to the following letter from a patient, one of many such in my possession.

Surgeon Commander,....., Ex-R.N., aged 64, writes :—

"I just want to tell you that your treatment of my right eye appears to have been *absolutely* successful. I should have written before but I wanted to allow sufficient time to elapse to enable me to speak authoritatively; and now after more than two years I think I am enabled to speak with a sense of conviction.

"Well, when the acute inflammatory condition completely subsided, I noticed that the haziness of vision was rapidly clearing up and in a few months the sight (with the usual distance glasses) became normal and has remained so ever since....."

His vision when he came to me with his correcting glasses had gone down to 6/13. This gentleman's capacity to estimate range of vision cannot be challenged as such was a very important part of his work in the Navy.

This result is in harmony with my extensive experience among Railway Officials whom I had ample opportunity of following up as they had to return to me for re-examination periodically so as to comply with the requirements of the Railways.

Since my first paper on this subject many inunctions and instillations have come into the field, all claiming to be efficient for this purpose. I do not for one moment question their efficiency. Their success in my opinion depends solely on their action as mild irritants, inducing a hyperæmia of the ocular vessels. It seems to me that the method of inducing this hyperæmia is immaterial, so long as it is maintained for a sufficient length of time. *From the patient's point of view that agent is best which, while being efficient, causes him least inconvenience.* I have tried iodide of potash and many other drugs, and in my experience cyanide of mercury is the most reliable, producing a uniformly standard reaction with no evil effects. The principal cause of senile cataract must be failure of the nutrient mechanism of the lens (whatever that may be) to produce a physiological pabulum, and the induction of hyperæmia restores the physiological function of that mechanism. We know the influence of Biers' hyperæmia applied to the other parts of the body, as of leeching and dry cupping in acute inflammation of the viscera. *Their exact mode of action we do not know, but this is a similar case.*

IMMATURE CATARACT.

In 1908 in a paper read at the annual meeting of the American Ophthalmological Society at New London, I first brought it to the notice of the ophthalmic profession that immature cataract could be extracted in the capsule with the same facility as could mature cataract in a patient of the same age. I laid down that the difficulty of dislocating a lens varies inversely as the age

of the patient, and that the cataractous process has, with few exceptions, but little influence on the matter, for in fact the healthy lens is just as easy or as difficult to dislocate as the cataractous lens at the same age.

Prior to the publication of this paper, immature cataract was held by the profession to be inoperable. No one dreamed of questioning the opinion of the "Masters of Europe" on this point, which in my opinion was, and still is sound so far as extraction by the capsulotomy method is concerned.

If immature cataract is dealt with by capsulotomy, the cortex is still a living tissue, still sticky and firmly attached to the capsule. It cannot be mechanically separated from the latter with any degree of perfection, though the methods are legion which have been introduced in the endeavour to do this. These cortical remains irritate the eye and are a provocative cause of post-operative iritis. They stimulate the sub-capsular endothelium to proliferate and in consequence greatly increase the density of the after-cataract.

In dealing with this dense after-cataract the surgeon is faced with the choice between Scylla and Charybdis. He cannot steer the middle course of neglecting it, as was frequently done by the old school of capsulotomy operators with the comparatively thin after-cataract which follows operation in the mature stage. It is so grave an obstruction to vision that he is compelled to make a hole in it at some time in some way.

If he gives the eye sufficient time to settle down completely and to lose the intolerance to further inter-

ference which is present during the first few weeks, the after-cataract will have become sclerosed and tough. No mere needling will then be sufficient to deal with it; *nothing short of deliberate extraction will suffice.* Yet if he needles it early while it is still tender and amenable to the process, he will be sailing perilously close to the wind.

Interference with an after-cataract at any time after the original operation, however long, is always fraught with *risks of setting up an iritis, an iridocyclitis, or* an acute glaucoma. The older generation of capsulotomy operators tacitly recognised these risks. For in the main they were loath, even after the lapse of months, *to needle the relatively thin after-cataract which follows* operation in the mature stage. Vision had to be seriously reduced by it before they would embark on further operative adventures inside the eye.

The disasters which followed needling on this restricted scale were not a few and were more than were published. But with the present vogue of tackling immature cataract by the capsulotomy operation they must be much more common. The range of the operation must be extended to that stage if it is to survive the competition of its rival. It can only be done, and at that imperfectly, by taking the additional risks which are involved in needling the after-cataract while it is still young, risks which are far more serious than the *modern school of capsulotomy operators would have us* believe. I have as much experience of the capsulotomy operation as any man. I know too well how intolerant

the eye is of further interference for weeks and months after it, and how frequently such interference provokes an explosion which destroys the organ.

It is the fashion in certain quarters to brush these risks aside in a very summary manner. The hesitation of the older generation to tackle immature cataract by capsulotomy, is declared to be purely and simply a relic of pre-Listerian days, an obsolete tradition whose persistence for so long is hardly explicable. I do not think that anybody has had the temerity to expound this view in print, where he would have to face the fire of controversy. But I know for a fact that it is the answer given to undergraduate students who inquire about this point in the ophthalmic department of one of the largest general hospitals in London. I have no doubt that it passes for wisdom in the special hospitals also.

Now, if we examine it closely, two things are at once apparent. The first is that it is a gross libel upon men whose hairs are but yet grey. Will anyone seriously maintain that before 1908 ophthalmatic surgeons were lacking in antiseptic and aseptic technique? I have seen at work the foremost men of the world of that decade and they were certainly as careful as any surgeon of the present day. Are we expected to believe that it took ophthalmic surgeons forty years to learn the length to which Listerism would allow them to proceed? The ophthalmic section of the profession is certainly conservative. But I doubt whether those members of it who are most proud of their conservatism would welcome a tribute to it of this kind.

The next thing apparent is that by making this statement the opponents of intracapsular extraction are really conceding the whole case against them. For the germ of truth which it contains is that when surroundings are bad, the mature cataract will escape after the capsulotomy operation with fewer complications than the immature, on account of the more perfect expulsion of the lens matter which is possible with the former. How much better then should we be able to escape complications if the cataract is extracted in its capsule, cortical lens matter and all, and no dead foreign body is left to irritate the eye? And what surgeon will be so bold as to claim that he can make his surroundings perfect in every respect and that he can neglect this source of danger within the eye itself?

If the reader accepts the force of my arguments, he will hesitate considerably before he tackles immature cataract by capsulotomy. To do so is but to jump from the frying pan into the fire; for if the after-cataract is needled early, he will be taking unjustifiable risks ; if it is left till late, it will be as serious an optical obstruction as the original cataract, and one which is not easy to remove.

Can then the cataract be ripened artificially in a short time to render it amenable to the capsulotomy operation? I know of no safe means of doing so. Preliminary iridectomy, with or without simultaneous massage of the lens through the cornea, is safe if the surgeon knows what he is about, but is useless either way. So also is direct massage of the lens with a blunt instru-

ract, and can be employed without hesitation whenever optical considerations demand it.

MATURE AND HYPERMATARE CATARACT.

The strictures I have passed in the preceding chapters on the treatment of immature cataract by the capsulotomy operation also apply, though not with equal *force, to its use in the mature stage. An after-cataract* is still an inevitable consequence and still a source of danger. Though in some cases it is possible to obtain a fair result, yet in too many the patient finally gets sick of repeated unsuccessful attempts to deal with an after-cataract and resigns himself to spending his declining years in a state of partial blindness.

And when we look closely into the type of cataract *which gives the best result by capsulotomy, we find that* it is the Morgagnian or intumescent. Now this is the very type which is the exception to the general rule, that the difficulty of dislocating the lens is solely dependent on the age of the patient, varying in inverse proportion to it, and that the cataractous process has, with few exceptions, but little influence in the matter. A Morgagnian cataract is easier to dislocate than a hard cataract in a patient of the same age, the attachment of the suspensory ligament to the capsule being weaker. Hence where the capsulotomy operation is most successful, it is least needed, for as a type the Morgagnian is the easiest of all cataracts to dislocate. We must remember, however, that age still plays a part. A Morgagnian cataract at 35 years of age is more difficult to dislocate than a hard cataract in an old patient.

So it is clear that in mature senile cataract the capsulotomy operation has *raison d'etre,* and should be abandoned in favour of intracapsular extraction.

CATARACT SECONDARY TO IRIDOCYLITIS OR COMPLICATED BY GLAUCOMA OR BY THE CYNECHIÆ OF OLD IRITIS.

In this section the Morgagnian cataract which has in the swollen stage provoked mechanically an acute glaucoma is expressly excluded from consideration. Its significance and the line of treatment, *viz.*, immediate extraction by capsulotomy, with every prospect of a successful result, have been fully discussed.

In the other types, which have been previously enumerated, there are several points of importance. If the perception of light and the appearance of the eye indicate the prospect of useful vision, they are not hopeless cases for operative interference.

But such interference must only be undertaken when it is certain that the disease has become quiescent, recovery of the normal lustre of the iris being a valuable guide.

If glaucoma is present, an iridectomy or a Lagrange's operation must be done in an endeavour to arrest it. The cataract must not be touched unless the tension has been permanently lowered to normal. In iritis or iridocyclitis it is wise to do a preliminary iridectomy, and leave the extraction of the cataract to a second sitting when the wound has healed and the eye settled down again;

for the iris is liable to bleed profusely and we wish to avoid inflicting any unnecessary trauma on it at the time of extraction of the lens. It is in these types of complicated cataracts, and in them only, that a preliminary iridectomy is indicated and is the right procedure.

The actual extraction of the lens must be in the capsule. For relapse of an iritis is always liable to be provoked in these eyes, or the onset of other complications and the presence of irritant remains of cortical lens matter will frequently turn the balance in this respect. Extraction by capsulotomy will lead to disaster. Needling is little short of criminal. For it will be certain to provoke the recrudescence of an iritis or iridocyclitis, while the lens matter will never be adequately absorbed. It will thus leave an after-cataract as dense as its parent, and bound firmly down to the iris. A second needling will be no more successful than the first, but will inevitably open up the vitreous, which at any subsequent attempt at extraction will come forward when the incision is made, and in conjunction with the firmness of the adhesions to the iris, will render it impossible.

If adhesions of the iris to the lens are present, they should be separated before it is expressed. It is quite easy to do this, for they are generally much weaker than is imagined. The iris is adherent at the pupillary margin only, and there is always a posterior chamber behind it. The iris repositor should be slipped into this chamber between the lens and the iris, a piece more being taken out if necessary in order to open it up. The surgeon should then work steadily round until he has

freed the iris completely, and it will retract as he does so if it has been properly atropinised. It will bleed profusely and part with quite a large quantity of its pigment, but this is no matter. The surgeon should steadily massage the blood clots out of the eye until the bleeding has stopped, and then proceed to express the lens.

Finally, the surgeon should have taken time by the forelock, and have got the patient well under the influence of mercury and of atropine, so that he is in readiness to deal with any complications that may ensue before they arise.

All these types are of course bad operative risks, for the visual function of the retina has been more or less impaired, and there is more liability to post-operative complications than in healthy eyes. In glaucoma there may be an expulsive choroidal hæmorrhage, which is the more likely the greater the damage done by the disease before its arrest, and consequently the less the ultimate prospect of useful vision, if the complication is escaped. It is in my experience no less frequent with the capsulotomy operation than after intracapsular extraction, and is solely dependent upon the extent of the damage to the choroidal vessels.

The patient should always be warned that in insurance phraseology his eye is "a third-class risk." But if he is, for practical purposes, already blind, it is worth his while to take the risk when there is a prospect of his regaining useful vision if matters go well. He will be no worse off if matters do not go well.

CATARACT IN CHILDREN, JUVENILES AND YOUNG ADULTS UNDER 30 YEARS OF AGE.

I have already mentioned the close association of retinal and mental defect with cataract in young children and the necessity for a guarded prognosis. The earliest age at which I regard it safe to operate on congenital cataract is six months to a year. In the non-congenital cataract of children, the earlier it is done the better. They take readily to the necessary spectacles for the evident reason that they see so much better with them.

In considering the treatment to be adopted I will recapitulate the three clinical types met with in children.

(1) A membrane consisting of opaque capsule with either no or at most nominal contents.

(2) A capsule with contents of the consistency of milk.

(3) A capsule with contents of the consistency of jelly. (*The most frequent variety.*)

In the first variety the cataract is hypermature—the lens matter has been absorbed and the capsule is both dense and tough; needling such a cataract gives poor results. It is for practical purposes an after-cataract and should be extracted through an iridectomy-sized incision.

The second variety is the only one which can be needled successfully—it should be done with the iris fully under atropine using a Graefe's knife with a narrow

blade so that the anterior capsule can be extensively lacerated.

In the third variety needling will again lead to disappointment; the opaque jelly-like contents of the capsule do not become absorbed even after this has been done repeatedly.

Early in my career I came across an English girl of about sixteen years of age, whose cataracts were of this variety, and had been needled six times when she was about four years of age by one of the leading ophthalmologists in Europe, yet her condition was no better than if nothing had been done. I mention this case in order to emphasise the importance of diagnosis—the type containing milky juice is of a uniform white or bluish white appearance—that containing jelly-like material presents a flocculent apearance and of a soapy white colour and must be treated by extraction.

As to cataract in young adults there is a common impression that no nucleus is met with under 30 years of age, but this is not correct. I have met a nucleus in a subject under 15 years of age, and one will be on the safe side assuming that a nucleus will be present as a rule after eighteen years of age, generally a small one, and relatively soft, it is true, but if present, will be responsible for a bad result after needling.

EXTRACTION.

My practice up to the present has been to extract these cases by Daviel's operation through a small sized incision, having the iris well under the influence of

atropine, and to deal with the after-cataract at the same sitting. The zonule is firmly attached and the lens matter can be expressed by quite vigorous massage of the cornea.

After this has been done, I remove the speculum and hand over the lids to the care of a competent assistant, insert a pair of closed iris forceps well beyond the centre of the pupil, open the points wide, drive them back through the posterior capsule and remove what is in their grasp. I have never regretted doing this yet. I extracted two cataracts in a girl of the age of eight at the same sitting, leaving the posterior capsule untouched on one side as it seemed quite transparent. Three years later I saw her again. The eye in which the posterior capsule had been extracted shewed a perfect result, a clear pupil and vision of 6/6. On the other side there was a dense after-cataract. I have frequently observed that in children the presence for some years of such a dense after-cataract is very likely to impair permanently the development of the retina. I have not, up to the present, attempted to deal with these cases as a routine by the intracapsular method. The anchorage of the lens under 25 to 30 years of age is so firm that considerable force is needed to dislocate it. If pressure from without with a squint hook is used for this purpose, it is impossible to avoid escape of vitreous when dislocation occurs. Recent developments with capsule forceps may yet enable this to be done, a matter which is more fully considered in the chapter dealing with Barraquer's pneumatic forceps.

CHAPTER II

Operative Technique.

CHAPTER II

OPERATIVE TECHNIQUE.

Preparation of the Patient.

In uncomplicated cases the less this is done the better. Prolonged hospitalisation takes all the nerve out of the patient, and makes him more likely to misbehave on the table. In the Punjab, where constipation is uncommon among the villagers, our patients are operated upon within a few hours of their arrival at hospital, and do much better this way.

General treatment should be limited to a mild purge if the patient is constipated, Blue Pill, gr. v, followed by a Seidlitz power, and if he is nervous, the *effective* use of a sedative is indicated.

I have experimented with all kinds of sedative in all manner of doses. The one to which I have finally gravitated is bromide of potass. The pharmacopæial doses of this drug are absolutely useless for the purpose for which we desire it. I have gradually increased them until I now use 100 to 120 grains in the male, 80 to 100 in the female. This seems a heroic dose, but it is quite safe. Less is ineffective, 50 to 60 grains only making the patient more irritable. The dose must be given sufficient time to act, at least eight or twelve hours. The use of this big dose has the further merit that the patient

sleeps well not only the first but also the second and third nights after it is given.

The point I wish to impress on the reader is that if sedatives are to be used at all, the dose must be sufficient to make sure of producing the desired effect. Any alienist would agree with me in this.

Other sedatives, and particularly morphia, I have found dangerous, the latter owing to the great risk of vomiting following its use.

Local treatment of a healthy conjunctival sac is to be avoided. If it or its appendages appear unhealthy, operation must be postponed until treatment has restored them to health. But the practice of applying antiseptic drugs and ointments to a normal conjunctiva as a preparatory measure is to be condemned, as is that of regarding the normal lachrymal sac as a source of danger and injecting it with silver nitrate. Such treatment only irritates and inflames the mucous membranes, and the discharge of mucus which ensues, forms a favourable breeding ground for micro-organisms. The application of a bandage to the eye the night before operation is equally bad. If the conjunctiva is in the least unhealthy, a bandage serves merely to retain its discharges and make it more unhealthy.

The only previous local treatment which should be undertaken is that required when we wish to have the pupil dilated by atropine at the time of operation. If this is to be done at all, it should be done so thoroughly that the iris will stay fully retracted until the wound is

soundly healed, and that in consequence we will be able to avoid the necessity of subsequent daily instillations during the after-treatment. Atropine ointment B. P. should be applied inside the lower lid several times during the day preceding operation, starting at least 36 hours beforehand. If we have any qualms about its action we can insert some more ointment before closing the lids after the operation and on the first few days subsequently, drawing down the lower lid to do so without inspecting the cornea but even this subsequent interference is to be avoided if possible. Watery solutions make their way into the throat and may cause objectionable symptoms.

The Anæsthetic.

General Anæsthesia is to be avoided as far as possible, as the vomiting which follows it when pushed to the surgical degree is liable to cause detachment of the choroid. I have often cheated troublesome patients by giving them a few whiffs of chloroform, enough to make them happy, nothing more; and then proceeded with the operation under the local anæsthetic which had been previously instilled.

Local Anæsthesia.—The only satisfactory drug in my experience is cocaine, which should be used in a 4 p.c. solution and given *full* time to act. Slight dilation of the pupil is the sign that it has done so.

The use of novacain has been advocated in various forms. The common method is to inject a solution containing a little adrenaline under the skin of the eyelids. This has certainly the advantage of preventing the

patient feeling our fingers or instruments upon the skin. If done at all, the area infiltrated should be wide, including the brow and out over the face to the origin of the zygomatic process of the malar bone. It will then enable us to do an external canthotomy if circumstances require it in a troublesome patient.

The question of its use for producing paralysis of the orbicularis is considered in a later section in which the subject of the prevention of iris prolapse is dealt with. I wish however, to emphasise here that it is not a substitute for an efficient assistant.

The Operating Table.

This should be narrow, not more than 2 ft. wide. It should not be on castors, to prevent the danger of it being shifted inadvertently by assistants. I prefer to sit on an ordinary dissecting room stool, high enough to give a clear view of the field of operation. When sitting one's back does not grow tired so quickly and one's hands are much steadier.

The practice of operating on a patient sitting in a chair or propped up on a couch is bad, as he is liable to faint or vomit and provoke choroidal hæmorrhage, and the operator does not get as fairly at his work as in the horizontal position.

The Sterilization of Instruments.

In my experience the edges of cataract knives or of iris scissors will not stand boiling in any solution no mat-

ter for how short a time. I always use pure carbolic acid for sterilizing them, steeping them in it for thirty seconds. This is a perfectly efficient method and does not injure cutting edges in the least. They should be rinsed out in a tray of rectified spirit and allowed to dry before use, being put back in the tray after use.

The other instruments should be boiled in a metal tray which has a perforated bottom and is large enough for them to be laid out side by side in the order in which they will be needed. The tray should be lifted out of the boiling water with hooks and laid in an enamelled iron dish which has also been boiled. The instruments dry at once and are to hand as they are required without having been touched by anyone's fingers since they were sterilized.

This is the point at which to emphasise that the use of sterilized gowns, caps, masks and quantities of towels is not necessary in order to achieve asepsis in ophthalmic surgery. These adjuncts are a positive danger if they lull the surgeon into forgetting that his fingers, the patient's skin, the eyelashes and the Meibomian region cannot be sterilized effectively in any way. The business ends of the instruments must not be allowed to touch these areas after they have been boiled, what happens to the handles is immaterial. I have seen surgeons of international repute forget this. Rubber or cotton gloves should not be used. They deprive one of the full sensitiveness of the finger tips. The bare hands should be dried in spirit after washing.

Preliminary Cleansing of the Field of Operation.

The face and eyelids should be well washed with soap and water and swabbed with mercury solution. There is no point in pressing the everted lids together to squeeze out the secretion of the Meibomian glands. There is one practice which makes the marrow freeze in my bones, that of turning out the lids and rubbing the conjunctiva with the bare fingers, with the idea of "cleansing" it. The eyelashes should be cut away in the outer third only to clear the field for the knife.

The eye which is not being operated on should be covered with a pad of wet cotton wool. For some reason this prevents the patient from blinking and moving his eyes about and from trying to see what is going on.

The Speculum.

The instrument I use is displayed in Fig. 3 (B). There are several points about it which I wish to emphasise. It has got no screw stop—a thing which is an abomination in cataract surgery. The inexperienced surgeon will always screw it up if one is present, and when an emergency arises suddenly, as it always does, he will be unable to remove the instrument promptly. The patient will then proceed to squeeze out the contents of his eyeball, or will get one lid slipped out of the speculum, perhaps while the surgeon actually has an instrument inside the eye.

The spring of my speculum is weak. A strong spring is almost as bad as a screw stop in providing the patient with a *point d'appui* upon which to squeeze.

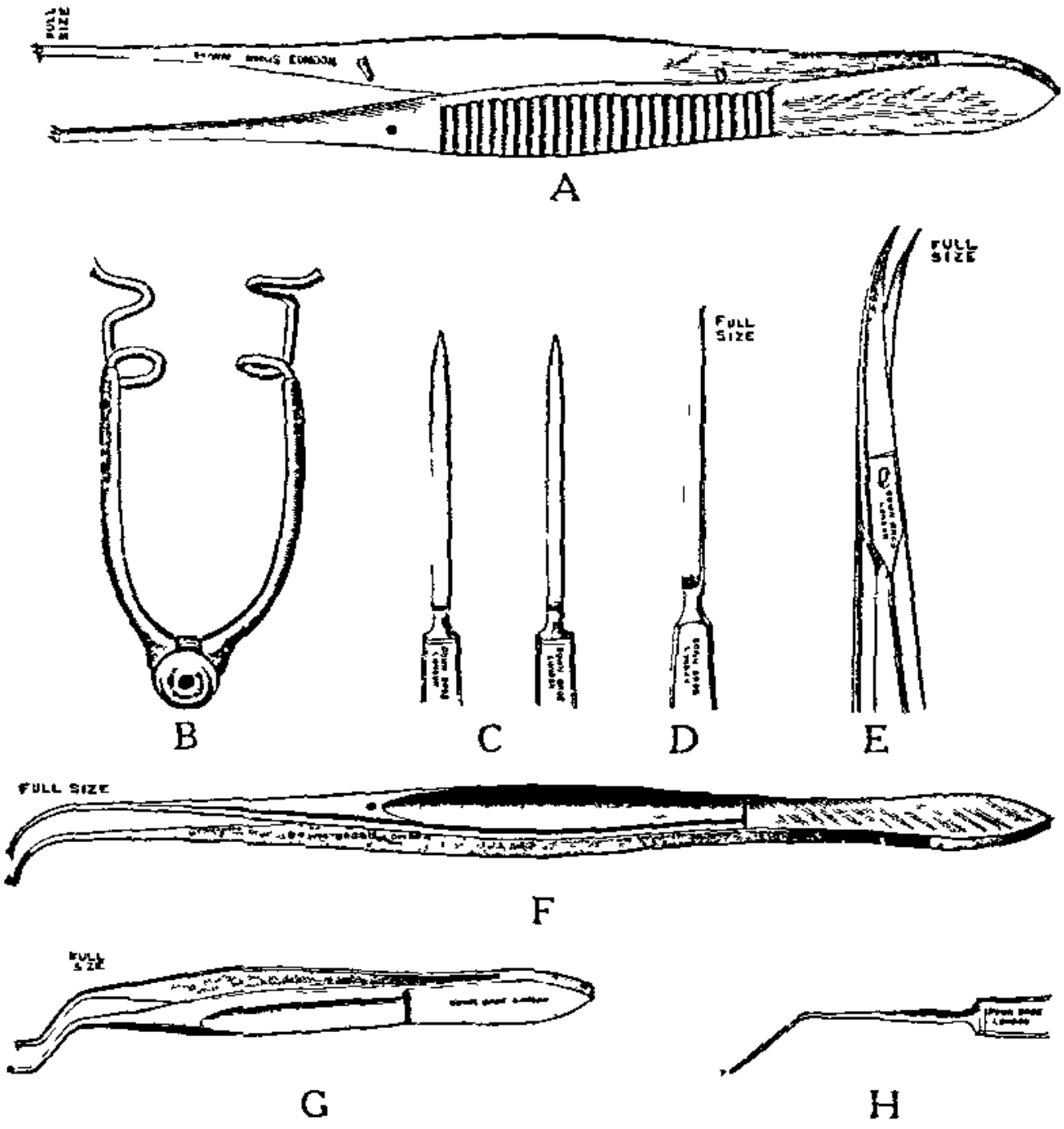

Fig. 3.

A—Fixation Forceps. B—Speculum. C—Cataract Knives, Graefe's. D—Cataract Knife, Smith's. E—Iris Scissors. F—Iris Forceps. G—Peripheral Iridectomy Forceps, Hess's. H—Capsulotome.

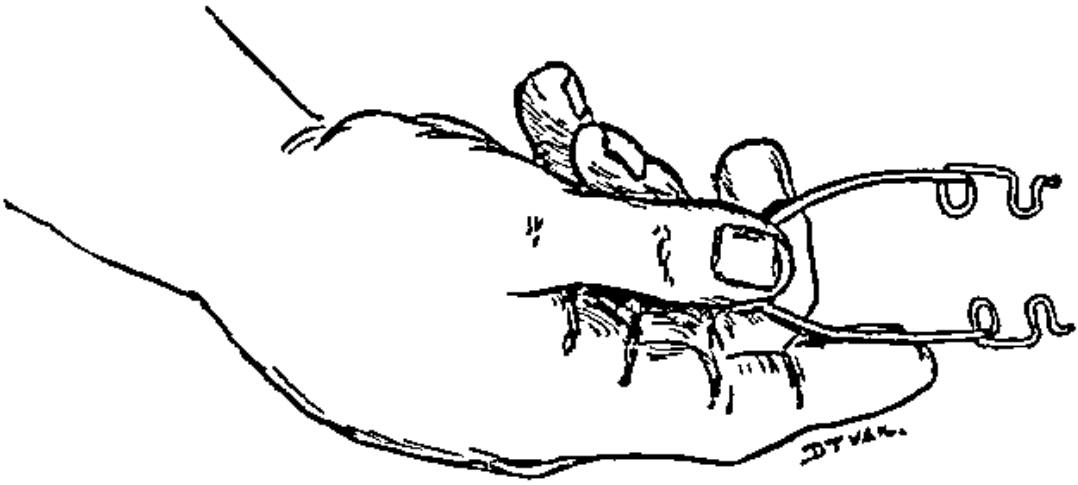

Fig. 4.

The correct grasp for introducing the speculum.

Fig 5

Shews the method of exposing the eyeball and cul de sacs for irrigation. The surgeon grasps the brow with a claw-like grip to overcome the orbicularis and draw the tissues beneath the fornix up towards the rim of the orbit while the left hand lifts the lids on the speculum In this way the recesses of the fornices are thoroughly exposed for douching prior to operation

The jaws of my speculum are narrower from side to side than is usual, but pass further under the lids. The usual jaws are so wide that they stretch the palpebral fissure unduly, so giving rise to pain, but are not deep enough to hold in properly. Specula made with the jaws of two bent plates of metal, with the idea of covering the eyelashes are often liable to slip out, but it is almost impossible for one of my designs to do so.

The proper grasp for the introduction of the speculum is shewn in Fig. 4. It must not be smeared on the skin, lashes or Meibomian area in the process. After the introduction the eyebrow should be drawn up on the forehead and the speculum lifted, so as to expose every recess of the fornices of the conjunctival sac. (Fig. 5). This should be douched out with a quantity of fluid delivered with sufficient force to have a scouring effect. I use a reservoir swung from the ceiling six feet above the table, and a wide-bore nozzle on the delivery tube. The nature of the fluid used is immaterial so long as it is sterile, as it is its mechanical action in washing away mucus and debris which is desired. My own preference is for perchloride of mercury solution, 1 in 2,000. This produces no objectionable irritation.

The Control of the Orbicularis Muscle.

It is well to discuss this in detail before going on to describe the incision, for it represents the foundation which must be well and truly laid before one can attempt to build the superstructure of extraction of cataract in the capsule. No matter what method is employed, expression solely by pressure from without, extraction from

within by any of the forms of capsule forceps, or a combination of the two, unless the orbicularis muscle is under complete control and prevented from making pressure on the eye, no surgeon can meet emergencies which may arise.

(a) While making the incision.

Control is sufficiently well obtained by the assistant drawing up the eyebrow on to the forehead with his thumb, so lifting the upper folds of the orbicularis off the eyeball. The speculum need not be touched until the incision is nearly finished, when if the patient is at all nervous it should be lifted gently to raise the lids off the eye, while the surgeon makes a slight pause to take the patient off his guard before he cuts out if he exhibits nervousness.

(b) While the iridectomy is being done.

Before the expression of the lens the assistant should have one hand in readiness to lift the speculum and to whip it out the moment the iris is cut. With the other hand he should steady the eye with fixation forceps. If the surgeon is skilled he can control the brow with the ring and little fingers of the hand which holds the iris forceps and if he is using De Wecker's scissors of the hand which holds them. But if he hesitates to do this, he must employ another assistant for the purpose. Failure to control the brow is responsible for the accident occurring of the lens and some vitreous being squeezed out, if the patient winces when the iris is caught.

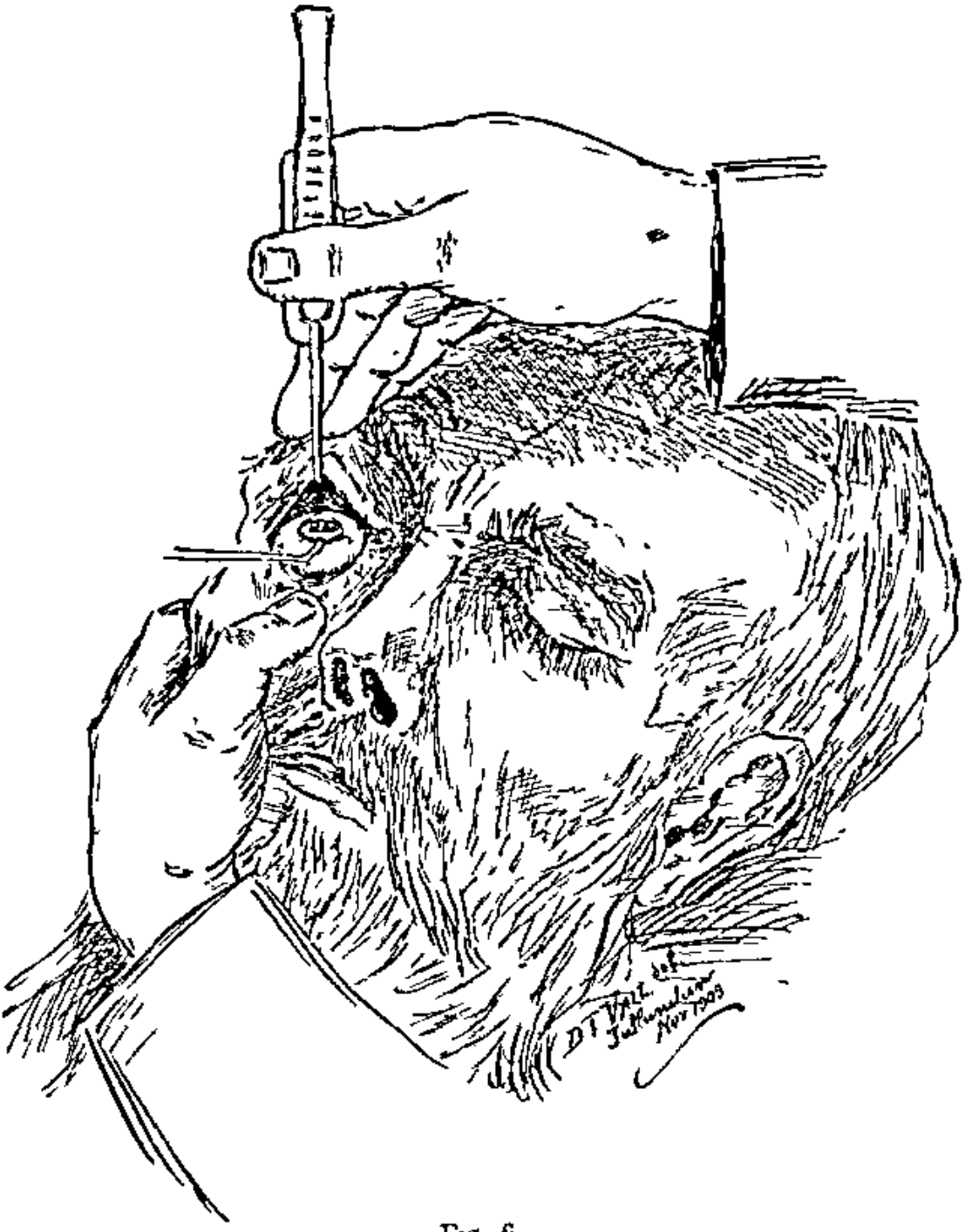

Fig 6

Showing the proper position of the assistant's hands in holding the eyelids, while the operator is expressing the lens in its capsule through an upward incision (notice how the eyebrow is being held up by the assistant's three fingers). The upper lid is hung on the lid hook exposing the summit of the eyeball The lower lid is everted by the thumb of the assistant's left hand.

The grasp of the lid hook as shewn here is rather too high up the shaft of the instrument for comfort (a mistake which is repeated in Figs 9 and 10.)

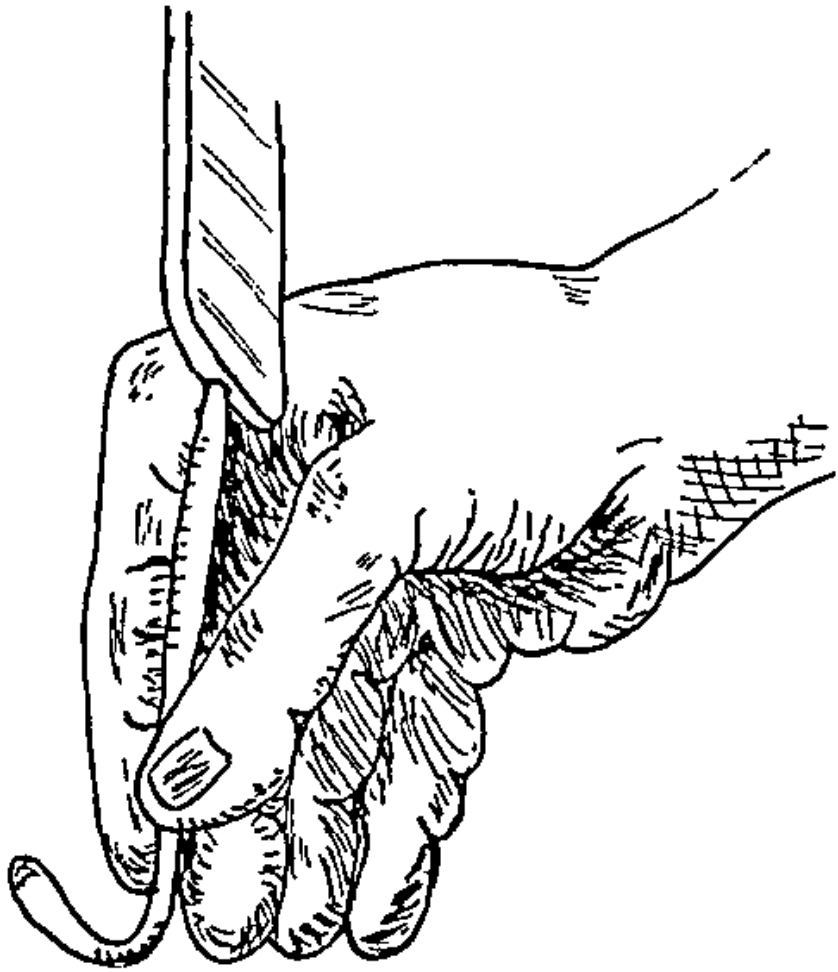

Fig. 7.

The correct place to grasp the lid hook, as near the bend as possible.

Since this accident is liable to occur unless the assistant is quick in handling the speculum, many of my pupils prefer to have the lids held apart with retractors while making the incision, the assistant being then in immediate readiness to control the orbiculars during the rest of the operation in the way I am about to describe. For this plan, there is not much to be said. Everything depends on the alertness of the assistant. If he is asleep, disasters will occur just as easily with hooks as with a speculum which has an advantage over retractors in that it is not in the way while the iridectomy is being done.

(c) *During expression of the lens.*

The speculum is removed and the assistant stands on the left-hand side of the patient.

After removing the speculum, the assistant standing on the surgeon's left, lifts the upper lid upon a squint hook with his right hand. The hook should be straight beyond the bend and long enough to reach well up beyond the tarsal plate. The brow is pressed back upon the forehead by the ring and little fingers of the hand which holds the squint hook. (Fig. 6). The mistake made lies in grasping the hook too far up the shaft; Figs. 6, 8, 9 which follow, were drawn from the pose of an assistant whose hands were far above the average size and should not be imitated in this respect. Fig. 7 shews the correct grasp.

When the section has been made it can be demonstrated that the globe fills up and the cornea is pushed

forward if the upper fibres of the palpebral portion of the orbicularis are allowed to exert pressure on it They can do this when the upper lid is pulled towards the brow as well as lifted forwards (Fig 8), while they are raised right off the globe if the upper lid is pulled slightly downwards as well as forwards The upper recess of the conjunctival fornix is then displayed and the cornea falls back flaccid (Fig 9)

The importance of pulling the upper lid slightly downwards when it is lifted off the eye should be thoroughly realised by the surgeon He must see that his assistant understands it before he proceeds with him to the actual removal of the lens The raw assistant naturally thinks that by pulling the upper lid down he is obstructing the surgeon's view It takes some time to convince him that the removal of all pressure upon the eye by the orbicularis must take precedence of the surgeon's view, which is actually not as much obstructed as he imagines

While the brow and upper lid are controlled in this way with his right hand, the assistant grasps the patient's face and chin firmly with his left hand A small piece of cotton wool under the ball of his left thumb, or a cotton glove, enables him to get a grip on the slippery skin, or this may be done by lifting it on a stitch He thus not only controls the orbicularis but steadies the head of an unruly patient

With care in training upon patients whose eyes are cocainised for other purposes than cataract operations one man can be made perfectly competent to do this

Fig. 8.

In this position the upper fibres of the orbicularis drop on to the globe and can exert pressure. The assistant must be trained to assume the position shewn in the next drawing (Fig. 9).

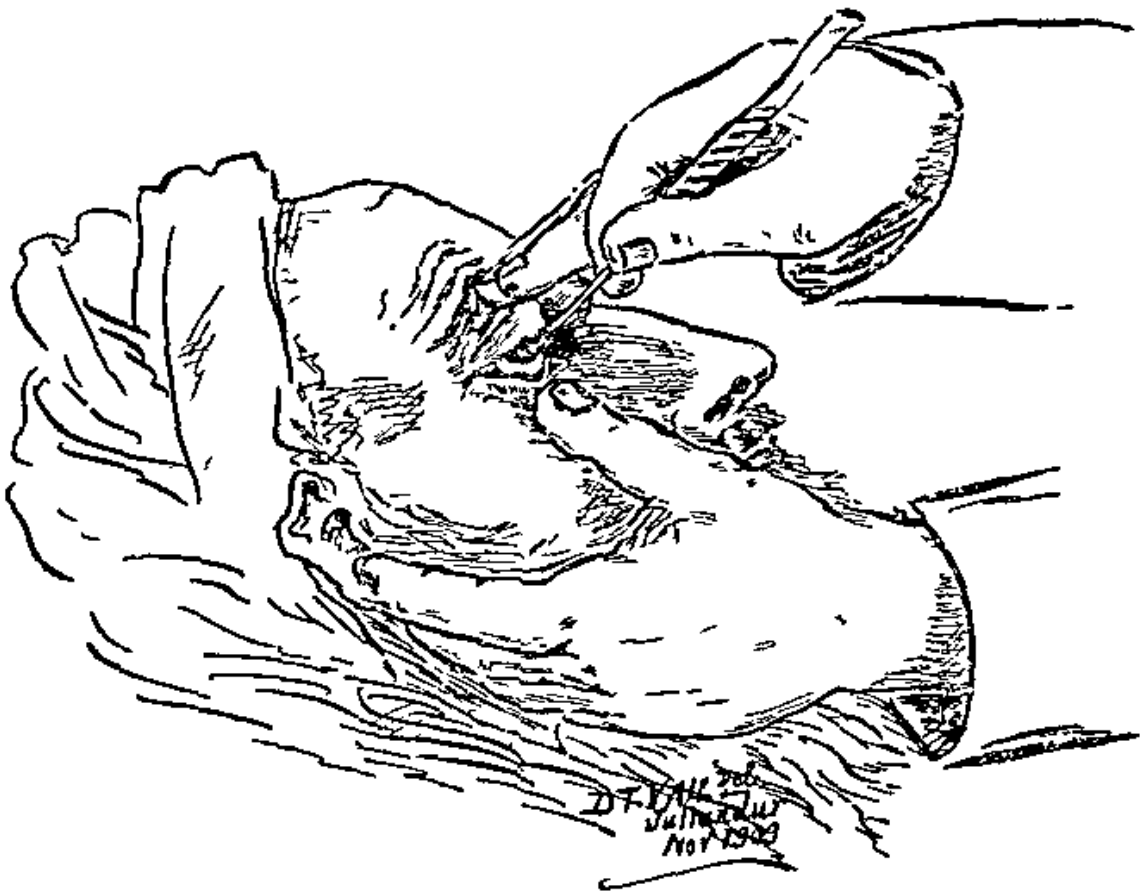

Fig. 9.

The assistant's right hand is leaned towards the patient's chin and the upper lid is pulled downwards as well as forwards. This lifts the upper fibres of the palpebral orbicularis off the globe and exposes the whole of the upper conjunctival fornix.

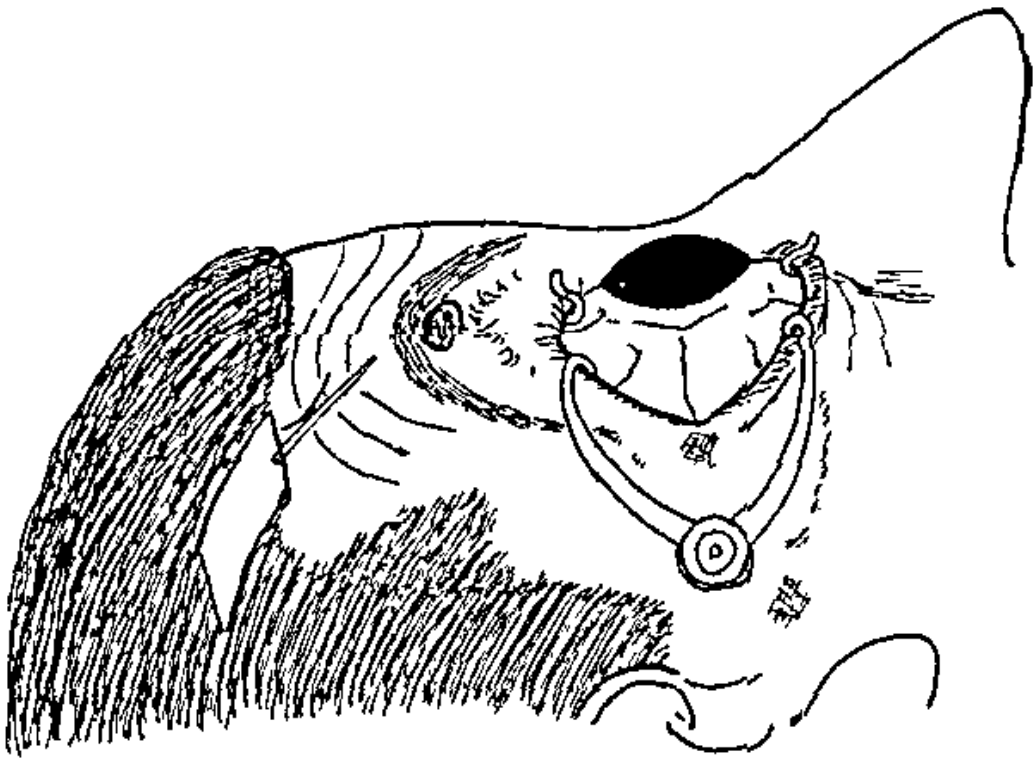

Fig 10

Brow stitch to assist in controlling the orbicularis A small area of the scalp is shaved and a piece of adhesive plaster stuck to it its lower free border being well above the limits of the frontalis muscle A stitch threaded on a button is passed through the tissues of the brow and then through the free border of the plaster and the two tied tightly together

whole job by himself. But many surgeons are unable to retain the services of one assistant for any length of time. These will find that if his work is divided between two people they will acquire the necessary dexterity much more speedily than will one.

Two further developments in eye brow and lid control should here be mentioned. In the first, a piece of adhesive plaster is fixed to the forehead well above the limits of the frontalis muscle, the hair being shaved, if necessary, over a small area. A stitch threaded on a button is passed through the brow from below and then through the tape and the two are tied together. In this way the brow is trussed mechanically and the patient cannot squeeze with the upper orbicularis. (Fig. 10.)

In the second, an adjustable metal head band is employed of the type used for suspending head mirrors with a ball and socket joint on it which is controlled by screw. Into this joint fits a notched arm and the hook upon which the lid is suspended ends above in a loop which is slipped into one of these notches. The surgeon can adjust the position of the lid to an absolute nicety before beginning work by moving the notched arm, altering the notch into which the hook is slipped, and if necessary, bending the point of the hook with his fingers. The assistant then, his two hands perfectly free to control the brow and the lower lid and to steady the patient's head, grasps it firmly but not so tightly that the patient realises he is being held. If the patient should then suddenly shake his head, the lid hook moves automatically with it, and still maintains perfect control,

while if an emergency arises the surgeon can simply knock down the notched arm and the hook will fall out. (Fig. 11.)

I have never claimed to be the first man to extract cataract in the capsule as a routine. But I think I can fairly claim to have been the first to lay down the fundamental importance in the intra-capsular operation of this control of the lids and to have worked out the method of doing it. I wish to emphasize that to rely on the use of novocaine for the purpose of paralysing the orbicularis is to rely on chance. It does not enable us to dispense with the aid of a competent assistant, even in the capsulotomy operation.

Talking to the Patient during the Operation.

The patient should not be worried during the operation or before it by giving him orders if it can possibly be avoided. His nerves are on end for he knows or thinks he knows that the slightest wrong movement will make him blind for life. Preliminary training to get him to move his eyes in any given direction will only have increased his nervousness by making him "die many times before his time." And the more we talk to him during the operation the more irritable will we make him and the more likely to give unintentional trouble. The surgeon should take his patient quietly and ask no favours, but proceed to operate in whatever position he finds the eye. He must not let the patient feel by his language or by his acts that he has lost his temper either with him or with his assistant or has got "nerves."

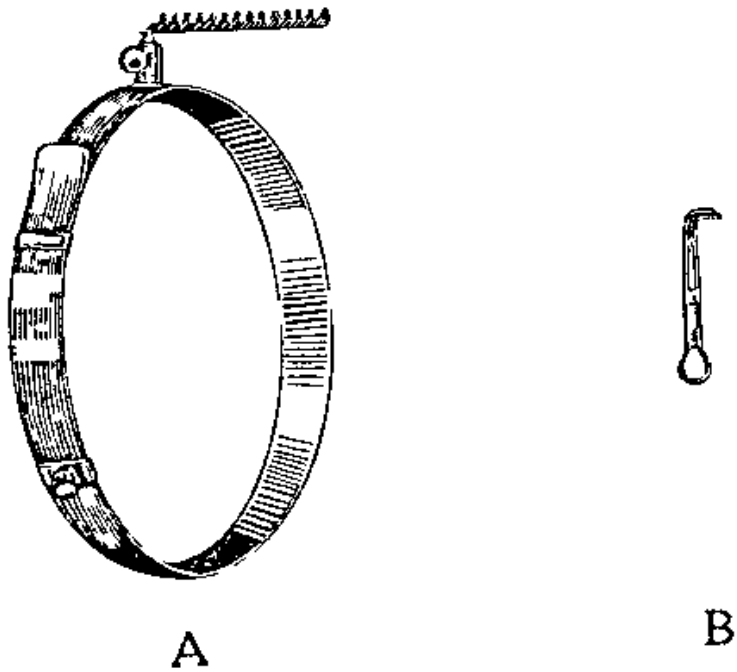

Fig. 11.

Adjustable head band support (A) for upper lid hook (B). (Made by Down Bros.)

The ideal operator is the man who never gets irritated and has no "nerves."

For this reason he should neither talk to his assistants nor let them talk to him, but enjoin absolute silence in the theatre. He should have his assistants trained beforehand to do what is necessary at the right time without orders.

The Knife.

The ordinary new Graefe's knife is far too stumpy in the point. The knife I have had designed for me is modelled on the Afghan war knife, incomparably the finest puncturing instrument in existence. The back is perfectly straight, the edge nearly so and slopes to meet the former all the way from the heel to the point. (Fig. 3, C, D.)

The point of the knife is thus very fine and will puncture the coats of the eye much more easily than will the point of the ordinary Graefe's knife. This is the only thing that the point of any knife should be asked to do. It should never be used for cutting but reserved solely for puncturing. It is the part of the knife which wears out first, and if used this way we will get the full life out of it. But it is very common to see the point of a knife made to cut, and therein my knife is at a disadvantage for it is very easy to break the point of it if used for this purpose. For the same reason though the experienced surgeon will prefer to any other a thin bladed knife which has been resharpened several times, the beginner will probably be better advised to

use a really sharp knife with a stiff blade until he has learned how to handle it properly

My knife is unsuitable for simple iridectomies on account of its fragile point

The Fixation Forceps

These should be of the usual pattern but without a catch If one is present, it should be taken out, for the surgeon must be able to let go the conjunctiva instantaneously There should be two and three teeth in the jaws The type with only one and two teeth takes too small a grip of the conjunctiva and is liable to tear it

How to Hold Knife and Forceps

That this is of importance should be self evident, but many operators do not seem to realise it when we see them at work

Both hands must be steadied by resting them on the patient's head, which at the same time helps to control the patient The hands can never be as steady if unsupported, and if the patient gives his head a sudden shake, as he not infrequently does, most undesirable consequences will ensue unless the hands are resting on it and so move with it

From now on I am assuming that the surgeon is right handed and is standing above the patient's head as he makes the incision upon the patient s right eye He should hold the toothed forceps as one holds a pen, taking a grasp of the conjunctiva and subconjunctival

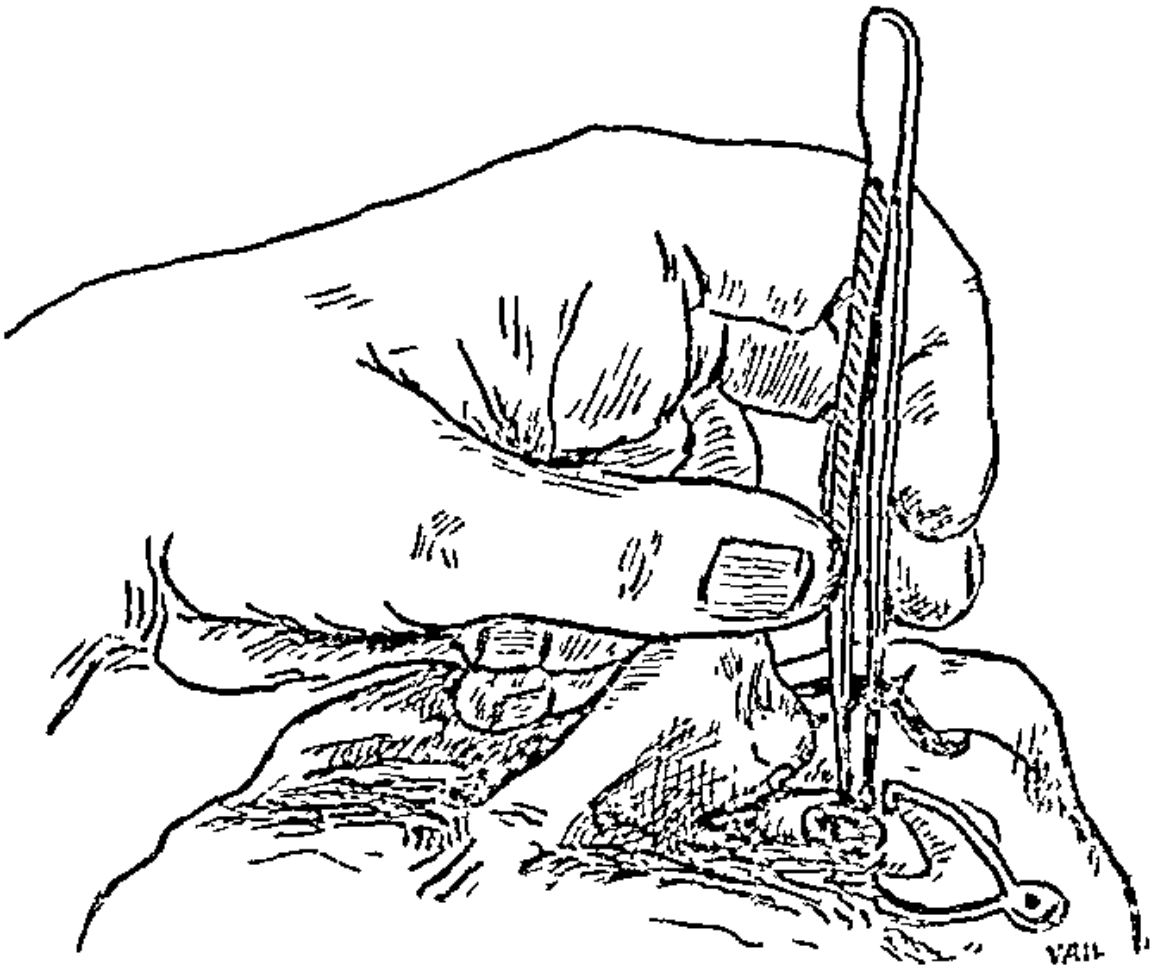

Fig 12.

The position of the left hand in using the fixation forceps to steady the eye for section. Note how the little and ring fingers are resting on the patient's head.

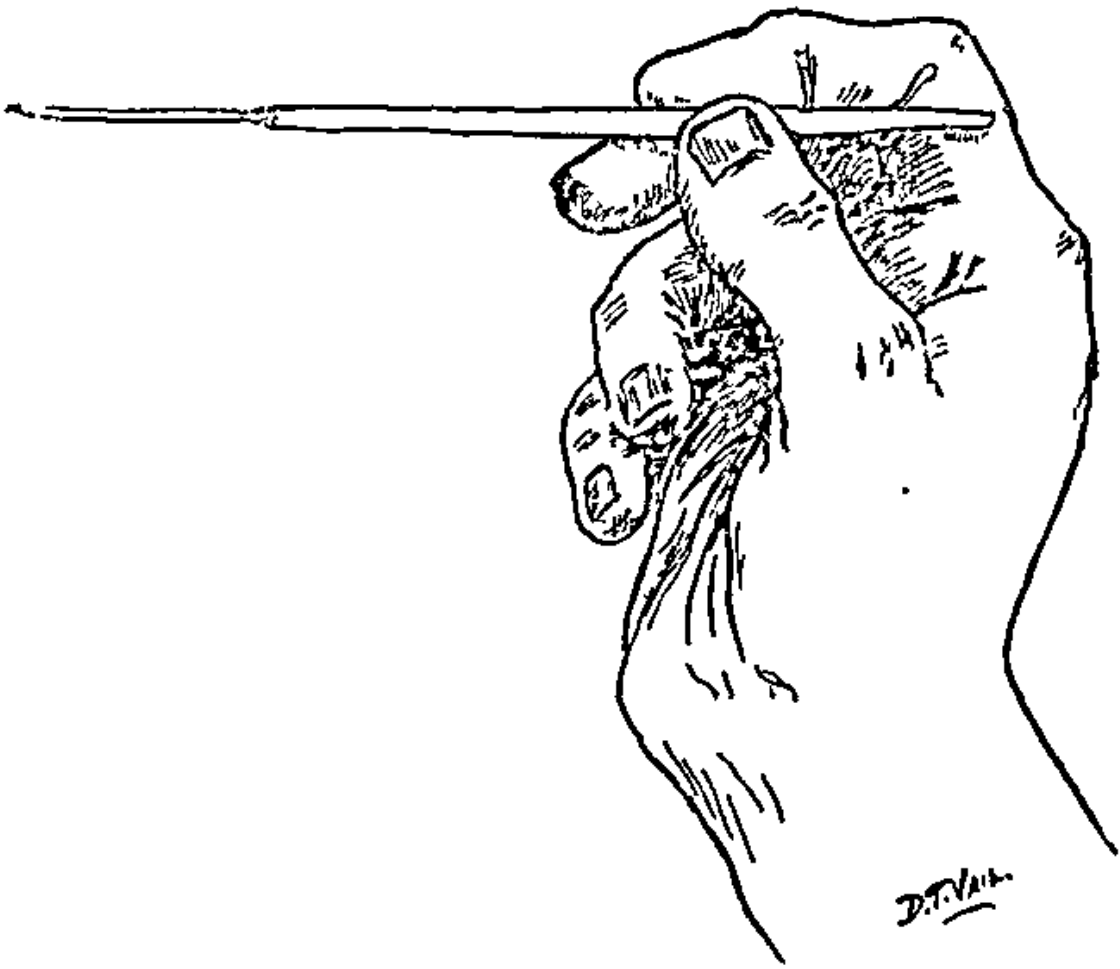

Fig. 13

The first position of the hand and the proper grasp of the knife—a little behind the centre of the handle and very lightly.

tissue in the mid-line below and *as close as possible to the limbus*. The conjunctiva *away* form the cornea is lax and gives no control over the eye and is more liable to give way than *close* to the cornea. The handle of the forceps should then be drawn across the bridge of the nose out of the light. The ring and little fingers of the left hand should be flexed at the proximal interphalangeal joint and rested on the patient's left cheek and against the left side of the nose. In this way the left hand will both be steady itself and will steady the patient's head, while it is not obstructing the light. (Fig. 12.)

The knife should be held as one holds a pen in writing, if anything more lightly, so that one can alter the direction of the edge of the blade by rolling the handle between thumb and fingers. The grasp of the handle should be taken a good distance from the blade, well back of the centre. (Fig. 13.) The direction of the edge should always be verified before making the puncture. Such advice may sound unnecessary but it is not. If after making the counterpuncture one finds that one has neglected this precaution and that the edge of the blade is turned down, it must be corrected by turning the knife over with its back against the iris and the incision be continued as if nothing had happened.

The tip of the little finger should be rested against the patient's temple. The other fingers and the thumb should now be drawn back, without shifting the grasp upon the handle of the knife, as far as is convenient, so that the hand comes to have the appearance of a

partially closed fist. (Fig. 14.) The point of the knife should then be fairly close to the spot at which it is to be entered.

Making the Incision.

From this position the knife is entered and driven across to the heel by straightening out the fingers (Fig. 15), the handle being dropped after the counterpuncture, so that the point is raised and can pass across the bridge of the nose if necessary. The raising of the point is achieved by a slight movement of supination of the wrist, followed if necessary by dropping the handle into the palm of the hand.

The surgeon must realise that if the incision is to be made dexterously, the muscles which actuate the fingers must be used to the fullest extent of their power, those which actuate the wrist, to a lesser extent, and those which move the elbow and shoulder, not at all. He will then be able to give the knife the necessary draw across the tissues, without which no knife will cut properly. If he does this he will be able to make most of the incision with one sweeping cut forwards, completing it with a single draw back, and it will be clean cut and without ragged edges.

If we watch an operator carefully who adopts the common method of making an incision by sawing to and fro, it will be seen that the knife is in reality being moved from the shoulder joint. This abolishes all delicacy of touch. It will next be evident that the movements are so short that the eyeball swings to and fro

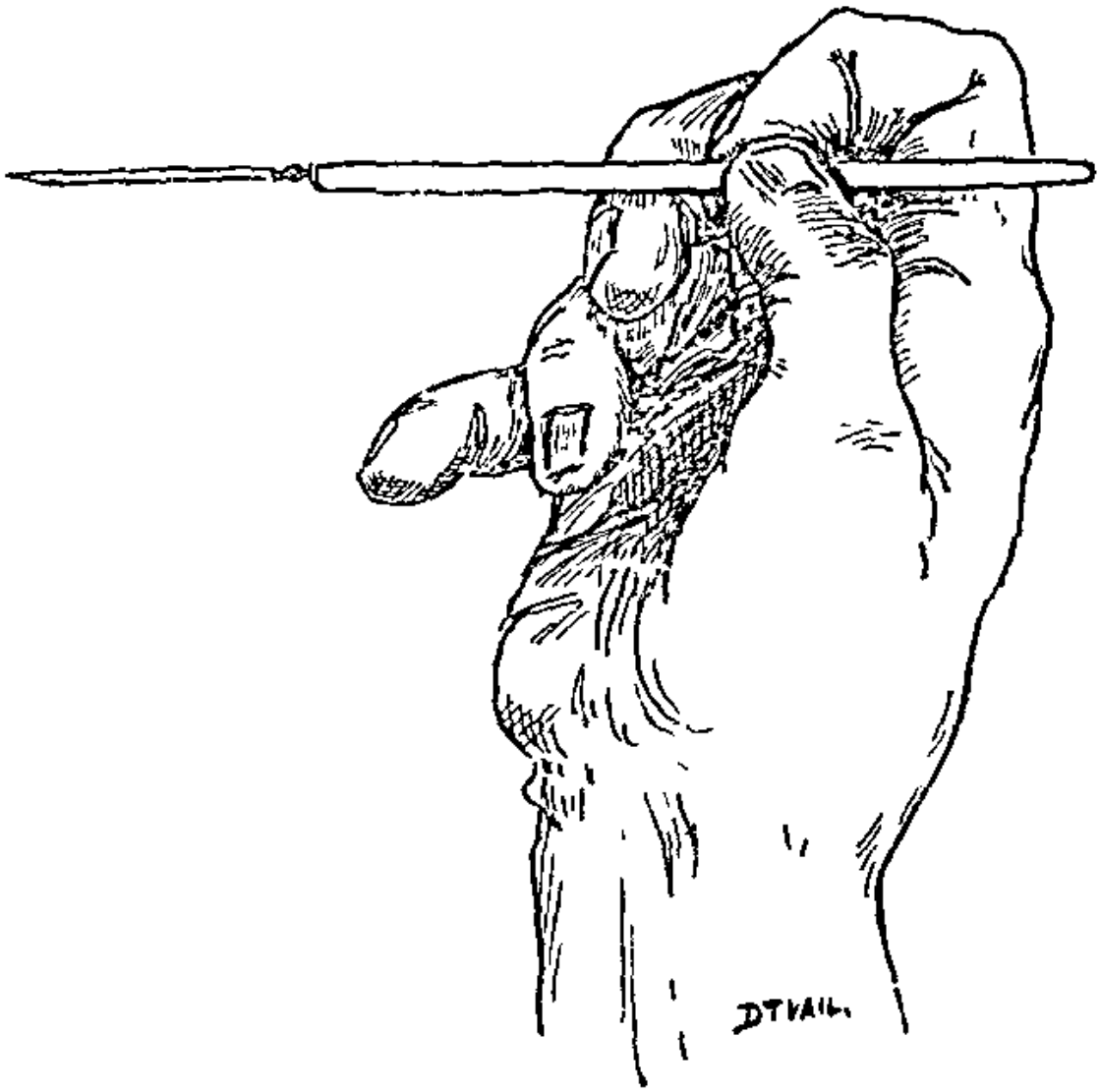

Fig. 14.

The second position of the hand. It is steadied by resting the tip of the little finger against the temple, while the knife is drawn back by finger flexion so that the point can be applied to the sclero-cornea.

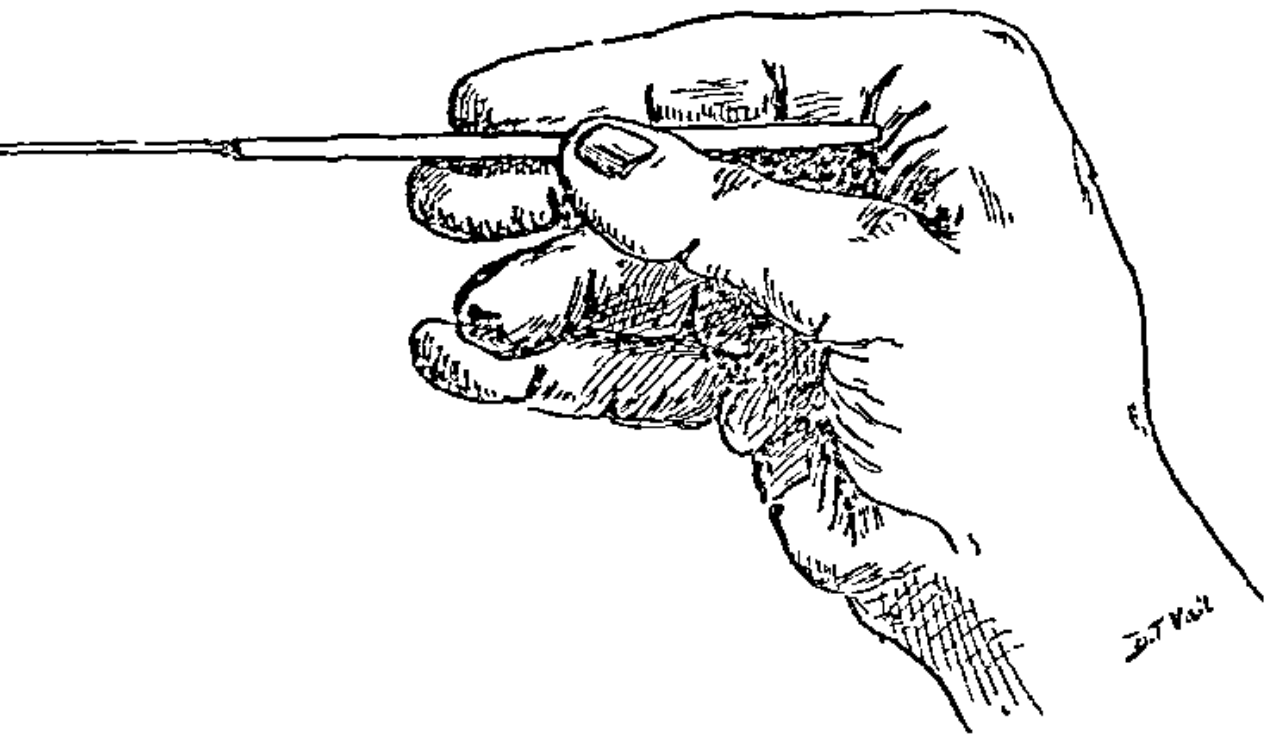

Fig. 15.

The third position of the hand in making the section The fingers have been straightened out. The knife is held lightly and the position is favourable for dropping the handle into the palm and continuing the forward cut until the blade is through to the hilt, when by raising the handle the section is completed.

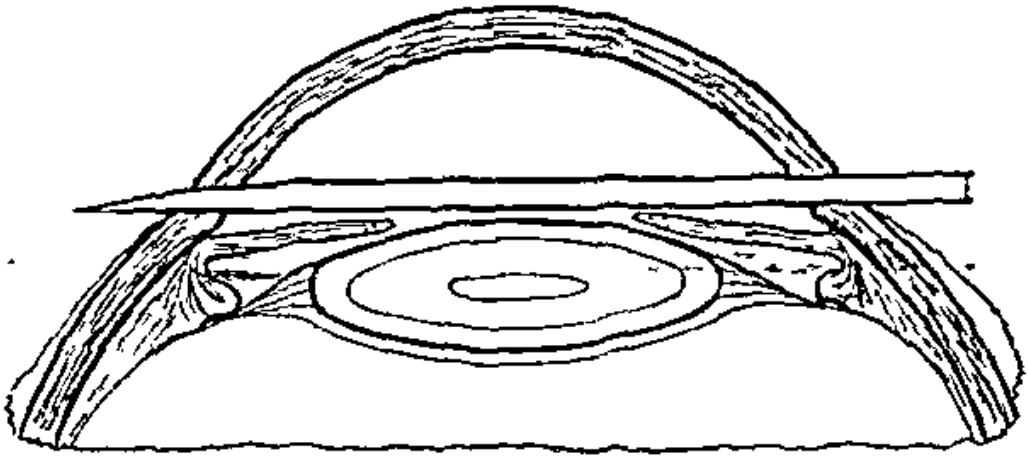

Fig 17.

Puncture and counterpuncture have been made with the blade of the knife turned forwards 30° from the plane of the sclero-cornea and there has been no splitting of the coats of the eye.

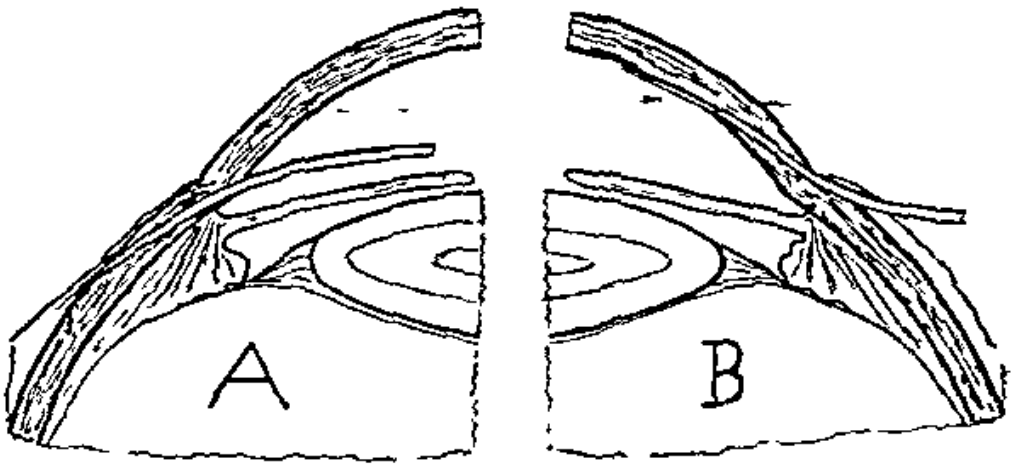

Fig. 18.

A thin bladed flexible knife has been used and has been entered on the flat at the puncture (B). The point travels forward between the corneal lamellæ, a long way before entering the anterior chamber, thus considerably reducing the effective size of the section Similar splitting of the sclerotic takes place at the counterpuncture (A), the knife passes through the deep vascular region and causes a lot of bleeding.

with the knife. No draw across the tissues being imparted to the edge, the incision when completed is found to be ragged. Finally, he has a great tendency to use the point of the knife for cutting and destroys its usefulness for its proper function of puncturing.

In making the incision in the way I have described there are a few matters which require emphasis. While making the puncture the handle should be held fairly firmly, but *without any pressure* with the point on the eyeball which would bend the blade on the flat. The back of the knife should be parallel to the plane of the sclero-corneal ring, the edge turned forward so that the blade makes an angle of 30° to that plane. If held this way the edge will cut as the point passes through and it will come out in the anterior chamber exactly where it is intended. (Fig. 17.) If the blade is held on the flat in entering and is at all flexible it will split the cornea. I have more than once seen surgeons, even of considerable experience, when using a flexible, much re-sharpened knife, drive the point half way across the cornea between the lamellæ before getting it into the anterior chamber. (Fig. 18.) The new rigid Graefe's knife will not do this, and is much less pleasant to use, owing to its stumpy point, than one of my straight backed ones or an old knife re-sharpened.

A *method often recommended is to enter the knife* at right angles to the surface of the sclero-cornea, *i.e.*, pointing towards the centre of the globe. It had its origin I suppose, in endeavours to avoid spliting the

corner It is an excellent method of ensuring that the point shall stick into the iris especially when the knife plunges in heavy hands as those of a beginner or of an occasional operator must be The iris will be caught up so near its root (Fig 19) that it will be very difficult to disentangle the point from it while if the knife is pressed on, it will probably tear it clean away from the ciliary region This plan is a most dangerous one to recommend If the knife is entered with the edge turned forwards 30°, all difficulties will be solved

Once the point is into the anterior chamber the blade should be turned again on to the flat When the knife is being passed across the anterior chamber the grasp on the handle should be relaxed so that it is held as lightly as a feather If it is held with a firm grip the heel will act and aqueous will be let out, ensuring trouble later with the iris coming forward over the edge of the blade Pressure with the point of the fixation forceps at any time will make this happen too The eyeball should be *pulled* with the forceps in any direction required, *not pushed* as is the usual beginner s fault

If the point of the knife catches in the iris it must be withdrawn until it is free Before being passed on again across the pupil it should be swept up to avoid the place where the iris has been punctured for if passed straight on, it is difficult to avoid catching it up again at the same place When safely across the pupil the point is brought down again to the level at which it is desired to make the section

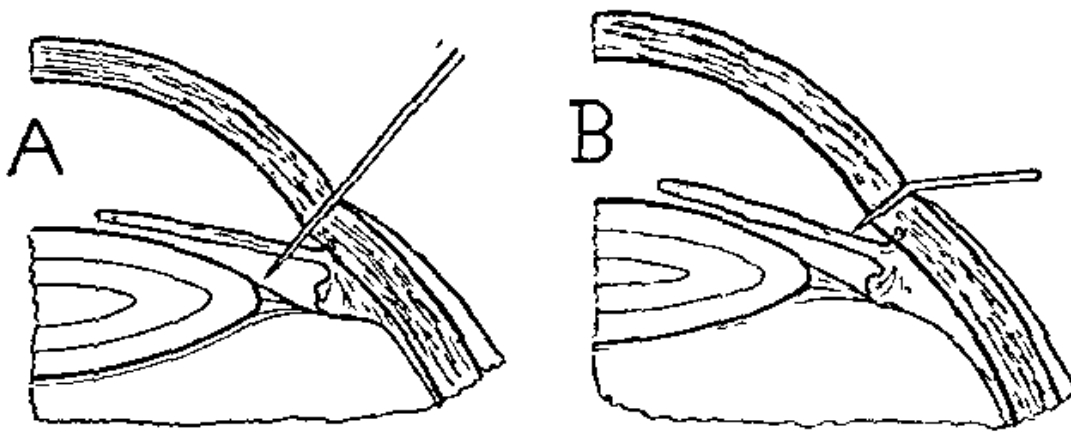

Fig 19

The knife has been entered at right angles to the surface of the sclerocornea at the puncture. In A it has plunged and picked up the root of the iris In B it has not plunged, but the point has been bent when the handle was dropped preparatory to passing the blade across the anterior chamber.

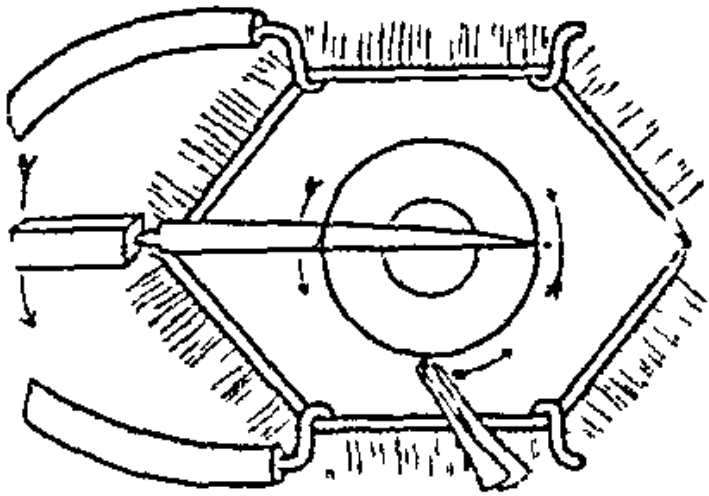

Fig 20

Counter Puncture, First Position — The point of the knife is just showing through the selerotic. Before cutting out the handle is dropped in the direction of the arrows by supinating the hand, the eye being pulled with the fixation forceps in the *same* direction as with the knife.

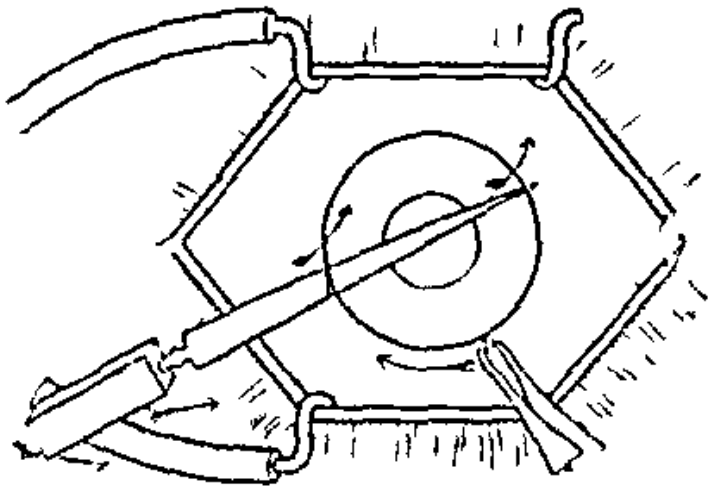

Fig 21

Counter Puncture, Second Position — No aqueous has escaped as the handle has been dropped and the knife is now in a position to be driven through to the hilt by straightening the fingers, the handle being still further dropped in the process and the eye being pulled *against* the knife with the fixation forceps.

In making the counterpuncture the knife should again be grasped more firmly. As in making the puncture if the edge of the blade is turned forwards 30°, the surgeon will avoid splitting the coats of the eye and having the point emerge far out in the sclerotic where it will cut the deep vessels and cause annoying bleeding. (Figs. 17, 18.)

As soon as the point shows through at the counterpuncture before the opening is large enough to let out any acqueous, the handle should be dropped by a slight movement of supination of the wrist. (Figs. 20 & 21.)

This will raise the point and enable it subsequently to pass over the bridge of the patient's nose if necessary. This dropping of the handle is a preliminary manœuvre for position which should be done before the knife is made to cut. If it is omitted the surgeon will find difficulty in completing the incision with the one sweeping cut forwards and a single draw back, without pressing on the globe and driving the iris forward. If he is using a straight backed knife, the slender point should be made to come out clear before starting to drop the handle or it will be broken. Owing to the fact that both point and heel are cutting the whole time, this can be done without fear of losing acquous. With the ordinary Graefe type there is not so much danger of breaking the point but there is danger of making a big hole which will let out acquous if it is driven right through before dropping the handle. Pressure on the eyeball during this manœuvre by heavy handling of either knife or forceps will mean

loss of aqueous and will drive the iris up over the blade of the knife

Having got the knife into the right position the direction of the edge should be corrected by rolling the handle between the thumb and fingers It should then be pushed through to the hilt by straightening out the fingers It should be made to cut on the nasal side only, but as heavily as possible, by dropping the handle and raising the point still further as it is passed through (Fig 22)

As skill is gained the surgeon will learn to pull the eyeball over with the fixation forceps against the knife which makes it easier to push the latter through to the hilt This should generally complete the incision if the knife is really sharp (Fig 23) But if it does not, a single light draw back will suffice, using this time the heel of the knife to cut out on the temporal side, while on the nasal side the blade is just kept lightly in apposition with the wound (Fig 24) *The instant the blade has cut out, the left hand must let go its grip with the fixation forceps*

Why should we not make the blade cut both sides of the incision at the same time? The practical fact is that it cuts much more readily and with much less pressure if asked to do only one job at a time The manœuvre of completing the incision with one upward sweep of the knife will only be successful after real skill has been gained, and then only if the edge of the blade is of exquisite sharpness If the beginner attempts to make the two hands work in unison before one has

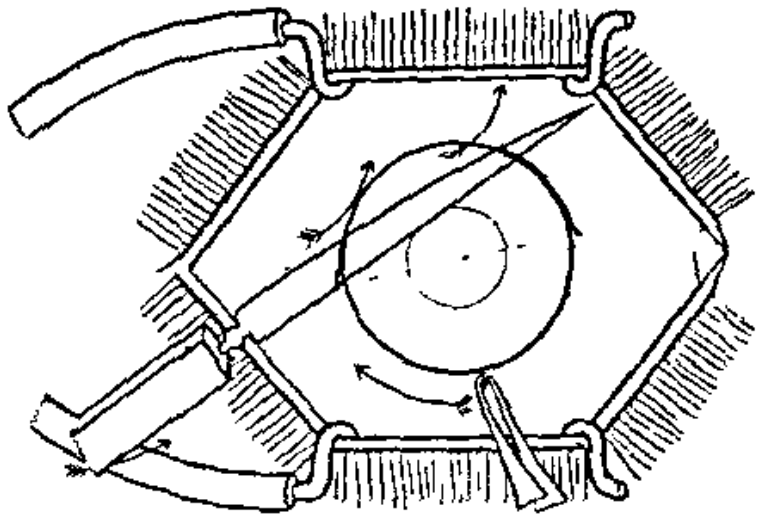

Fig 22

Beginning of the Section.—Shewing the effect of the *movements initiated* in Fig 25. The knife cuts on the nasal side only The point will clear the root of the nose as its travel is continued

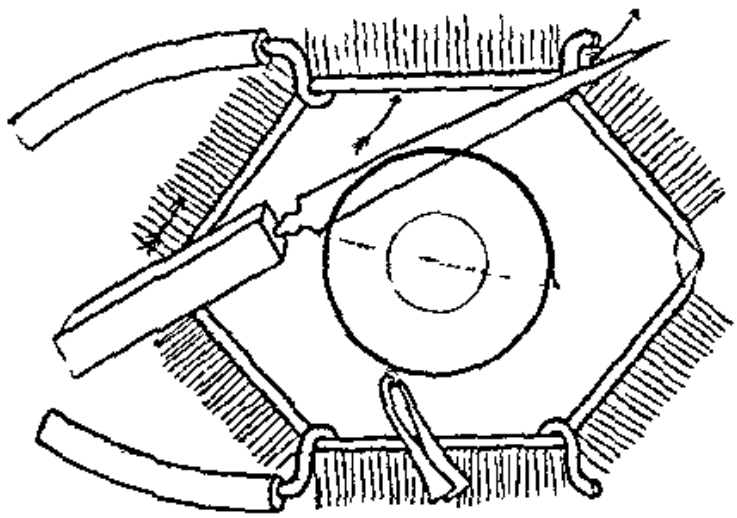

Fig 23

Cutting Out.—The section has been made in one sweep Before finally cutting out, there should have been a momentary pause to catch the patient *off his guard.*

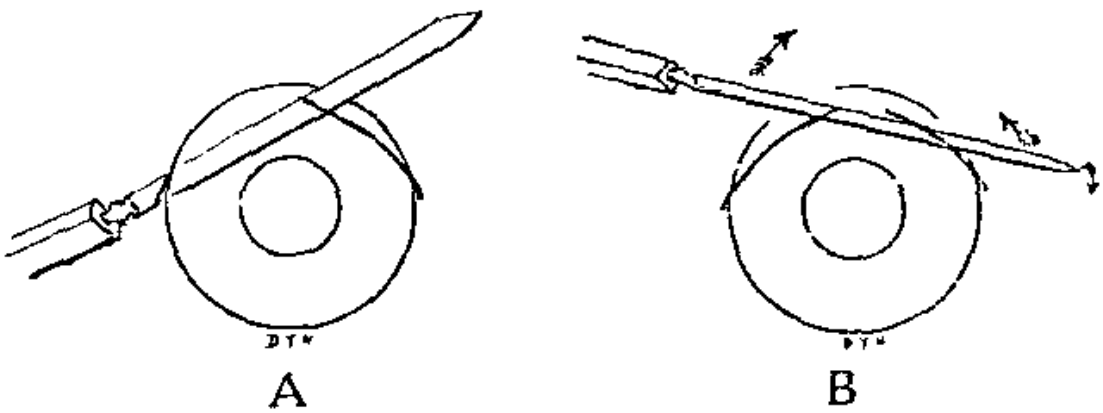

Fig 21

A —The nasal half only of the incision has been completed by the time the knife is through to the hilt At this stage the temporal half is completed by raising the handle of the knife as it is withdrawn to reach position B Here a slight pause should be made before finally cutting out

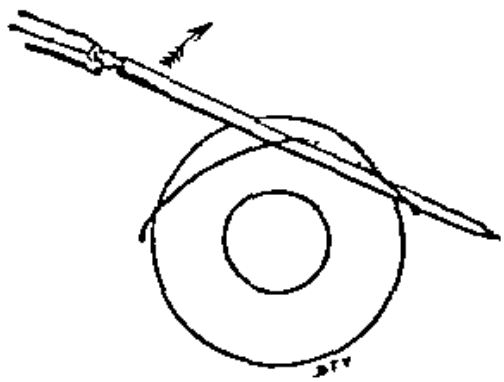

Fig 26

In deep set eyes where it is impossible to pass the blade through to the hilt the point of the knife is pushed into the skin of the nose. Using this as a fulcrum the incision is completed by a quadricircular upward sweep of the handle

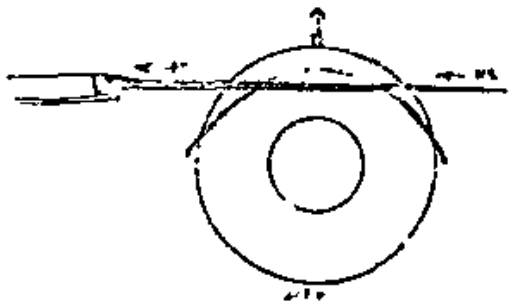

Fig 25

The iris has threat ned to come forward over the blade, owing either to pressure with knife or fixation forceps, or to the patient squeezing. By turning the edge of the knife forward and cutting out slightly forward an the cornea the incision can be completed without slicing the cornea

learnt his job he will only put pressure on the globe, force out aqueous with a spurt and bring the iris up over the blade of his knife. This is the commonest trouble he has. When it happens the only thing to do is to turn the edge of the blade forwards so as to cut out a little forward in the Cornea. (Fig. 25.) Go straight on and complete the incision as if nothing had happened. Hesitation and endeavours to avoid cutting the iris will only make matters worse.

Should the patient wince or squeeze as the incision is finished, he will be liable to express the lens and some vitreous. If there is any risk of this happening whether because he is given pain by the iris being caught on the knife or because he is a nervous patient, the surgeon should pause before he finally cuts out. This will take the patient off his guard. He is watching like a cat for the completion of the incision, but cannot keep up his concentration for more than a few seconds. The pause will also enable the assistant to lift the lids on the speculum as the incision is being finished and to whip it out instantly when the surgeon lets go his grip with the fixation forceps, though he should maintain his grip upon the eyebrow. It is in these cases above all others that both surgeon and assistant must be prompt in removing their instruments from the eye on completion of the incision.

Three quarters of the battle in intracapsular extraction *lies in making the incision properly. The full* advantage must be taken of the depth available in the sclero-cornea and valuable width must not be lost by

splitting the cornea. The secret of success lies in appreciating the angle at which the edge of the blade lies in relation to the plane of the sclero-corneal ring. In teaching men to operate on the living subject, it is rare to meet one who appreciates it from the start. For some reason the edge always appears to be turned a little further forward than it really is. The beginner expects it to cut as if it were on the flat when in reality the edge is turned a little backwards as if he intended to catch the iris with it. It is needless to say that when this is the case he is not pushing the knife against the edge, and he complains that it is blunt. When shewn his mistake, and he is careful to see that the edge appears to be turned a little forwards, he finds that the knife cuts and that the fault before was his and not that of the instruments.

Though the incision has been described as if it were done in stages it is really one act, not a series of acts, performed deliberately and steadily, equally without hesitation and without haste. To make it as described with the sweeping cut once forwards and then backwards needs some practice. The co-ordination of hand and brain in the movement required can be obtained to a considerable extent by practising on grapes, which form an excellent article for the purpose. When facility has been gained on them the eyes of six weeks old kittens should be used, mounted fresh immediately after they are killed. Their usefulness for this purpose was pointed out by Dr. W. A. Fisher of Chicago, the cornea in them being 11 mm. in diameter, and very nearly of

the same thickness and toughness as in the human eye. This use of kittens eyes supplies a much felt want in the instruction of surgeons whose opportunities for operating are limited. And a considerable economy can be made in them by previous practice on grapes.

The Incision on the Left Eye.

Ambidexterity has no meaning in ophthalmic surgery, for there is no advantage to be gained by it. The incision can be made in the left eye with the right hand by adopting the simple expedient of standing by the patient's left shoulder instead of by his head. And it will be found, if anything, easier to make than that on the right eye.

I have seen many ambidextrous men, and I have never seen one whose two hands were equally good as far as cataract work is concerned. The patient has certainly a claim to the surgeon's best hand. The amount of cunning which can be developed in the hand seems to be limited only by the practice which it gets. No cunning of the hand can be too great for cataract surgery, and it is folly to divide one's opportunities in two by playing to the gallery with a show of ambidexterity.

This view of monodexterity is exactly what Adam Smith advocates in his "Wealth of Nations" and illustrates by the art of pin making. The two hands of the surgeon should stand in the same relation to one another as do individuals in pin making. Each should be trained to do its special work alone, and each will then acquire the highest degree of skill that is possible. No surgeon has so much opportunity of acquiring skill

in cataract surgery that he can afford to divide it in two by attempts to make each hand cover the whole field. Nor need anyone expect that he will cultivate a really good "pair of hands" in a few days for this highly technical art

The Situation and Size of the Incision

The way often adopted of describing the size of the incision in millimetres is not practical In the eye we have landmarks which are plainly visible, the sclero-cornea and the centre of the pupil These are sufficient for all practical purposes

I Where to Make Puncture and Counterpuncture

The importance has already been mentioned of using the full depth available in the sclero-cornea at the angles of the incision I wish here to emphasise again that the root of the iris is much further behind the sclero-corneal junction than is commonly realised The point of the knife can be entered quite one millimetre outside the limbus without any fear of injuring the iris or ciliary body if the back of the blade is parallel to the plane of the sclero-corneal ring It can similarly be made to emerge well in the sclerotic at the counter-puncture By this means the incision is made as wide as it can possibly be with the particular proportion of the corneal circumference that is chosen for the section This not only gives the maximum room for the emerging lens to pass through, so lessening the liability to rupture of its capsule, but it also makes the base of the corneal flap broad in proportion to its length, interfer-

ing least with its nutrition, and by keeping the edge of the blade turned forwards at an angle of 30° while making puncture and counterpuncture, not only is splitting of the coats of the eye avoided but the incision is quickly carried forward out of the filtration angle.

II. Where to End the Incision.

It is clear that the nutrition of the cornea must be conveyed from the periphery towards the centre, owing to the absence of blood vessels in it. Hence an incision in one of the diameters of the corneal circumference would interfere least with the channels by which it is conveyed. The optical effect of such an incision would of course render it absurd. But we must remember that radial punctures in the cornea heal almost without a scar, and that the further from its centre the incision for the extraction of a cataract ends, the worse is the nutrition of the corneal flap. The addition to it of the usual conjunctival flap does not diminish but increases the strain on the emergency mechanism brought into play, for in the first few days it is entirely dependent for its nourishment on the cornea to which it is attached.

There is another theoretical reason for avoiding the sclerotic as much as possible. That is the close proximity of most important structures—the Canal of Schlemn and the spaces of Fontana. The nearer our incision is to it the more likely is it to be obliterated in a great part of its length by the inflammatory reaction during healing. If we go in for a deep scleral section in order to get an extensive conjunctival flap we run con-

siderable risk, at worst, of actually wiping out these structures with the blade of the knife, and at best, of getting the root of the iris adherent to the scar and so blocking up a large part of the filtration angle

Hence the incision should be kept clear of the sclerotic unless there is some imperative necessity such as exists in the angles of the wound owing to the need of room for the lens to emerge

The theoretical disadvantages of a conjunctival flap being clear, it remains to examine the grounds on which it is alleged to be advantageous The first of these is that it seals down more quickly than the corneal wound itself and so helps to prevent prolapse of iris

The type of flap usually made in finishing the incision is in the wrong place to prevent prolapse after an iridectomy, for this takes place in the angles, not in the centre of the wound to which the flap is confined The type of flap which should be most effective is that devised by Czermack A small incision is made in the conjunctiva tagential to the sclero cornea but some distance from it Through it the conjunctiva and subconjunctival tissues are separated from the sclerotic with a blunt dissector widely on either side right up to the cornea Under cover of the conjunctiva a small incision is made in the sclerotic with a Graefe's knife and extended with scissors on either side All the subsequent manipulations for the removal of the cataract are carried out under cover of the conjunctiva through the original incision

This is by far the best type of conjunctival flap made. A path through it remains open for its own nutrition and for that of the cornea. It covers the whole area of the wound and it needs no sutures to fix it in position.

I have seen Czermack's operation done by a most dexterous surgeon, now, I am sorry to say, no longer in active practice. He did no iridectomy. But prolapse was not absent—it was of frequent occurrence. The sclero-corneal wound was actually propped open by the pressure within the eye, the aqueous escaping under the conjunctiva but being retained there. And the prolapse was merely concealed beneath the conjunctiva—the most dangerous situation in which it can occur.

If a Czermack's flap signally failed to prevent prolapse of iris, how can we expect that usually made to do so even if sutured? The truth of the matter is that the conjunctiva is far too elastic to be of the slightest help in fixing the cornea in place. If we wish to do this we must take our courage in both hands and put our sutures in the cornea. To put them in the conjunctiva is to rely on a broken reed. This matter is more fully discussed in the section on the treatment of the iris.

In the capsulotomy operation a conjunctival flap does possess one advantage. If tags of capsule get caught up in the wound, it seals them over quickly and prevents them from acting as a drain communicating with the conjunctival sac.

I have seen such tags keep a purely corneal wound open almost as much as would a piece of gauze inserted

as a drain It is this in my opinion which is responsible for the myth that corneal wounds do not heal kindly In my experience with intracapsular extraction they heal more quickly, more soundly, and with less residual astigmatism than do sclero corneal sections with a large conjunctival flap

In intracapsular extraction then a conjunctival flap is to be avoided It serves no useful purpose and can be a real nuisance if such delicate operative procedures have to be undertaken as the removal of a burst capsule

On the other hand an incision ending forward in the cornea is objectionable from an optical point of view, more especially if there is any tendency towards drawing up of the pupil in the end result The happy mean is therefore an incision ending either in the sclero cornea or in the cornea just clear of the sclero-cornea according to the circumstances

III The Size of the Incision

The surgeon who extracts cataract in the capsule soon finds that matters are simplified by a big incision while a small one makes it impossible I will first discuss the upper limits of safety to the size of the incision

The surgeon whom I saw doing Czermack's operation drew out the lens in its capsule with a pair of forceps from beneath the conjunctival flap To be able to do so he had to have his incision extending round two thirds of the cornea (*i e*, 240° or forty minutes of the clock) This greatly overstepped the limits of safety and there was more or less starvation corneal opacity in the

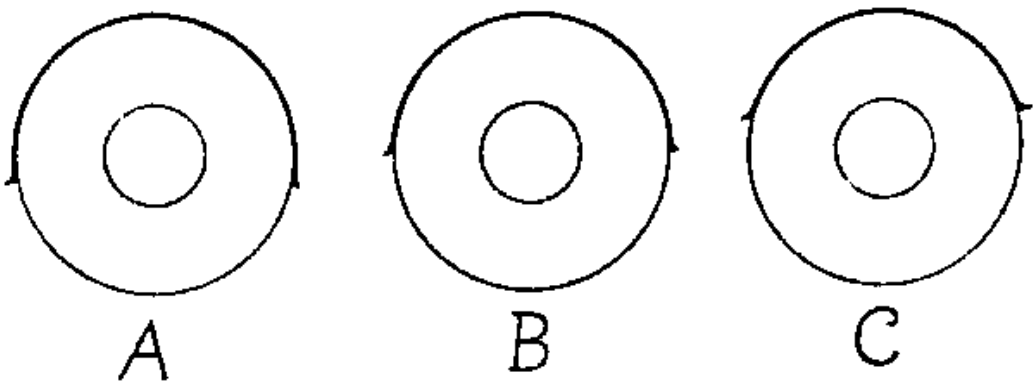

Fig 27

Sizes of Incision

A—Upper limit of safety for nutrition of the cornea —Three fifths of the corneal circumference or 214°

B—Minimum for intracapsular extraction when no intraocular instrument is used —One half of the corneal circumference or 180°

C—Correct for capsulotomy operation in senile cataract —Two fifths of the corneal circumference or 144 °

majority of his cases.

I have seen another man with a considerable clinic who aimed at an incision about thirty-four minutes of the clock or 204°. His cases did not suffer from corneal starvation, which demonstrated to me that we can go to this limit with perfect safety. I do not myself advocate an incision of this magnitude for it is not necessary. But I advance the clinical fact in order to persuade the surgeon who is attempting intracapsular extraction that he need have no fear in making his incision large enough from the very start. He may curtail it with experience but if he starts with it too small, he will court disaster and will give in before he reaches the length of enlarging it.

The Lower Limits.—In expressing the lens in its capsule the lower limit of safety is in my experience 180°, or thirty minutes of the clock. Men of large experience would be able to coax many ordinary hard cataracts through a slightly smaller wound. But even they would have too many disasters in the form of burst capsules. I myself would never intentionally make the incision under 180°, nor would I recommend anyone else to do so. If the beginner aims at 190° (thirty-two minutes of the clock), he will be on sure ground. Even if he errs a few degrees in excess of his aim, there will be no danger of corneal starvation. And if the error is a few degrees in defect, he will not be cramped for room in which to deliver the lens. But if his aim is 180° and he errs in defect, he will have trouble. (Fig. 27.)

In *Extraction* by means of an instrument introduced into the eye, which maintains its grip upon the capsule until the lens is out, these lower limits of safety must necessarily be raised. For the lens and the instrument will require more room to emerge together than the lens alone. Professor Barraquer lays down (*vide* Fisher's Senile Cataract, 1923 Edition, page 49) that an incision of two-fifths of the sclero-cornea (twenty-four minutes of the clock or 144°) is sufficient for the extraction of the lens by his method. If Barraquer himself can succeed with a routine incision of this size, I myself certainly could not. I have little doubt that the many, who have tried Professor Barraquer's method and have given it up, have failed very largely because they followed too faithfully his explicit instructions for an incision of 144°. Had they made their incision 190°, there would have been more of them doing his operation to-day.

If intra-ocular instruments are used to dislocate the lens then Knapp's method is in my opinion a long way the soundest. For after dislocating the lens below he lets go the capsule and withdraws his forceps. He then expresses the lens as a " tumbler " (*vide infra*) solely by pressure with a squint hook from without. In this way he avoids having to make his incision large enough to accommodate both lens and instrument at the same time and also avoids escape of vitreous to a large extent.

In *Daviel's Operation*, the standard incision recommended by the text-books is 1/3 of the circumference of the cornea, with the postulate that as the surgeon gains experience, he will be able to judge the size of the nuc-

leus and adopt his incision to it. In my opinion this cannot be done with any accuracy. There would be fewer disappointments if the capsulotomy operator made his standard incision in the case of senile cataract, 2/5 of the corneal circumference and did not hesitate to enlarge it with scissors in case he meets with such an emergency as a hyperamature lens being dislocated with the capsulotome. If an incision has to be enlarged, the pressure of the orbicularis must be taken off the eye in order to let the vitreous and iris fall back out of the way of the point of the scissors which causes pain if the iris is touched and makes the patient misbehave.

For this reason I am not sure that it would not be best in the capsulotomy operation in senile cataract to go the whole hog and make the incision a full half circumference (180°) from the start. The surgeon would then be prepared for all emergencies.

In the capsulotomy operation on juvenile cataract there is no necessity for these big incisions as there is either no nucleus or at most a small one.

THE IRIDECTOMY.

Why Should an Iridectomy be Done at all?

It is clear that we shall not have perfected the operation for cataract until we can do without an iridectomy as well as extract the lens in its capsule.

In intracapsular extraction the sole purpose for which it is done is to prevent prolapse of iris. It is in no way necessary for the delivery of the lens. If steady pressure is maintained the sphincter iridis gets tired and

relaxes just as do the muscles of the arm when a weight is supported in the outstretched hand. And when the lens has passed through the pupil it contracts behind it immediately. In fact the iris suffers much less damage during delivery of the lens if the pupil is intact than if a complete iridectomy has been done. In the latter case the emerging lens is liable to split the iris up to the ciliary region and to strip the pillars of the coloboma—we know how loosely the iris is attached at its root. But this does not happen if the sphincter iridis is intact. This stripping of the pillars of the coloboma is one of the causes of the drawn up pupil (Fig. 28, A, B, C) which is somewhat more prone to follow intracapsular extraction with an iridectomy than the capsulotomy operation. Tags of iris are left free to get incarcerated in the angles of the wound. The absence of the posterior lens capsule is of course a potent factor in this respect, as in the matter of the greater liability to iris prolapse, for it allows the iris to be pushed forward by the vitreous into contact with the wound, to which it may become adherent before tension is re-established.

Many years ago I was struck by the perfect cosmetic result which is always obtained if we shut the eye up and leave well alone when the patient has squeezed out the lens and some vitreous on completion of the incision, for prolapse of iris seldom seems to follow. I tried a large number of cases without an iridectomy to see what would happen, taking no auxiliary measures to prevent prolapse. This when it did occur always took place in the middle of the wound, not at the angles as it does after a

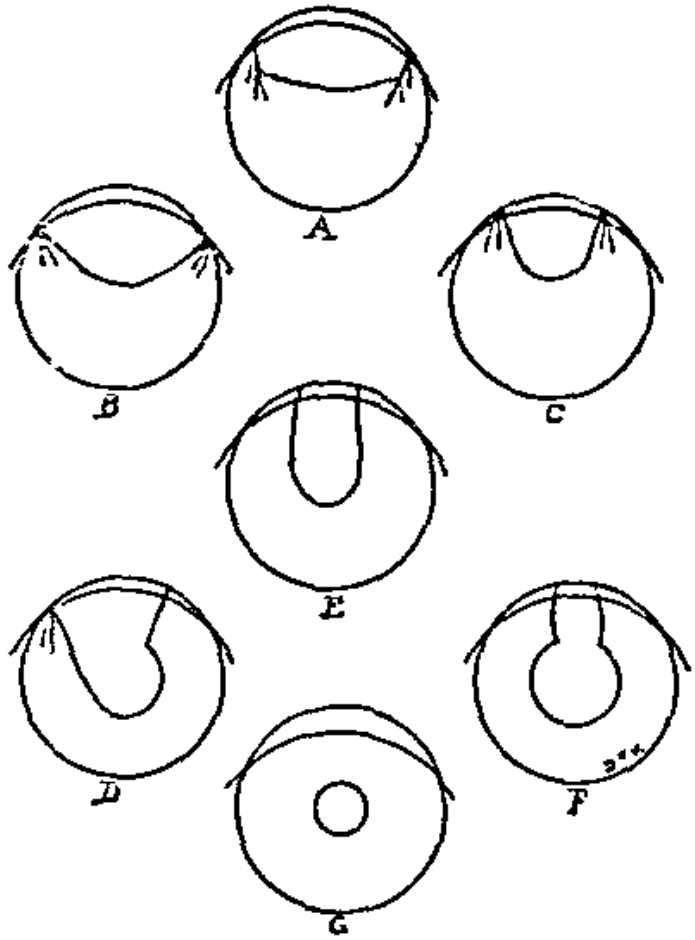

Fig 28

Showing different results as regards the shape and position of the pupil left after extraction, whether in the capsule or by the capsulotomy method. A —Vitreous has escaped. The angles of the coloboma are incarcerated in the wound or folded in such a way as to produce an unsightly drawn-up pupil By trimming off the vitreous while the upper lids held on the lid hook by the assistant and using the iris spatula properly as if nothing had happened, the curled angles of the coloboma could have been unfolded and the pupil left in good position B.—Shows a faulty result due to neglect of the operator to complete his operation by proper dis entanglement of the iris incancerations at the ends of the incision by means of the iris spatula. C —Shows still another faulty position of the pupil due of the same cause as B D —Showing one arm of the cut iris properly replaced, but the other still hung in the wound E —Shows the effect of proper use of the iris spatula. F.—Shows a nice pupil properly replaced where a small iridectomy has been done. G.—Shows a round central pupil in a case of simple extraction. When prolapse of iris has been escaped.

central iridectomy. It was lessened in amount by ending the incision forward in the cornea 2 mm. from the limbus (Fig. 28, G), but even then it was so frequent as to be prohibitive. So despite the excellent result in the successful cases I came to do a routine iridectomy, for it was clear that some adjuvant measure would be necessary before we could dispense with it with safety.

Since that time I have tried all manner of devices to avoid prolapse with an intact iris or failing that with some form of iridectomy, which would give a central or nearly central pupil.

In my opinion the cause of prolapse lies in the patient squeezing and bursting the wound open after the anterior chamber has been reformed. The iris if not already adherent to the wound is then swept into it with the gush of escaping aqueous, stays there and is ballooned out by pressure from behind. There is a theory that this only happens if the iris has been paralysed by bruising it against the sclerotic and wedging it into the angles of the wound during the delivery of the lens. The absurdity of this theory will be evident when we see an optical iridectomy for a leucoma done in the manner described in Chapter V. For in it the healthy untouched iris is swept into a small wound by a gush of aqueous as the knife emerges, and there has been no question of bruising or stretching.

Logically, the obvious line of attack would be to deal with the cause at its source by paralysing the orbicularis for eight or ten days, until the wound in the eye was soundly healed. (I have frequently seen prolapse

occur after the sixth day.) But I know of no way in which this can be done safely. Novocain injected into the orbicularis in my experience produces anæsthesia only, not paralysis, with any degree of regularity (*q. v.*), and anyhow its effect is transient. Quinine urea-hydrochloride and all the other drugs I have tried are effective, but only if one has the luck to strike the actual trunk of the facial nerve with the hypodermic needle. The more irritant they are the longer the duration of the paralysis. Even if it were possible to do this with unfailing regularity, and one had a drug at one's command which would produce a sufficiently lasting paralysis, the disadvantages would be very great. The whole side of the face would be affected, the buccinator as well as the orbicularis muscle, which would be very distressing and would greatly complicate the nursing. And no drug would act with such absolute uniformity as to remove all element of danger. There would be grave risk of the effect lasting inconveniently long in a proportion of the cases.

If paralysis of the orbicularis for the necessary length of time is ever accomplished, it will have to be by means of a drug which acts on the motor nerve endings when injected into the muscle. There is one drug which will do this—curare—but I have never dared to experiment with such a lethal weapon. But I have tried one method which at first sight seemed to be very promising—picking up the whole thickness of the eyebrow on a stitch which was then passed through a piece of adhesive plaster stuck on the forehead above the frontalis muscle and tied so as to keep the brow lifted. In this

way the upper part of the orbicularis was put out of action mechanically (*vide* Fig. 11). The lids were drawn apart very slightly and I added a stitch through their margins to keep them together. Now hopeful though this looked in theory it turned out to be of no assistance in preventing prolapse of an intact iris, but rather the reverse. I had not done a dozen cases before this became evident to me. On thinking it over I saw the reason—the stitch had pulled the upper fibres of the palpebral orbicularis off the eye and removed the support which they normally give to the wound lying under them in the upper conjunctival fornix. At the same time the lower part of the orbicularis was free to act and produce pressure.

This experiment led me to wonder whether a local paralysis of the orbicularis is really such a desirable thing. For it would remove the support normally given to the cornea by the tonic action of the muscle. This must delay a considerable part in face of the pressure of the aqueous inside the eye which tends to force it open. No dressings and bandages could adequately replace nature's splints in this respect. It is a moot point whether an effective and lasting local paralysis of the orbicularis would not do more harm than good. The ideal at which to aim would be a central paralysis having its seat in the cerebral cortex which would cut out the violent spasmodic squeeze but leave the steady pressure of the tonically acting muscles and the blinking reflex. The only way in which we can attempt to reach this ideal is by using sedative drugs of which, as I have said

before, bromide of potassium in adequate dosage is the best.

It remains to consider the various local measures in the eye itself which hold out some promise of preventing prolapse of an intact iris. The first of these is suturing the wound in hopes that the patient will not be able to burst it open. As I have already explained with reference to Czermack's operation suture of a conjunctival flap is worse than useless. I have tried through-and-through stitches in the cornea. Any qualms I had as to their behaviour were soon dispelled, for they gave no more trouble than do through-and-through stitches in the abdominal wall, but as a means of preventing prolapse of iris, I found them impracticable. With an incision of 180° it was clear that one suture would be useless. I started off with two, at 11 o'clock, and 1 o'clock respectively. They had, of course, to be inserted before the lens was expressed, and it proved to be a very tedious process, liable to take the nerve out of the patient and to make him go to pieces on the operating table to a most objectionable degree. To use more than two stitches was clearly impracticable, but two only were not sufficient to achieve their object—the iris was liable to prolapse between them or to adhere to the wound —a sclero-corneal incision having been used. I therefore came to the conclusion that corneal suture is not a practical line of attack.

Another device which I have tried is, ending the incision well forward in the cornea, to have the iris heavily under the influence of atropine—a 4 per cent.

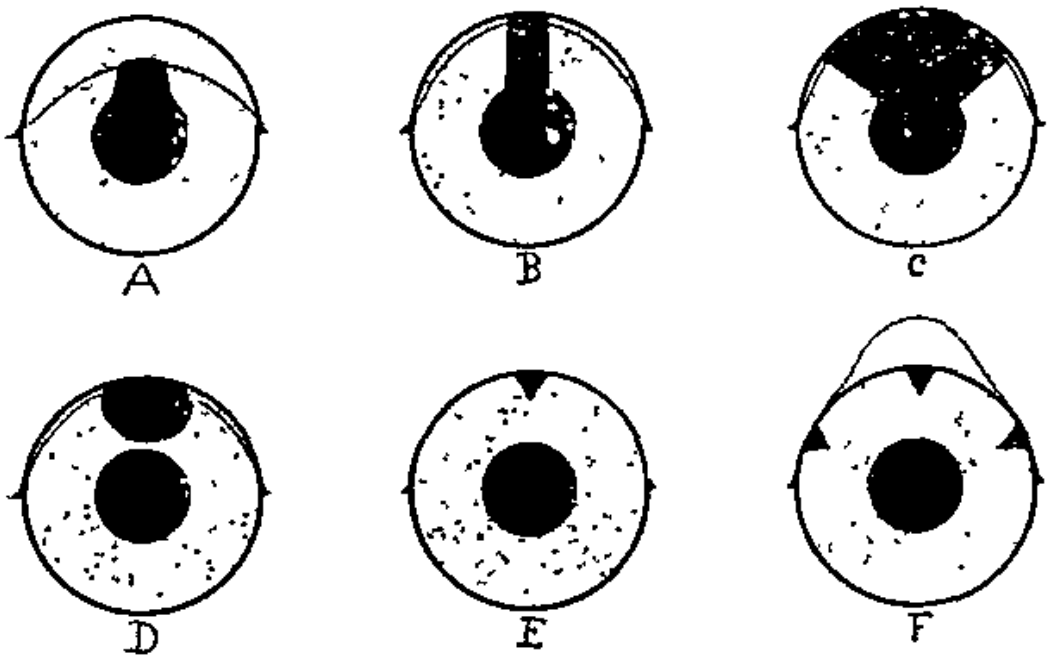

Fig 29

Iridectomies.

A—Marginal.—If small, nip off the pupillary margin of the sphincter which just clears the middle of a forward corneal section

B—Complete—Correct Size.
C—Complete—Unnecessarily large
D—Attempt at Hess Peripheral, but the section has been too far forward and the buttonhole has been made much too big. The intact strand of *sphincter will tear across during delivery of the* lens even if the latter elects to emerge through the pupil and does not give trouble by trying to find its way out through the buttonhole.

} The section has been made in the cornea just clear of the sclero cornea.

E—Hess peripheral Correct size. Section sclero-cornea

F—Three peripheral buttonholes. Section sclero corneal with conjunctival flap

ointment being used for two days previously to operation and for the first few days after operation. This kept *the edge of the iris clear of the centre of the incision,* fulfilling the object of an iridectomy and allowing a space for aqueous to escape if the wound should burst open. The immediate results were very promising when the atropine had been used heavily enough to be efficient in its action. But on following these cases up there was in the end a tendency for the iris to become adherent *to the wound and the pupil to draw up behind the scar.* The situation was similar when the forward incision was combined with an iridectomy so small as just to clear the centre of the wound and to remove only a portion of the sphincter iridis. (Marginal Iridectomy, Fig. 29, A.) In replacing the iris after expressing the lens it could be seen still to remain a continuous sheet intact above: the remains of the sphincter had prevented it splitting or stripping at the periphery. The immediate results again were good, with less tendency to boat-shaped and badly drawn up pupils than in the ordinary complete iridectomy with a sclero-corneal incision, but in the end result the corneal incision again proved an optical disadvantage.

A sclero-corneal incision should therefore be used and in intracapsular extraction some form of iridectomy is essential. (Complete Iridectomy, Fig. 29, B, C.)

In an attempt to avoid the stripping of the root of *the iris which is liable to occur during delivery of the* lens through the coloboma of a complete iridectomy, I tried the effect of postponing the performance of the

latter till after delivery had been accomplished. But though the results looked promising in the successful cases, I had to give it up—one is fishing for the iris rather in the dark, with the eye in an unstable condition and is very liable to provoke loss of vitreous. In doing the iridectomy in the usual way and a very good one is to insert the forceps closed into the eye, open them and pick the iris up. But there is an alternative method which is prettier and more spectacular. One limb of the forceps is dropped into the wound and held still against the scleral lip. The handle of the forceps being dropped towards the patient's feet in order to provide sufficient pressure, the other limb is stroked over the cornea as it is closed, and the iris jumps out into the grasp of the instrument. (Fig. 30.)

For success in this method there must be no conjunctival flap, and the point of the forceps must be blunt or it will scratch the cornea. The surgeon must be able to hold the one limb of the forceps still while he moves the other or he will only succeed in gripping the edge of the cornea between them.

When caught, the iris must be held very lightly—if it is squeezed the patient is liable to wince. In cutting it off, as small a piece as possible should be taken—the common mistake of the beginner is to pull it right out of the eye and to take away much more than is necessary. Both hands should be rested on the patient's head to steady them, the brow being retracted at the same time with the ring and little fingers of the left hand. (Fig. 31.)

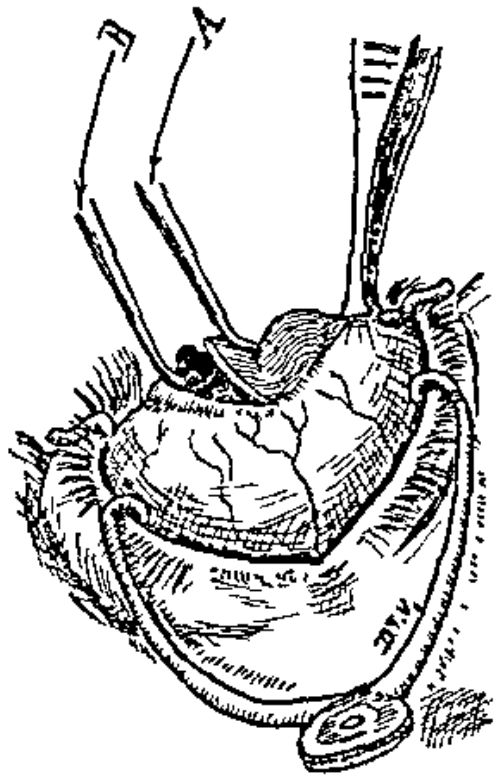

Fig 30

Showing the Method of Grasping the Iris: The end of one arm of the forceps is entered in the wound against the *scleral* side of the cut, while the end of the other arm of the forceps is made to glide over the cornea from the centre upwards, at the same time depressing the cornea to force the iris up in the wound where it is seized and cut off. The assistant steadies the eye with fixative forceps below. The depression of the cornea is exaggerated in this sketch

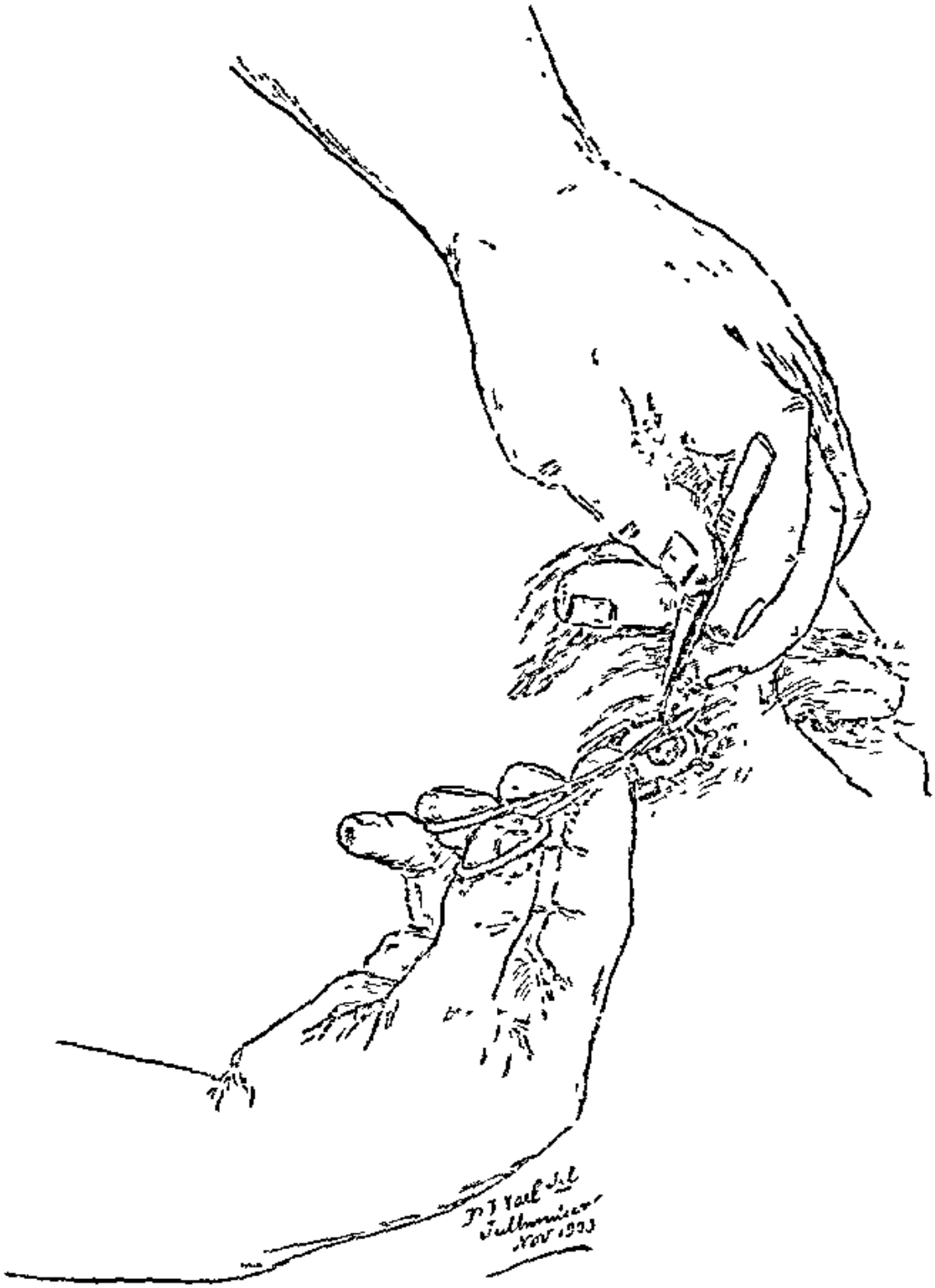

Fig 31

Showing How the Iridectomy is Done After Iris is Grasped: Note that the little and ring fingers of the left hand are in perfect control of the eyebrow, also that the right hand has perfect command of the scissors causing them to cut clean and sure The tip of the thumb and the tip of the ring finger of the right hand are inserted in the rings of the scissors.

Hess Iridectomy.

When prolapse of the intact iris occurs its *base* is always ballooned into the wound by pressure of the aqueous *from behind.* In a Hess iridectomy a small button hole is removed from the base or periphery of the iris, behind the wound (Fig. 29, E, F.) This gives free communication here between anterior and posterior chambers, and allows free exit for the aqueous in the posterior chamber which rushes for the wound when it is burst open. This is the rationale of the proceeding, which apart from the preservation of a round pupil, is unquestionably more satisfactory than a complete iridectomy, for there are no pillars of a coloboma free to flap into the angles of the wound. I was however unable to adopt it in the days when I was expressing lenses upper edge foremost *(q.v.)*; for if the buttonhole is made *before* the lens puts its nose into it during delivery—it is difficult to manage, while to make it *after* the lens is out—is quite impracticable. But since working out the method described subsequently for delivering all lenses as " tumblers " (*q.v.*), *i.e.*, lower edge foremost, I have been able to adopt it. A single buttonhole at the middle of the wound gives quite good results (Fig. 34, G), but there is still some tendency for prolapse or incarceration to occur at the angles. This can be overcome by making another peripheral iridectomy at each angle (Fig. 16, 34, H), *i.e.*, three buttonholes in all at 10 o'clock, 12 o'clock and 2 o'clock. In the after treatment an eserine ointment should be used to stretch open the holes and to keep the iris sheet taut so

as to lessen its liability to adhere to the wound The ordinary complete iridectomy should be reserved for those cases in which the presence of some complication, an old iritis, diabetes, or the like, renders the prophylactic use of atropine advisable If this drug has to be used at all, it must be used in no half hearted manner and a peripheral iridectomy is liable not to function efficiently, while for the separation of old iris adhesions a complete iridectomy is necessary in order to get an instrument behind the iris

De Weckers scissors are essential for making a peripheral iridectomy and care should be taken that the Hess forceps used are sharp in the point (Fig 32) The difficulty lies in keeping the buttonhole small and with blunt pointed forceps it is impossible to avoid picking up a large piece of iris For the same reason it should be seen that the teeth are sharp and in perfect order (to have them made of rustless steel is a great advantage) In making the iridectomy the surgeon should retract the eye brow with the fourth and fifth fingers of the hand holding the forceps (*cf* Fig 31), thus obtaining support for the hand at the same time The forceps should be inserted closed till they are held up by the bend coming in contact with the sclerotic opened slightly and closed again to pick up the iris

This should be cut off blindly inside the eye (Fig 33) by sliding the scissors down over the point of the forceps which are then removed and inspected to see if there is a piece of the iris on the teeth If the iris is pulled out of the eye, the buttonhole will be much larger

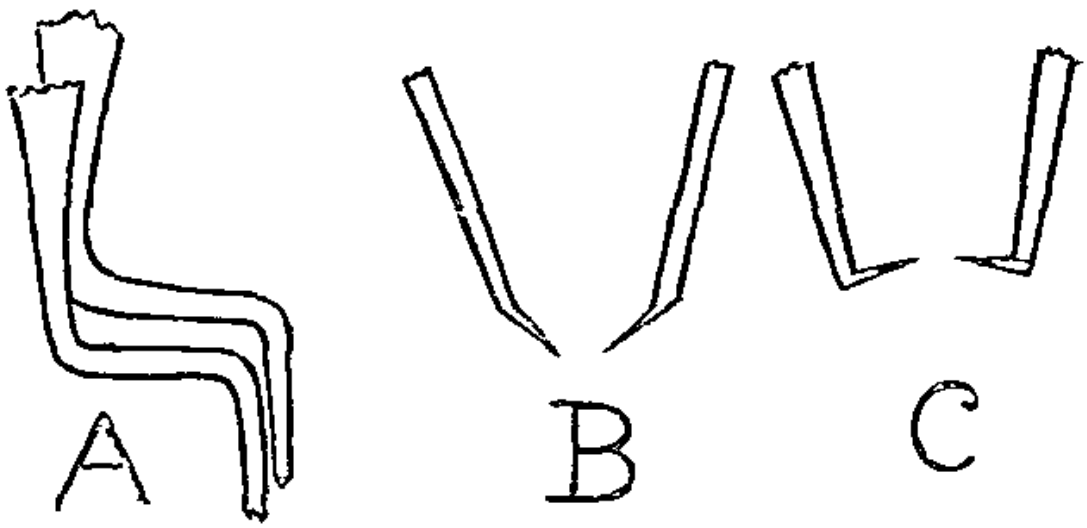

Fig 32

Hess Peripheral Iridectomy Forceps

A—Side view
B & C—Front view of teeth
B Correct—sharp in point
C Incorrect—blunt in point

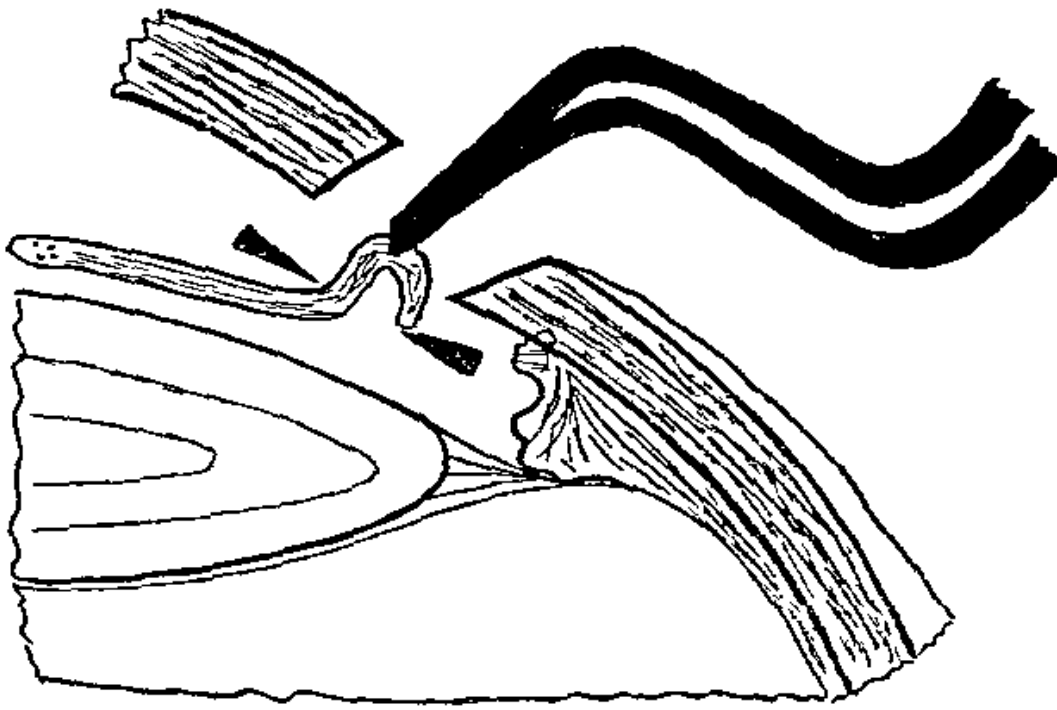

Fig 33

To shew how in making a perpheral iridictomy the de Weckers scissors should be slipped over the point of the forceps and the iris cut off without actually drawing it out of the eye

than necessary. When making more than one buttonhole it is therefore an advantage to use a fresh pair of forceps for each one as it is a nuisance to have to clean the fragment of iris off the points before proceeding.

In performing these iridectomies, it is a great advantage to have an assistant steading the eye with fixation forceps, *but he must be properly trained* to put no pressure on the eye and to let go the instant the iris has been cut.

The Dislocation and Removal of the Lens in its Capsule.

The methods in use for this purpose fall into two groups, that in which pressure from without alone is relied on—the standard method in India—and that in *which intra-ocular instrumentation with capsule forceps* mechanical or pneumatic or a zonulatome is called to our aid. The methods of extraction with capsule forceps, of which the late Professor Stanceleau of Bucharest was the first exponent on any large scale, were introduced primarily in order to get away from the loss of vitreous which was liable to occur in unskilled hands with the Indian method as used at the time. But there arose around these extraction methods, an idea that they possessed an inherent advantage over the Indian method in that, the lens being dislocated by pulling, less damage is inflicted on the intra-ocular structures than when pressure from without is employed for the purpose. The way in which this and other prejudices against intra-capsular extraction current in Europe and America have

been exploited by Barraquer of Barcelona in his introduction of the "Erisiphæ" or pneumatic forceps to the profession, makes it necessary to point out here the complete fallacy underlying this idea. ("Phacœrisis" raises such important issues from which a valuable lesson is to be learned in the correct use of capsule forceps of any kind, that I am devoting a special chapter to its consideration in detail.) If we hark back to our geometry for a moment, we will remember the proposition which states that a given surface encloses the greatest volume when it is in the form of a sphere. Let us regard the sclerotic, the moorings of the lens-capsule to it, and the capsule itself as the walls of a sphere which contains an incompressible fluid, the vitreous. If we deform these walls the volume which they can contain will be diminished. No matter whether we do it by pulling or by pushing on them, we will be constraining the vitreous to occupy a smaller space. (*See* Fig. 34.) Its refusal to do so will compress the structures lying between it and the walls which contain it, and will put the latter on the stretch. If we go on deforming them, the strain on them will increase until they burst at their weakest point.

The compression to which choroid, retina and vitreous must be subjected, in order to dislocate the lens in any particular eye, is determined by the tensile strength of the particular zonule, multiplied by the length of it which is ruptured in the first instance. The last factor is the only one which is within the power of the surgeon to vary. This compression is therefore least

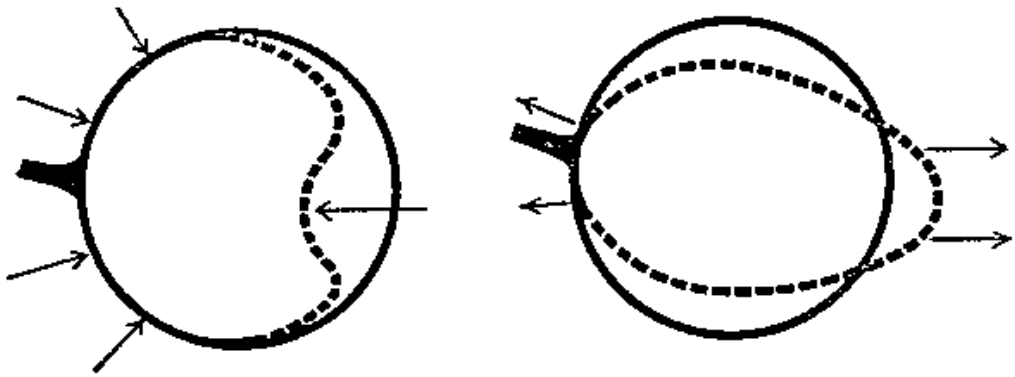

Fig 31

A given surface encloses the greatest volume when it is in the form of a sphere No matter whether the lens is dislocated by pressure from without the eye, applied either to it through the cornea or to the sclerotic, or by direct internal manipulation with forceps, the violence done to the eye is exactly the same, even though in this latter case, the manipulation takes the form of pulling rather than pushing For the walls of the sphere which contains the vetreous are deformed, the volume which they can contain is reduced, and the vitreous and all the structures which lie between it and the sclerotic are subjected to compression.

in the method which most nearly concentrates the strain on the zonule on a point—whether it involves pressure on the sclerotic, pressure on the zonule, pressure or traction on the lens capsule, is quite immaterial. The ideal would be achieved if we could use a sharp cutting instrument, but I need not discuss the use of such a weapon inside the eye. A blunt instrument applied directly to the zonule is the method next closest to the ideal, and has taken shape in the so-called zonulatomes to which different men have given their names. But it possesses certain theoretical dangers which are to my mind insurmountable. For at the worst it would be very easy when one is working with such an instrument in the dark behind the iris, to push it down the natural plane of cleavage which passes through the ciliary body. At best, it would be difficult to be sure that one had not bruised the latter against the sclerotic with the hard metal instrument itself. When these two plans are dismissed, there is absolutely nothing to choose between an instrument which dislocates the lens by pressure on the eye from without and one of the various types of capsule forceps used to do the same thing by direct internal manipulation. And whether the latter takes the form of pulling on the lens or pushing, it is quite immaterial. The violence done to any particular eye would be exactly the same assuming they were done with equal skill.

After this preliminary discussion of principles, the various methods of removing the lens in its capsule must be described in detail—the Indian method of expression from without, taking pride of place in point of time and

on account of the extensive scale on which it is performed: I wish again to emphasize the importance of having the lids and orbicularis under perfect control during removal of the lens, in charge of a competent assistant (as described previously, *vide* pages 65-70 and Figs. 6 to 11.) *The surgeon who keeps the speculum in during removal of the lens and relies on Novocain to paralyse the orbicularis is heading for disaster.*

THE INDIAN METHOD: EXPRESSION FROM WITHOUT.

I shall describe here the methods which I have used to express the cataractous lens in its capsule by pressure applied to the outside of the globe in the order in which I worked them out.

My latest method will unquestionably put my original one into disuse, as well as all the methods involving the use of an instrument within the eye with which to catch hold of the lens and extract it. But as my new method was developed from my older ones in order to remedy their defects, they merit description if only to explain what these defects were, and as a matter of historical interest.

The surgeon must realise that senile cataracts all fall into one or two groups from an operative standpoint, *i.e.*, hard and soft (or Morgagnian), the dividing line between which is arbitrary. The former type (which includes the type I have described as Hypermature *ab initio*) has a tough capsule and moulds but slowly for it has a large nucleus embedded in a viscous cortex. The latter group is much larger, moulds much more readily, for it has a small nucleus embedded in a fluid cortex,

but has a thin and easily ruptured capsule. In both types the firmness with which the suspensory ligament is attached to the capsule decreases steadily *pari-passu* with increase in the age of the patient, bearing roughly an inverse proportion to it. But this attachment is relatively weaker in the soft than in the hard type. These distinctions are of great importance in relation to the mechanical principles involved in the removal of the lens.

It is commonly supposed that in the expression of the lens in its capsule we simply put pressure on the eye till something happens, without knowing what we are doing, and that it is a matter of pure chance if the lens be delivered alone, or if vitreous comes along with it. This is not the case. We put on our pressure in a very difinite manner with certain definite objects, the same objects as those at which the surgeon must aim who practises any of the extraction methods. He will no more succeed with attempts to pluck the lens by main force out of the eye than will we by aimless pressure.

The lens is as it were slung in the suspensory ligament. Its attachment to this must first be torn so that it can be dislocated from the patellar fossa of the vitreous. Only then can it be removed from the eye. To effect dislocation, with as little compression of the vitreous, choroid and retina as possible, the lens must be made to swing round on some transverse axis so that the strain on the suspensory ligament is concentrated at one or two points. These points will vary according to the position of the axis and the direction of rotation. The suspensory ligament will tear off the lens at the

point of maximum strain first, and will strip round its circumference on both sides susbequently. Then and not till then is it ready for delivery.

(A) Upright Delivery of the Lens *(Upper Edge Foremost)*.

This was the first method which I used. It is applicable to hard cataracts only, as with it the soft cataracts burst their capsule. The transverse axis about which the lens is made to swing is its horizontal diameter. This, it is clear, puts least strain on the transverse fibres of the suspensory ligament, most strain upon them above and below, at which points they first part from the lens. I assume that an upper incision has been made. The pressure is applied through the cornea to the lower third of the anterior surface of the lens, making its lower edge move back and its upper edge come forward to present at the wound. When dislocation has occurred the direction of the pressure is altered in relation to the eye, being kept always at right angles to the surface of the lens, and following it up as it swings round and emerges. In describing how to apply this pressure I assume that the surgeon is right-handed and stands above the patient's head, the assistant controlling the lids on his left. He should hold the spatula ready for use in his left hand. He should grasp the lens hook with his right hand like a pen but a good distance from the point so that its handle does not rest over his knuckle. If it does this, it interferes with his capacity for rolling the instrument between his thumb and fingers which is essential if he is to be able to alter the direction and the

degree of his pressure with the necessary sensitiveness. As in making the incision his hands and instruments should be steadied as much as possible by resting them upon the patient's head. In the case of the right eye the little finger of the surgeon's right hand should rest against the patient's temple, while in that of the left eye the shaft of the lens hook should be laid across the bridge of the patient's nose. Thus steadied, his instruments will be in no danger of plunging and he will have them under the delicate control which is necessary for them to be used with the proper lightness and dexterity.

The lens hook should be placed on the eye upon the flat, the heel below and the point directed upwards, at the junction of the lower and middle thirds of the vertical diameter of the cornea. The point is then twisted backwards by rolling the handle of the instrument between the thumb and fingers. Pressure applied in this way by twisting the hook is under exact control and can be relaxed instantly when necessary. It can be applied with a light grasp of the instrument, a firm grasp of which brings the muscles of the forearm into play and deprives us of the delicate touch to be obtained by using the small muscles of the hand as far as possible unaided.

In many cases the simple backward twist of the point of the hook is sufficient to dislocate the lens. The surgeon will in that case find that there is no resistance to his pressure and should follow up the lower edge of the lens with the point of the hook as it swings away from him, which should be pressed very lightly into the flexure formed in the cornea. As the lens emerges the direction

of the pressure must be altered upwards until finally the corneal flap is folded completely behind it. (Fig. 35.) The hook must not be removed until at least two-thirds of the lens has emerged or it will slip back into the eye.

During the process of delivery after dislocation has occurred, the weight of the instrument alone generally provides ample pressure, being merely guided by the fingers which hold it as lightly as a feather. Once the lens has been delivered it is raked lightly off the wound by running the concavity of the hook behind it.

There is a type of senile hard cataract which though easily dislocated is a tight fit even for an incision of 180°. Its delivery is quite simple if the surgeon has patience and gives it time to mould. In order to drive it forward he must utilise the hydrostatic properties of the vitreous, putting up the tension of this body by applying a little gentle pressure with the heel of the lens-hook, and perhaps even with the toe of the spatula above the scleral lip of the wound. Given time, it will come out quite easily but if hurried, the capsule may burst.

This simple backward twist of the point of the hook is often insufficient to dislocate the lens—whether the suspensory ligament has too firm a hold or because the tension of the vitreous is low and the eye is flaccid. If this is the case, the surgeon must raise the tension of the vitreous by pressure with the heel of the hook keeping its point twisted backwards. The resulting hydrostatic pressure from behind will drive the upper edge of the lens forward causing the suspensory ligament to lose its hold at the wound first.

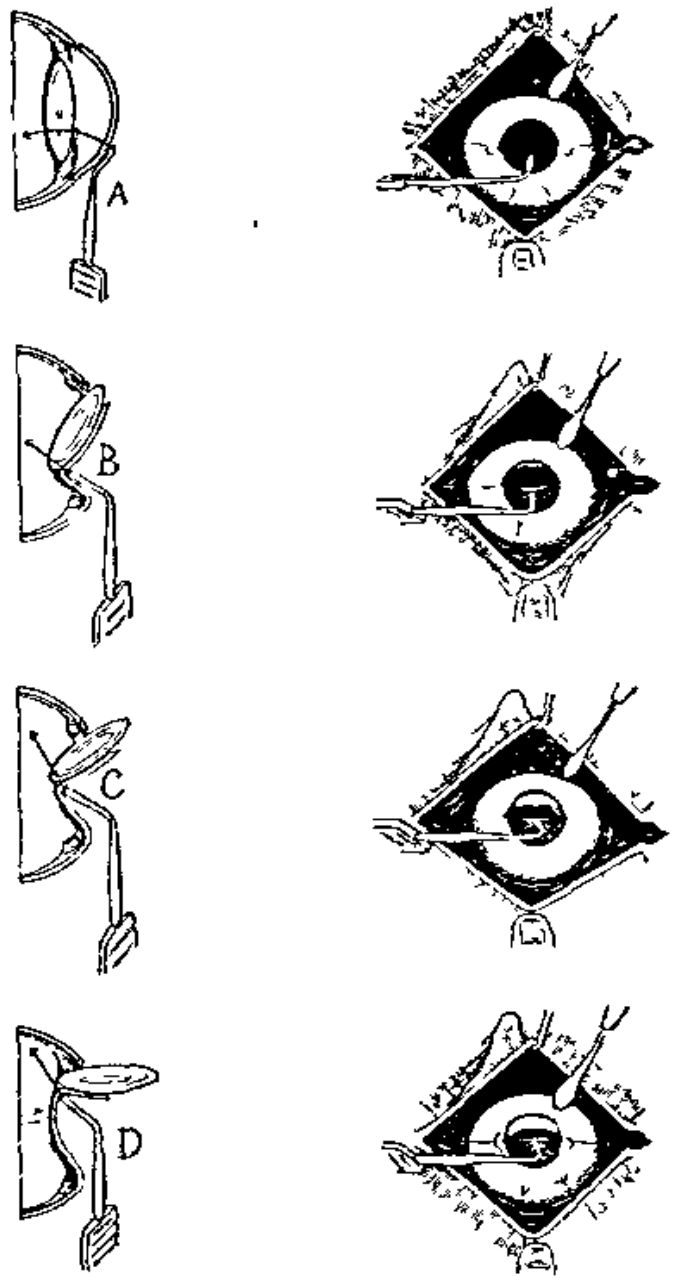

Fig 35

Upright Delivery of an Easily Dislocated Hard Cataract.

A—The lens-hook is laid on the eye, the heel below, over the sclero-cornea, the point above over the lower third of the cornea ready to be twisted into the eye in the direction of the arrow when :—

B—The lens dislocates at once both above and below and slides up the patellar fossa of the vitreous to shew its nose at the wound. The point of the lens-hook is directed up into the flexure of the cornea to follow it.

C—The direction of the pressure is altered more and more upwards as the lens emerges until :—

D—It is ready to drop on to the front of the cornea. The hyaloid membrane is still intact.

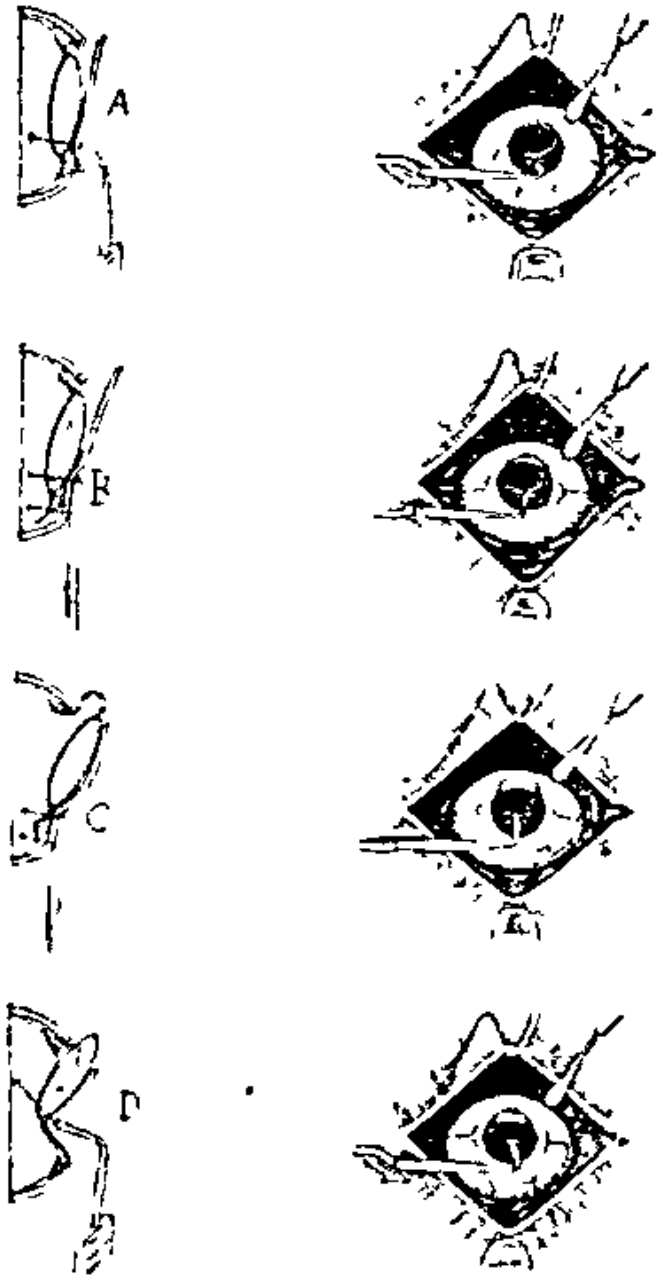

Fig. 36

Upright Delivery of a Less Easily Dislocated Hard Cataract.

A—The lens has not dislocated at the initial twist in of the point of the hook.

B—The heel of the hook is dropped on to the eye and more pressure is exerted in the direction of the optic nerve

C—In unskilled hands the instrument plunges and vitreous is expressed between the sclerotic and the back of the lens when the zonule gives way. This has however occurred below as well as above and the lens will be delivered without serious accident if the pressure is immediately *relaxed and altered upwards.*

D—In skilled hands the pressure is relaxed and altered upwards as soon as the zonule gives way and the lens will be delivered without rupture of the hyaloid membrane

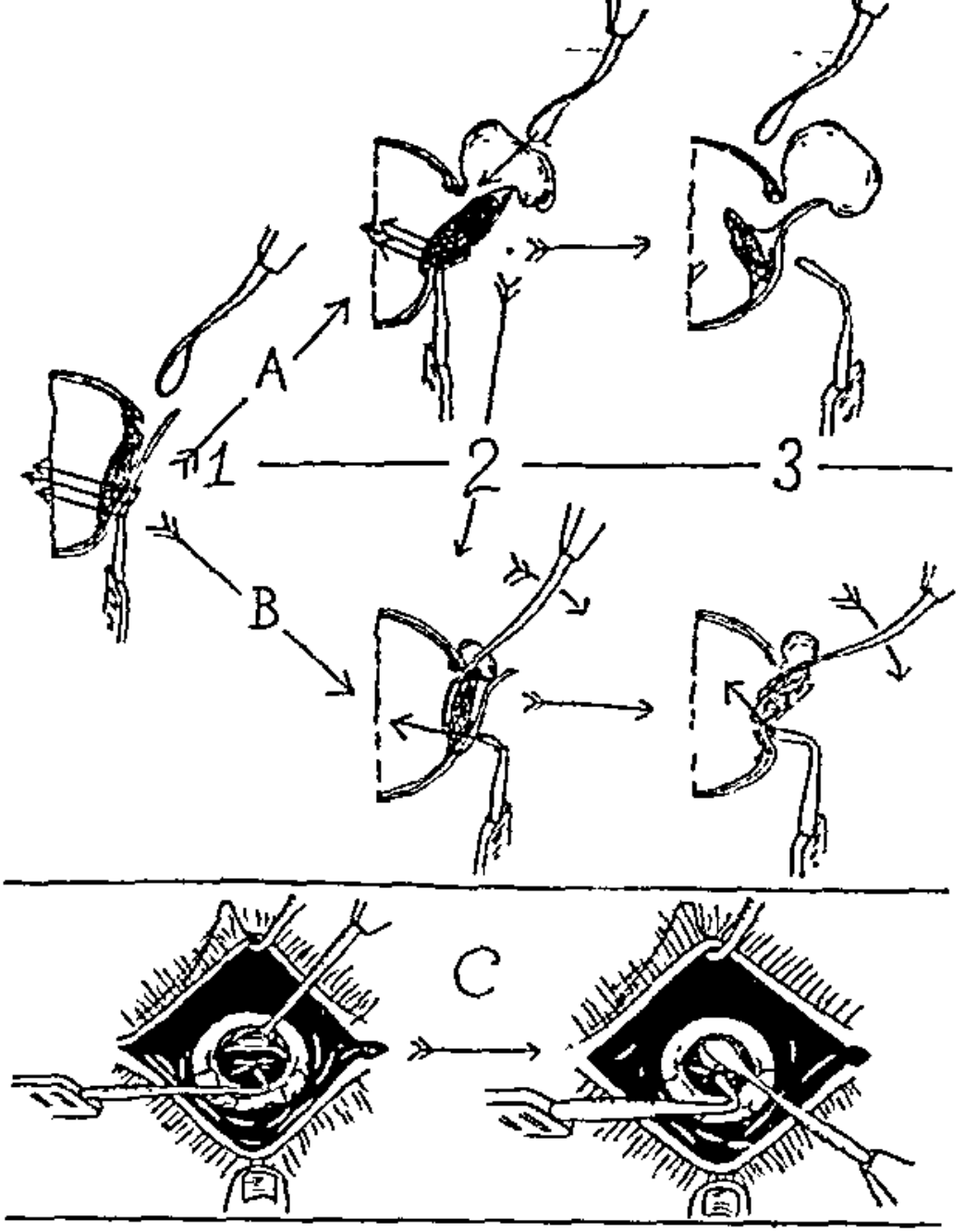

Fig. 37

Use of the Spoon when Vitreous Presents in Upright Delivery.

1 The lens hook is over the cornea, Great pressure is required to dislocate the lens, which is of the discoform type. When the zonule gives way it does so at the wound only and,—

A—2 Unless the operator is very skilful the vitreous comes out with a rush before he gets in his spoon behind the lens to prevent it from —

A—3 falling back into eye

B—2 The operator has got in his spoon behind the lens the moment the vitreous presents and has relaxed his pressure This is directed just past the end of the spoon, the handle of which —

B—3 is dropped as the lens slides up it, the pressure with the lens hook being shifted upwards as the lens emerges and is delivered perhaps without any loss of vitreous if the operator is really skilful

C — Successive stages in the use of the spoon. On the left the head of vitreous into which it has been passed is still visible, on the right it has dropped back into the eye

The moment dislocation occurs, the extra pressure must be taken off by rolling the handle of the hook in the thumb and fingers so as to lift the heel. Only the lightest pressure with the point must be maintained directed as before into the flexure of the cornea to follow up the lens as it emerges. It is in this instantaneous relaxation of the pressure the moment the suspensory ligament gives way that the secret of success lies. (Fig. 36.) If the surgeon is holding the hook lightly, he will actually feel dislocation occurring before he sees that anything has happened. He will then be able to act with promptness. If his grip is firm he will neither be able to feel what is happening nor to prevent his instrument from plunging. He will inevitably squeeze out vitreous along with the lens, unless it is a tight fit for the wound. In the latter case he will run some risk of bursting its capsule, for it will be pressed forward so quickly that it will not have time to mould.

When vitreous presents in this method of upright delivery it does so above the lens between it and the scleral lip of the wound. Its subsequent loss may be avoided in experienced hands by the use of the spatula. (Fig. 37.) With the concavity of the instrument forwards its point is dropped into the presenting bead of vitreous, meeting with no more obstruction than if it were clear water, and is passed well into the eye behind the lens. The instrument is not used from this position to lift the lens forward and dig it out of the eye, for such a proceeding would be certain

to rupture the capsule. Its function is simply to provide a firm inclined plane up which the lens may slide and which will prevent it from sinking backward, and to keep the pressure applied with the lens hook from being transmitted to the vitreous.

When the spatula is in position it must at first be kept perfectly still, while light pressure is made with the point of the hook, directed *just past* the lower border of the lens. So directed, there will be no risk of the lens being squeezed between the spatula and the hook, and of its capsule being ruptured, but it will at once slide upwards up the inclined plane formed by the spatula. When it does so only sufficient pressure must be maintained with the point of the hook to keep the lens in position, while the handle of the spatula is shifted towards the patient's feet so as to rotate the point backwards. In this way the cornea will be folded behind the lens as it escapes.

Using this technique the experienced surgeon will be able to avoid loss of vitreous even in that class of lens whose attachments are so strong and so elastic that it has to be delivered right out of the wound before they are ruptured. If this has to be done he will not wait for the actual rupture but will pass the point of the spatula through the suspensory ligament once the upper edge of the lens is clear of the wound. In this type of case it will be seen that there is a certain mechanical advantage in ending the incision well forward in the cornea, when the method of upright delivery is being adopted. For

the upper edge of the lens has further to travel before it reaches the wound than with a sclero-corneal incision. Hence the suspensory ligament can be stretched further before the lens emerges and there is a better chance of its giving way while the latter is still safely under the shelter of the scleral lip of the wound.

In a small proportion of cases (generally of the disciform type) the zonule is so firmly attached to the lens that considerable pressure is necessary to dislocate it. If an attempt is made at upright delivery the sclero-cornea and sclerotic are so much deformed below, opposite the wound, that there is no strain on the zonule there—it is all concentrated above. Thus, when this structure ruptures above, it retains its hold below and even the most experienced surgeon cannot get his spoon behind the lens before he has expressed some vitreous. With inexperienced hands disaster is in store. A quantity of vitreous will be expressed with a rush and the lens will drop back into the depths of the eye (Fig. 37, A) before the spatula is passed on, and there may be difficulty in retrieving it.

It will be seen then that promptitude and dexterity in the use of the spatula is essential if the surgeon is to attempt upright delivery of hard cataract as a routine. The manœuvre I have described with it is neat and simple to execute once the trick has been acquired. But it is not easy to learn for it demands the lightest of fingers, perfect co-ordination of the two hands and considerable opportunity for practice. It is the most techni-

cal accomplishment of a highly technical art, the acquisition of which puts the final polish on the education of the cataract surgeon while the want of it is the rock upon which most of the men have foundered who have attempted and have given up expression of the cataractous lens in its capsule or have chosen the middle course of "selecting" the difficult cases for capsulotomy, and that after the difficulty has been encountered on the operating table.

(B) Delivery of the Soft (Morgagnian) Lens (*Lower Edge Foremost as a "Tumbler"*).

Very early in my experience I found that the soft cataract can be dislocated even more easily than the hard cataract by pressure applied to make it present at the wound—upper edge foremost. But in its subsequent delivery the capsule bursts far too frequently. This accident is undesirable at any time. If this happens during upright delivery of the lens it is exceedingly inconvenient. For it is at once drawn back into the aqueous chamber by the elasticity of its attachments which are as yet unruptured below.

I then found that with a slight alteration of the direction of my pressure I could make the Morgagnian lens swing forwards on a transverse axis which passes through its upper border. Its lower edge comes forward and the suspensory ligament is put on the stretch below, at which point the rupture first occurs. Once dislocated here the point of the hook can be insinuated behind the lens through the folded cornea and used to expel it

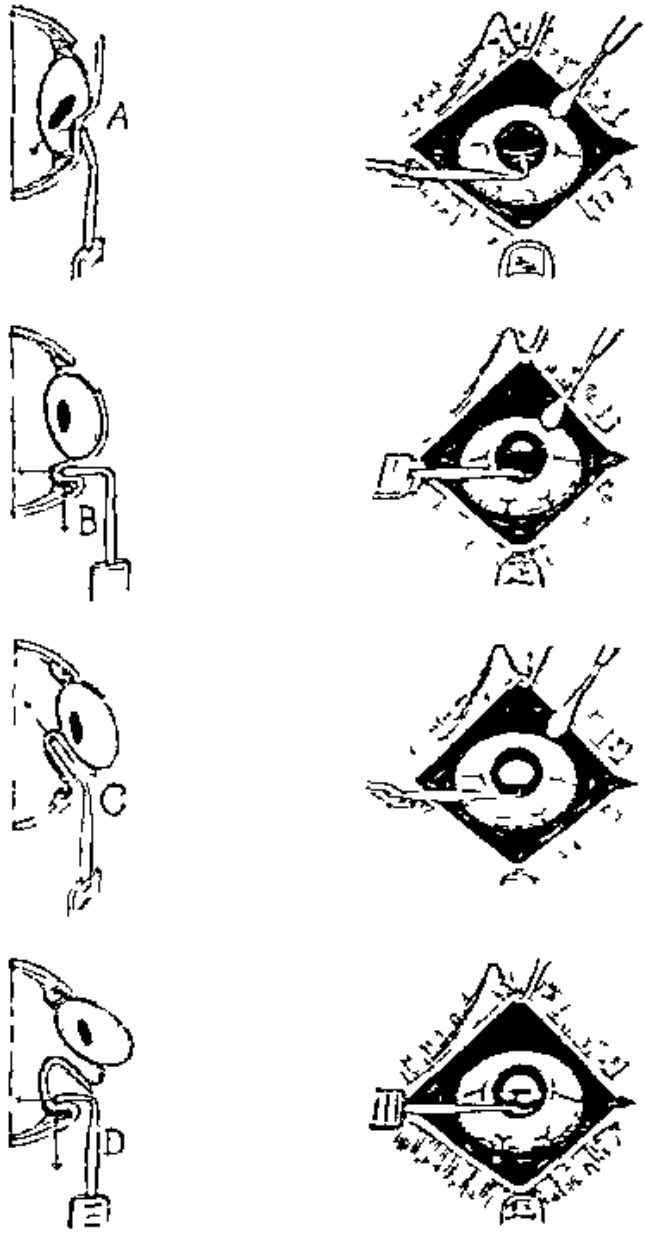

Fig 38

Delivery of the Morgagnian (Soft) Cataract as a "Tumbler," i.e., Lower Edge Foremost.

A—The hook is layed on the eye as before and the point twisted back into the cornea.

B—The twist is continued downards *until the resistance of the more rigid* sclero-corneal ring is felt. Keeping the point of the hook pressed backwards to maintain the grip, the ring is pulled down towards the patients foot. The zonule gives way below but not above and the lower border of the lens rolls up in front of the hook

C—The point of the hook has been rotated upwards the cornea is being folded behind the lens, which is hanging out of the eye by its upper attachments.

D—The downward pull has been continued too long and vitreous is presenting below the lens. To correct the error before harm ensues is simplicity itself, far easier than to correct that shewn in Fig. 41 C, *while if the case has been properly selected*, the lens cannot drop back into the eye as it did in Fig. 42.

through the wound, lower edge first. The suspensory ligament remains attached above even when the lens has been completely delivered. It has to be stripped off by drawing the concavity of the squint hook across the wound behind it. *If the capsule ruptures at any time* during delivery by this method it is still anchored above and its removal is relatively easy.

In putting on pressure to make the soft lens turn a sumersault in this way (or to " tumble " as I term it) the hook is laid on the eye on the flat with the point as before over the junction of the lower and middle thirds of the vertical diameter of the cornea. The same backward *twist is given to the point but this time the rotation of* the shaft is continued until the resistance of the sclerocorneal ring is felt. This ring is much firmer than the flexible cornea, and if the point is pressed into the cornea as it is rotated 90° downwards, a grip can be obtained upon it. With this grip we endeavour to pull the patient's eye towards his feet and he unconsciously resists our effort. If the pull is maintained the wound gapes, and the lens, which is soft and moulds easily, appears to roll upwards, dislocating at the lower edge first. The downward and backward pressure should not be relaxed until the rolling up of the lens is well advanced. The point of the hook is then twisted upwards by rotating the handle of the instrument between thumb and fingers, and the cornea is folded behind the lens with the gentlest pressure. (Fig. 38.) When this has been done, the lens lies on the front surface of the cornea still attached to the suspensory ligament above, which has

acted throughout like a hinge. It is peeled off by drawing the heel of the hook, concavity forwards, across the wound behind it. (Fig. 39.)

Considering the physics of the question it will be clear that in the initial twist backwards the nucleus of the lens slips up through the fluid cortex above the point of the hook, and that the downward pull deforms the sclero-cornea and ciliary region from a circle into a pyriform shape, the stalk of the pear below under the point of the hook at 6 o'clock. At this point therefore the strain on the zonule is greatest and at this point it first gives way, permitting the hydrostatic pressure set up in the vitreous to drive the lower border of the lens forward in front of the point of the hook. At the same time the downward pull against the sclero-corneal ring makes the corneal wound gape and increases the sectional area of the hole through which the lens is asked to emerge.

Once the greatest diameter of the lens has passed through this opening, the backward pressure must be relaxed and the downward pull give way to an upward twist. If they are continued too long the cornea will be drawn away from contact with the lower surface of the lens and vitreous will be driven forward to present between the two (the suspensory ligament being intact above it can only present here). (Fig 38, D.) But even then it is only in very clumsy hands that any loss will occur. For it is a very easy matter to repair the damage immediately by making good our omission to twist the point of the hook up and to relax the backward pressure at the appropriate time. A simple roll of the handle of

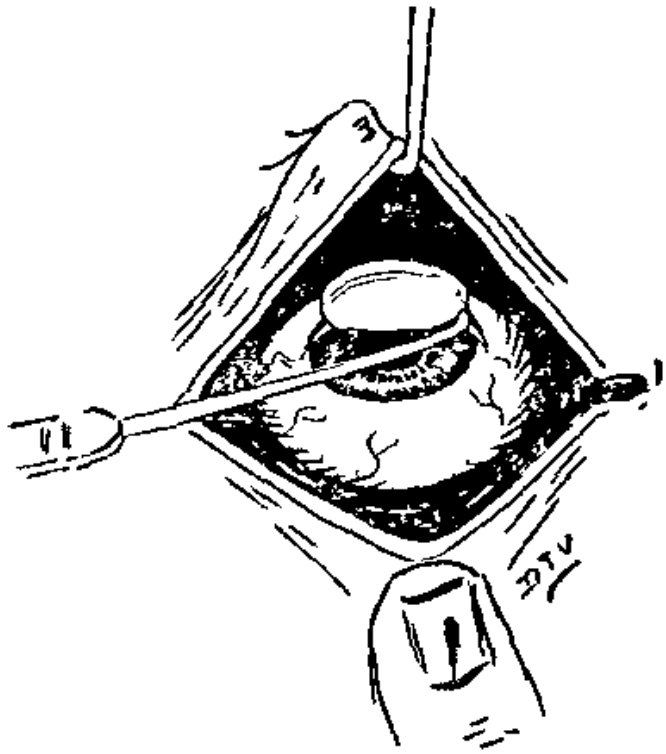

Fig. 39

The lens has been tumbled and is lying on the front of the cornea The heel of the hook is being passed along the wound under it to separate it from its final attachments.

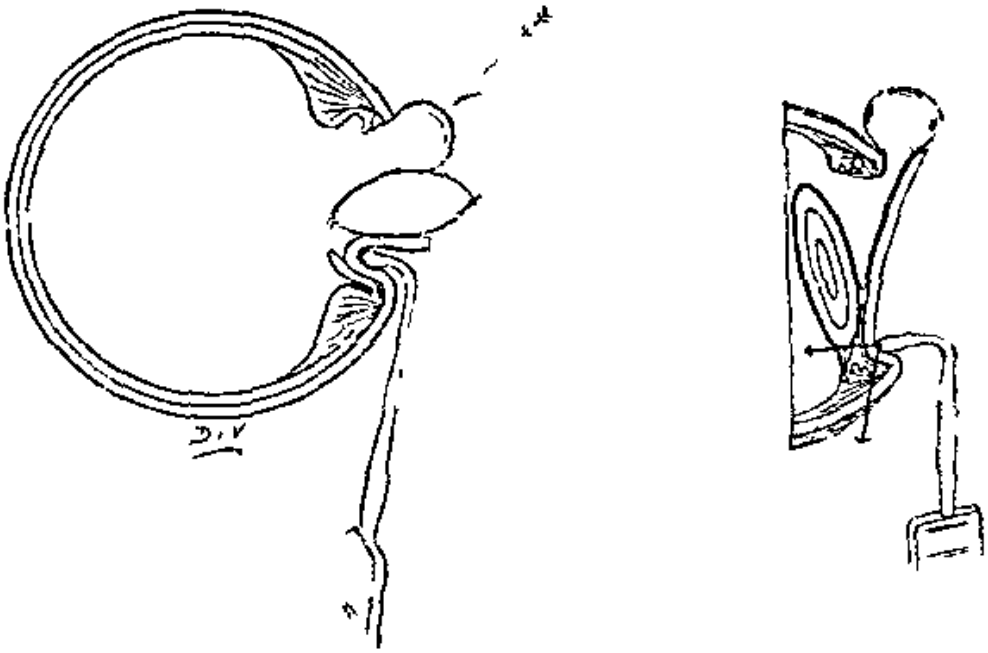

Fig 40

An attempt has been made in order to deliver a hard cataract as a "tumbler" by pulling downwards against the sclero corneal ring On the left the lens was fairly easily dislocated and the zonule has ruptured both below as well as above but vitreous is presenting above and it will have to be delivered on the spoon On the right the zonule has not given way below and the lens has dropped back into the eye before the spoon could be got behind it—a disastrous accident If there is any doubt about the diagnosis or if the lens does not come at once according to expectations, no attempt should be made to "tumble" it with the lens hook over the cornea, but the technique should be adopted which is described in a later section and illustrated in Fig 46

the instrument between the thumb and fingers is all that is necessary to regain complete control over the presenting vitreous.

Delivery of the Morgagnian lens as a tumbler this way is a pretty manœuvre and easy to learn. In teaching men to operate on the living subject I found that they quickly dropped into the trick of doing it. And it is devoid of the risk of escape of vitreous which is present in the method of upright delivery.

There are two warnings which must be given. These Morgagnian cataracts are the bulkiest of all types. In general the bulkier they are the weaker is their capsule. If they are to be extracted without bursting it, an incision of 180° is an absolute minimum, in which none of the depth available in the sclero-cornea has been wasted by splitting the coats of the eye with the point of the knife at the puncture and counterpuncture. An incision of a few degrees over the half circumference would considerably reduce the number of burst capsules. The second, that if an error in diagnosis has been made and pressure is applied in this way to a hard cataract trouble will occur if its anchorage is strong (with weak zonule dislocation takes place at the first backward twist and all is well), the zonule will rupture above first, vitreous will be expressed, and if the operator is not on the alert, the lens will drop back into the eye before the spatula can be inserted. (Fig. 40.)

The line of distinction between hard and soft cataract cannot in practice be drawn with accuracy and if there is *any* doubt the method of delivering hard cataracts

as tumblers (to be described in the next section) should be adopted, owing to the risk of this accident.

A CONSIDERATION OF THE FACTORS WHICH LED TO THE EVOLUTION OF AN ALTERNATIVE TECHNIQUE FOR THE EXPRESSION OF THE HARD LENS.

Up till the time when I retired from the I. M. S. in 1921 and left India I practised the two methods just described to my complete satisfaction. I was able to express the hard lens upper edge foremost without loss of vitreous in 99% of the cases. The 1% in which I was unable to avoid it, were mainly of the type "hypermature *ab initio*" which are anyhow entirely unsuited for the capsulotomy operation. With the Morgagnian lens my loss of vitreous was practically nil and I was far too busy to sit down and review results elsewhere when my own methods were giving me as good results as I could desire.

In the summer of 1921 I undertook at the request of my old pupils a trip through the U. S. A. and Canada in order to demonstrate my methods. I attended the Annual Meetings of the Medical Associations of most of the States of the Union and of the Provinces of the Dominion, and operated upon between 500 and 600 cataracts at clinics which were raised for me.

Everywhere my old pupils told me that, while the methods I was using left nothing to be desired in my own hands, yet in most men's hands they were attended with a prohibitive loss of vitreous, especially in the case

of hard cataract. Though some of the most dexterous of my pupils, who had worked up sufficiently large clinics to keep their hands in practice had but little loss of vitreous, to most of them it was still a grievous source of dissatisfaction. And it was completely scaring new men who had not been to me in India from taking up the intracapsular method.

During the next four years I was able to pay attention to the new methods of removing the lens in its capsule which were being devised on every hand, all of them involving the use of some intraocular instrument and being regarded essentially as methods of extraction rather than expression. (The fallacy has already been pointed out of regarding them as less potent for damage to the intra-ocular structures than the method of expression from without.)

The first man to use a capsule forceps of the ordinary type extensively was Stanculaneau of Bucharest though there were others of lesser degree who have used instruments essentially the same in principle with modifications of but small importance. I have already laid down that success can never be obtained as a routine if the surgeon simply endeavours to pull the lens by main force out of the eye. If he does so he will put an equal strain upon the suspensory ligament all round and will generally tear a piece out of the capsule before he succeeds in dislocating the lens.

Just as in the expression methods, the lens must be made to swing round on some transverse axis so as to concentrate the strain on the suspensory ligament at one

or two points. When the ligament has given way at these points and the lens is dislocated from the patellar fossa then and then only can it be removed from the eye.

To Arnold Knapp of New York belongs the credit of showing the world the proper way to use a capsule forceps. When with me at Jullundur he was greatly struck by the ease with which the Morgagnian lens can be made to tumble by pressure with a squint hook, and with the perfect control which the operator then possesses over threatening escape of vitreous. In the method he practises he takes a grasp of the capsule below, as far from the incision as possible, and by backwards, sideways and forwards movements he either ruptures the attachments here or tears a hole out of the capsule. He then removes the forceps. If the capsule has given way he proceeds with the capsulotomy operation. If the attachments have ruptured, he places the lens-hook on the cornea below and presses straight back towards the optic nerve. The lower border of the lens comes promptly forwards and he delivers it as a "tumbler," the zonule remaining attached above to the last. With this technique Knapp not only obtains perfect control over the vitreous and has the capsule within easy reach if it should burst during delivery. He also gets away from the disadvantage attaching to all capsule forceps, mechanical or pneumatic, when used to extract the lens as well as dislocate it—that the corneal wound has to be enlarged to permit the passage of both lens and instrument.

The pneumatic capsule forceps, whose establishment by Barraquer in recent years as a practical addition

to the armamentarium of the ophthalmic surgeon has created such a stir, appeared at first sight to be little different from the other types in principle. It seemed to have but one advantage over them, that it took a softer and a wider grip of the capsule, while it shared with them the disadvantage of requiring an enlarged incision. But those who observed Prof. Barraquer operate, did not fully realize his art. It is often, I might say, generally, easier to execute a thing than to describe exactly how one does execute it. This matter is considered fully in a later chapter on account of the valuable lesson to be learned from it in the use of capsule forceps of any kind if they have to be used at all.

Now I have always had an aversion to any form of capsule forceps on account of their absolute lack of flexibility. The diagrams which their inventors display look very nice on paper, but they ignore one vital factor, the mentality of a conscious patient. For the introduction of the instrument the patient must be told to look down. The mere giving of orders to him, in the highly strung apprehensive state in which he is, may provoke an explosion. It is difficult enough to extract a cataract by the expression method in a patient who is behaving badly, but if an instrument has to be introduced into the eye to do it, it becomes impossible.

But even if the patient behaves well and looks down quietly, this very act, with an upper incision, increases the risk of loss of vitreous. The natural position of rest, in which the extraocular muscles are relaxed, is for the eye to be rolled up under the upper lid. It is the con-

traction of the rectus muscle opposite the incision which puts pressure on the globe. I found that in a small class of patients who will persist in looking downwards, I was much less liable to lose vitreous if I made a lower incision instead of an upper one. And when I had for optical reasons to make a lower incision I found that if the patient suddenly strained to look upwards he also was likely to press out vitreous.

Entirely apart from these considerations all the forms of capsule forceps, mechanical or pneumatic, are very liable to fail half way through the task, either by tearing the capsule, or by losing their grip on it. The capsulotomy operation or the intra-capsular expression method have then to be called in under very adverse circumstances to clear up the mess which has been left behind. In my tour of the U. S. A. in 1921 I advised those men who were experimenting with forceps extraction methods (mechanical or pneumatic) to help matters out by simultaneous pressure with the squint hook from the exterior, and I have since heard that those of them who tried this out have achieved much greater success. But even so matters are far from satisfactory. On a return visit to the Punjab in the winter of 1925-6 I determined to work out a method of delivering hard cataracts as tumblers solely by pressure from without. In my early days I had tried using the squint hook over the sclerotic for this purpose, but was misled into throwing it up by having an undue number of cases of choroidal hæmorrhage on the day on which I did so. I attributed these cases to the method, stating so in a paper

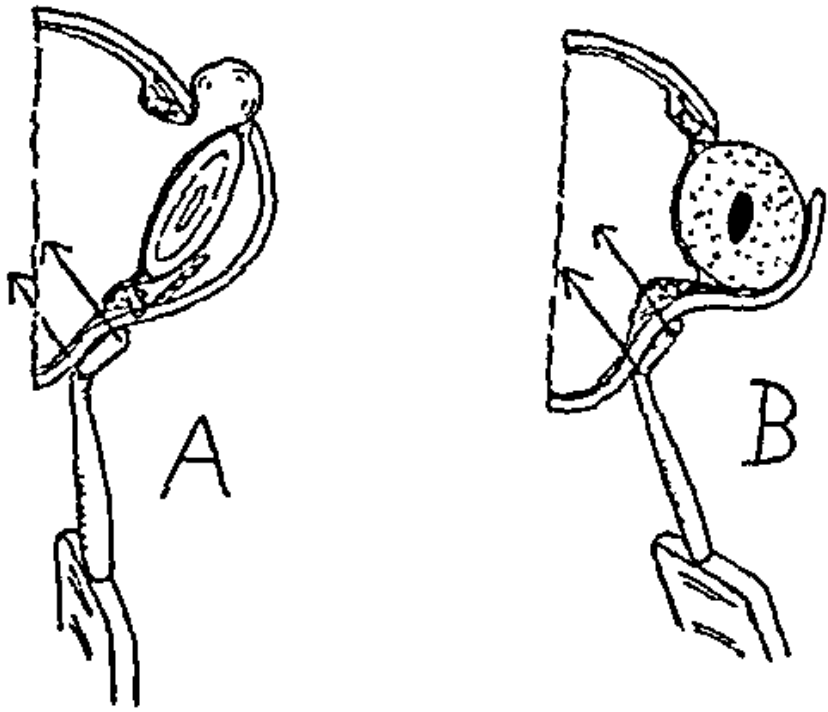

Fig 41

Pressure on the Sclerotic Below.

On the left with a hard lens the zonule gives way at the wound and vitreous presents, on the right with a Morgagnian cataract the zonule gives way below, the lens tumbles, and all goes well. (A sclero-corneal incision having been used in both cases).

written to the Indian Medical Gazette at the time in 1906, but I have since realised that I was mistaken—they occurred by pure accident. I have therefore reverted to the method (to be described in the next section) which simplifies matters to an extent almost beyond my dreams, giving, even in relatively unskilled hands, an almost perfect control over the vitreous.

(C) Tumbling the Hard Lens by Combined Pressure with Lens-Hook and Spatula.

In this method pressure with the squint hook over the sclerotic opposite the incision, *i.e.*, at six o'clock, behind the lens, is used to raise the tension of the vitreous up to the point required for dislocation. The pressure exerted by the vitreous on the back of the lens is distributed evenly which puts the zonule on the strain equally all round. With a sclero-corneal incision there is least obstruction to the movement of the lens behind the middle of the wound. If a hard lens, the zonule will give way here first and vitreous will be expressed (a Morgagnian however tumbles in the ordinary way and all goes well). (Fig 41.) If, however, an obstruction is created to the forward movement of the upper border of a hard lens by placing the spatula, with its convexity backwards, over the incision, and by applying just sufficient pressure to prevent that edge of the lens from shifting, the lower border will have no option but to come forward. The lens is thus made to swing forward about a transverse axis passing through its upper border. The strain on the zonule is greatest below and it gives way here first, the lower

border of the lens "tumbles" up, enabling the point of the hook to be insinuated through the cornea behind it.

The hook used for this purpose should be short beyond the bend so that there is no difficulty in accommodating it in the inferior conjunctival fornix. It is placed here on its flat over the sclerotic, the point upwards but well behind the edge of the lens, *i.e.*, about 5 mm. from the sclero-cornea. With the spatula in place above, steady pressure is exerted with the flat of the hook towards the centre of the globe in order to put up tension in the vitreous. This pressure is maintained as the point of the hook is slowly advanced towards the sclero-cornea, and inreased until the zonule gives way. The lower edge of the lens will then swing forward, until it is arrested by the cornea and the deformity set up in this structure is visible to the naked eye. (Fig. 42). When this occurs the pressure with the lens-hook is relaxed, sufficient being maintained with the heel alone to keep the lens in place. The point is lifted slightly to disengage it from the fold of conjunctiva in which it is liable to catch. As it is slid forwards on to the sclero-cornea to be insinuated behind the advancing lower border of the lens, the spatula may now be lifted from the wound, to avoid risk of bursting the capsule between the two instruments as the lens is expressed by gentle pressure with the point of the hook used to fold the cornea beneath it as it emerges. It must be remembered that the hard lens requires time to mould, especially if it is a tight fit for the wound. The surgeon must

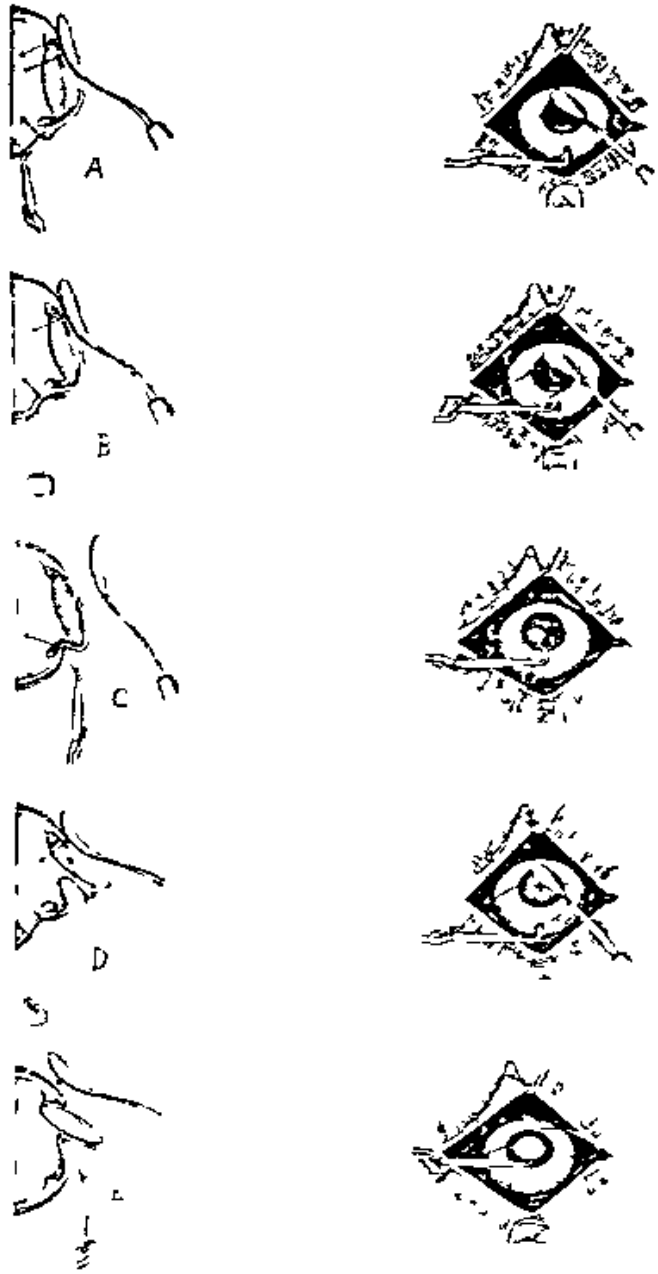

Fig 42

Tumbling the hard cataract by combined pressure with spoon and lens-hook.

A—The spoon is laid with its convexity over the wound and keeps the upper pole of the lens front moving The lens hook is laid on the sclerotic below, care being taken that it is *behind* the lower pole of the lens.

B—The lens dislocates below and its lower border comes forward to bulge the cornea, and is kept in position by pressure with the heel of the hook. The point of the hook is lifted to disengage it from the conjunctiva in which it is liable to catch as it is brought up after the lens

C—The point of the hook is dropped into the sclero cornea preparatory to insinuating the cornea behind the lens

E—The spoon having served its purpose, it is lifted off the wound.

D—The lens hook has been kept on the sclerotic too long and the vitreous is presenting below the lens It is however a simple matter to correct the error before harm ensues.

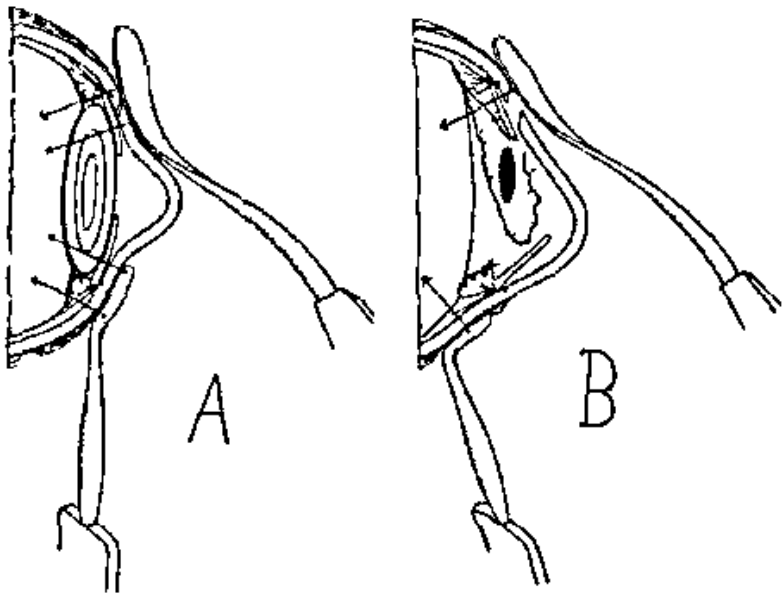

Fig. 43

A—The case has been correctly diagnosed as a hard cataract but the lens-hook is too far forward, its point lying in front of the lens, which in consequence will not move Some lenses extend much further beyond the sclero cornea than is often imagined, and it is well to start with the hook right down in the lower fornix in the first instance, sweeping it up slowly till the lower border of the lens is encountered.
B—Combined pressure has been applied to a big swollen Morgagnian cataract Accident would have still been avoided if the spoon had been lifted at once when the lens began to come forward but as matters are, it has been squeezed between the two instruments and the capsule has been burst. This however is a far less serious accident than those depicted in Fig. 45, where the lens drops back into the eye.

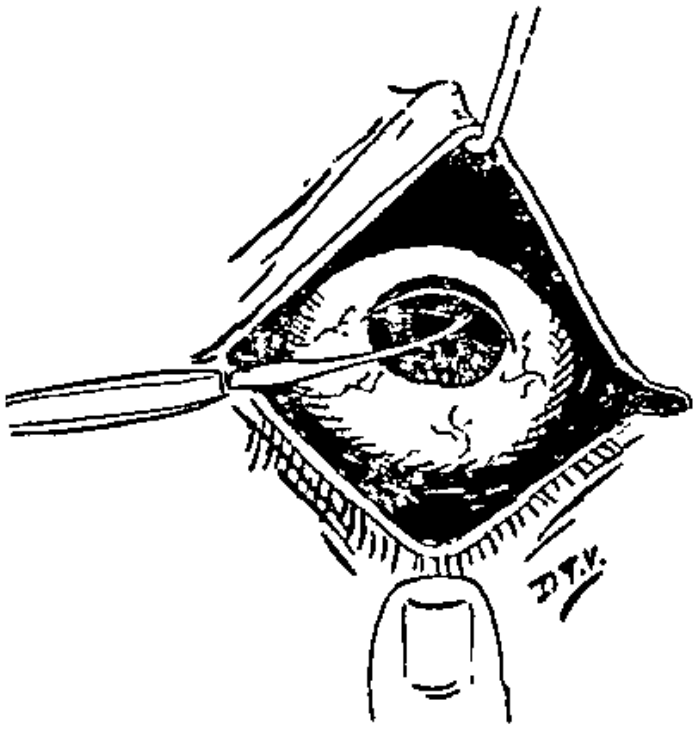

Fig. 44

Replacing the iris after the cataract is extracted. The assistant still holds the upper lid away from the eyeball by means of the lid hook, and everts the lower lid with the thumb of his left hand, while the operator uses the iris repository to rake the cut root of the iris from its position against the scleral side of the corneal cut The cut iris root clings to this cave-like projection and should be separated by passing the iris spatula along under this cave from one end of the incision to the other. Notice that in doing this, the end of the spatula points upwards toward the summit of the eyeball.

exercise his patience while it does so and anyhow he has no need to hurry.

As in any other method, if the pressure required to dislocate the lens is continued after it has achieved its object, the vitreous will be driven forward. But in this method, as in that of tumbling the soft cataract, the suspensory ligament remains attached above throughout and is an effective barrier to escape of vitreous above the lens. It will present below, between it and the corneal flap if the under-presure is continued after the lens has been dislocated, and here again it is under perfect control. It is a simple matter to repair the omission to *relax the pressure and slide the point of the hook up on* to the cornea at the appropriate time.

Two warnings only are necessary. If this method of combined pressure with lens-hook and spatula is applied to the big swollen Morgagnian cataract in the stage of intumescence there is considerable risk of squeezing it between the two instruments and bursting its capsule. (Fig. 43, B.) There is no necessity for applying it, as this type is the easiest of all to deliver as a tumbler by my original method of a downward pull against the sclero-corneal ring. (Fig. 44.) But in case of doubt as to the type of lens with which he is dealing, the surgeon should not persist with pressure over the cornea. If the lens does not dislocate easily he should treat it as of the hard type and work with the *lens-hook over the sclerotic, on account of the danger* with the former method of rupturing the zonule opposite

the wound above, and so expressing vitreous while leaving the lens in the eye. (Fig 40.)

The second warning concerns the necessity for making sure that the hook really is applied in the first instance behind the lower border of the lens. Some lenses extend much further behind the sclero-cornea than one imagines and it is as well to start the hook right down in the lower fornix and sweep it up until the resistance of the lens is felt. (Fig. 43, A.)

This method of delivering the hard lens as a tumbler by combined pressure is revolutionary. It is simple and easy to learn. In all but the clumsiest hands it should be entirely devoid of escape of vitreous, which in the method of expressing the hard lens upright is a nightmare to the beginner. It should rob intracapsular extraction of the senile lens of all its terrors. For it enables us to apply the force necessary for the dislocation of the most stubborn lens while keeping it under perfect control. No complicated instrument is invoked to " cut the zonule without traction or violence " or to " draw the entire cataract gently to the exterior without pressure or stretching, without the production of ectopias of and traumatism to the intra-ocular structures." The instruments required are simple, and no pretence is made of the method providing a royal road to success which will cut short the necessity of training the hand and fingers. But once skill has been gained the surgeon will be able to give up " selecting " his cases. In practice this has meant the application of nearly enough force to dislocate a stubborn cataract, and then giving

it from the sclera. This should be repeated at the other up when almost as much trauma has been inflicted on the eye as if the lens had been actually dislocated but without the advantage of its removal to compensate for it. In fact this method enables us to extend with safety the benefits of intracapsular extraction to the type of cataract occurring between the ages of twenty and thirty, which were previously quite beyond its range.

In my opinion the time is now not far distant when Daviel's operation will be but a tradition of the Fathers, and when Barraquer's vacuum spoon will share a shelf in the Museum with all the varieties of Kalt forceps, there to be inspected as objects of historical interest. For the two methods which I have described of delivering the soft and the hard lens as "tumblers" by external pressure alone are so simple and so efficient that they are bound to prevail the world over.

The Toilet of the Wound.

The iris is a sticky membrane, and at the operation will be found not only caught up in the angles of the wound but adhering to the under surface of the scleral flap. If not released, it will stay there. Any iris-repositor will do for the job. If the patient is troublesome it is difficult to see what we are doing without struggling with him, a thing to be avoided if possible. If the point of the iris-repositor is drawn across the more rigid *sclerotic towards the angle of the wound, we will feel at* once when it drops in. We now know that it is on the iris and should give it a sweep in both directions to release

angle, and finally the point of the repositor should be drawn right across under the scleral lip of the wound. The intact iris or one in which only a peripheral hole has been made are much easier to replace than are the pillars of the coloboma after a complete iridectomy.

There is no need to swab or douche out the conjunctival sac for traces of lens matter or blood as these cause no harm, and the disturbance of removing them may lead to the iris or vitreous being squeezed out.

Closure of the Lids and the Applications of Dressings.

When all is complete the patient is told to close *both* eyes gently. When the eye is seen to roll up under the upper lid it is a sign that he has understood and is obeying our order. Then and not till then, should the lids and brow be released. For if the patient is nervous, and the lids are released before he understands the order, he may misbehave and sorely try our temper.

The lids should then be smeared with some antiseptic ointment or sterile vaseline to prevent the lashes sticking to one another and to the dressing, a source of considerable discomfort to the patient. A small pad of cotton wool wet with mercury solution should be placed on the lids. This will, when dry, be moulded accurately to the contour of the parts and form an excellent splint.

If we wish to operate on the second eye at the same sitting, there is no objection to doing so, so long as the first eye is covered during the process to prevent the patient blinking.

Over all, a large pad of cotton wool should be placed. It should cover both eyes, leaving a slit in it for the nose, and extending up over the forehead and out over the bony prominences over and about the orbit. This will enable it, if it is of uniform thickness, to subserve its first function, of taking all the pressure of the bandages off the eye. I use a figure-of-eight bandage which is quite satisfactory if care is taken to run the turns over the bony prominences but adhesive plaster will do as well. One of the many forms of mask intended to prevent the patient from unintentionally rubbing the eye is very useful, provided it does not itself defeat its own function by pressing on the eye. The second function of the cotton wool pad is to exclude light. It does this better if it is coloured than if it is white, and it should be amply thick. Even the sound eye is very sensitive to light during the first week or so, and if it is open its movements and the blinking of its lids are accompanied by associated movements of the operated eye which disturb the wound and delay healing.

Accidents and Complications during the Operation.

(1) *The conjunctiva tears where it is held by the fixation forceps* while the incision is being made. This accident sometimes happens in old people. The surgeon will have to complete his incision and bring out the knife where he can, not where he wishes, and may give up all idea of corneal sutures.

(2) *The lens and some vitreous are shot out on completion of the incision.*

If this happens it means that the surgeon has cut out without pausing in a nervous patient or has not let go promptly with the fixation forceps, or that the assistant has not been quick enough in whipping the speculum out.

But if it happens the assistant must take charge of the lids while the surgeon confines himself to snipping off the protruding vitreous (Fig. 45), to make sure that the stroma of that body does not get caught in the wound and act as a drain to keep it open. He should not attempt to do an iridectomy for he will inevitably express more vitreous in doing it. And it is not necessary, for the iris seldom seems to prolapse in these cases. When the bandages are opened the surgeon will be surprised to find a perfect cosmetic result, a nice round mobile pupil, with no appearance of harm having ensued.

(3) *Loss of vitreous during expression of the lens.* Any protruding bead should be snipped off for the reason explained in the preceding section.

(4) *Burst capsule during delivery of the lens.* The commonest cause of this is too small an incision, and a contributory cause is over-hastiness on the part of the surgeon in expressing the lens. I assume of course that it is not due to an attempt to deliver a Morgagnian cataract upright, or to make it tumble by the combined pressure with spoon and lens hook which is used for the hard lens, in which latter case it is an inevitable result of the lens being squeezed between the

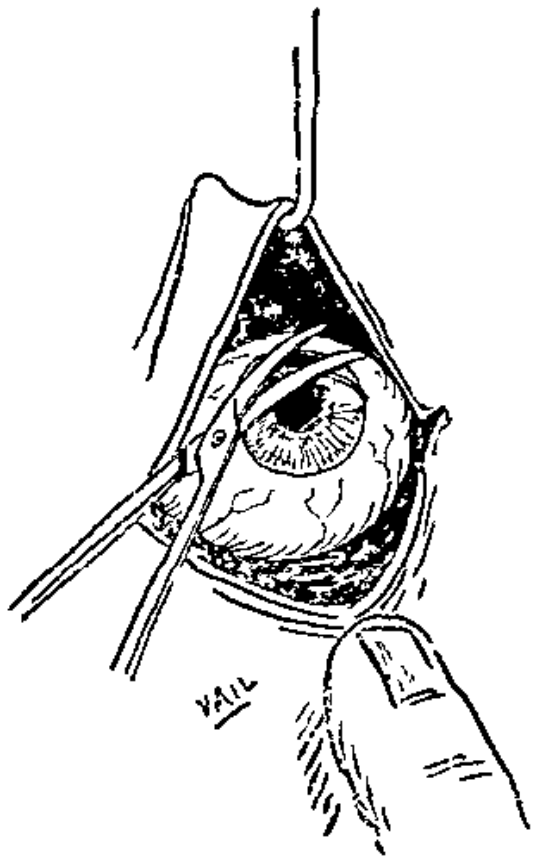

Fig 45

There has been an escape of vitreous The lens, however, has been extracted. The operator trims off the vitreous hernia as shown in the figure, while the assistant drags the eyelids well away from the ball, and at the same time pushes the eyebrow well upon the forehead thus preventing further escape.

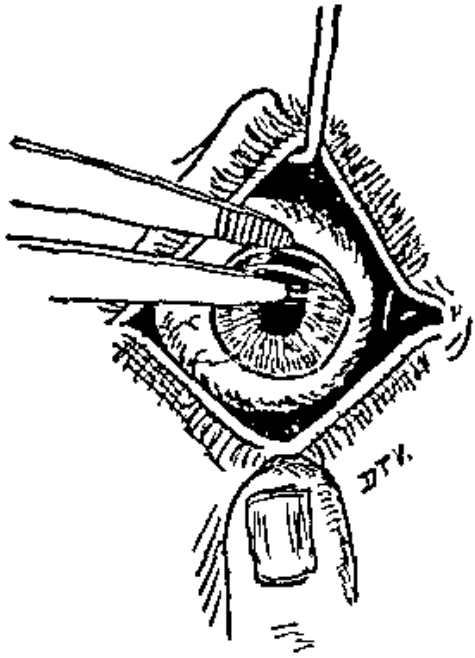

Fig. 46

Showing the method of grasping the capsule which has ruptured and hangs half out of the wound. Ordinary well made dissecting forceps are used as shown, the pressure and movement being made with the lower arm of the forceps, while the upper is held steady at the scleral lip of the wound

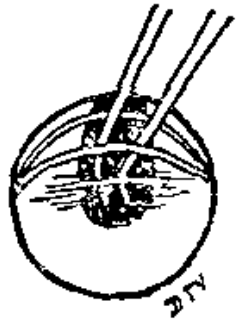

Fig 47

Showing the iris forceps going into the eye in the act of grasping the capsule which has ruptured and remains in the pupil space after the nucleus of the lens has escaped

two instruments. This source of burst capsule can only be avoided by the surgeon training himself in the diagnosis between soft and hard cataract.

If the capsule bursts, the spatula should be transferred to the front of the cornea to maintain the pressure and keep it from slipping back into the eye, while with the right hand we reach for a pair of dissecting forceps with which to grasp it and pull it out. These are better than iris forceps for the purpose as they take a broad soft grasp and bring the capsule away entire. If it slips back into the anterior chamber and it is still attached above as it is when one of the methods of tumbling the lens has been employed, it will jump out into the grasp of the dissecting forceps if they are used to milk the wound. One limb should of the widely opened forceps be rested on either lip and sufficient pressure made with them as they are closed to force the capsule out of the eye. (Fig. 46.)

If this fails, we must resort to a pair of iris forceps or a pair of small dissecting forceps. They should be inserted closed into the eye, opened, closed again and brought out with what is in their grasp. (Fig. 47.) The capsule will generally be found lying much nearer the cornea than one would expect. The iris forceps for this purpose will take a much softer grip if the arms are made so that they come together when closed all the way from the point to the bend, and are milled on the inside.

The surgeon must not desist without reasonable effort until he has got the capsule out even at the expense

of some loss of vitreous, for it is much more difficult to extract at a second sitting than is the ordinary after cataract following Daviel's operation. This is because it is floating loose in the aqueous, and when an incision is made to extract it, the vitreous comes forward at once.

Couched lens.—The lens here has floated up again behind the pupil as if on a hinge owing to the suspensory ligament remaining attached at some point. This is the case which startles the inexperienced surgeon by dropping back into the vitreous as soon as the section is completed or when pressure is made on the globe. He should examine them carefully beforehand and try to find where the hinge is and make his incision opposite it. He should put in the spatula behind the lens at once to prevent it falling back, and express it with the squint hook, in the same manner as is done when vitreous presents during the upright delivery of the lens. An iridectomy should not be done as the time lost in doing it, facilitates the lens dropping back out of sight.

A soft eye.—An eye is occasionally met in which perhaps owing to fluidity of the vitreous the tension of the structures behind the lens is under normal and when pressure is made with the squint hook the surgeon finds he has no control of the lens. These should be dealt with by placing the tip of the spoon on the sclera behind the lens and getting up the tension. In extreme cases he may actually have to squeeze the globe between the two instruments behind the lens to keep it forward and to invaginate the coats of the eye in between it and the vitreous, above as well as below.

BARRAQUER'S OPERATION.

By J. Russell Smith, M.R.C.S. (London).

(Reprinted by permission of the British Journal of Ophthalmology.)

"I do not believe in violence—especially if it is not likely to be successful."—From Gandhi's Collected Public Addresses, 1919.

Professor Barraquer's article in Dr. W. A. Fisher's book on "Senile Cataract," in the edition published in 1923, by the Chicago Eye, Ear, Nose and Throat College (obtainable from Messrs. H. K. Lewis & Co.), is a mine of information which well repays careful study. He seems to have evolved a method of dislocating and extracting the cataractous lens in its capsule, which, if the claims he makes for it are correct, constitutes a revolution of the very greatest importance. For to quote from page 38: "Facœrisis consists in drawing the crystalline lens by its anterior surface, separating it mechanically without either traction or violence of the zonula (suspensory ligament) and extracting it completely out of the eyeball, without having produced ectopias or traumatism to the intraocular structures. The instrument employed, called the Erisifaco, is nothing more than a pneumatic forceps and a zonulatome. Fig. 39 represents a longitudinal section of the Erisifaco and of the intermittent or vibratory pump which is employed to work it." A critical examination of these claims should be of interest to the profession.

The first thing to examine is this vibratory pump on which a very large part of the claims for the method are

based. A year or so ago Professor Barraquer did my father the kindness of presenting him with a complete outfit for facœrisis. Messrs. Down Bros. took the apparatus to pieces for us and examined it minutely. It is an ingenious and exquisitely made piece of machinery. In my description of it, the numbers in brackets refer to Professor Barraquer's diagram, Fig. 39, in his article, which is reproduced as Fig. 48.

The pump consists of an inner cylinder (29) which is solid except for a transverse tunnel (30) bored across its lower part at right angles to the vertical axis about which it revolves. In the bottom of this cylinder there is a fairly wide central circular hole which is bored from its under surface into the transverse tunnel. This hole is in line with the shaft attached to the inner revolving cylinder above, on which is fixed the armature of the electric motor which drives the machine. It engages with the pin (33) which projects upwards from the bottom of the case, and the two form part of the bearings of the machine. The outer part of the pump consists of a cylindrical case, which above contains the magnets of the motor, below is accurately machined on the inside to fit the central revolving cylinder (29). In it are two holes (35 and 37). These are placed diametrically opposite one another in the horizontal plane in which lies the axis of the transverse piston tunnel bored in the inner revolving cylinder (29). Hole 35 is the air inlet to the pump; hole 37, the air outlet. The transverse piston tunnel contains a solid piston, not long enough to fill it, and machined accurately to fit its walls. In the

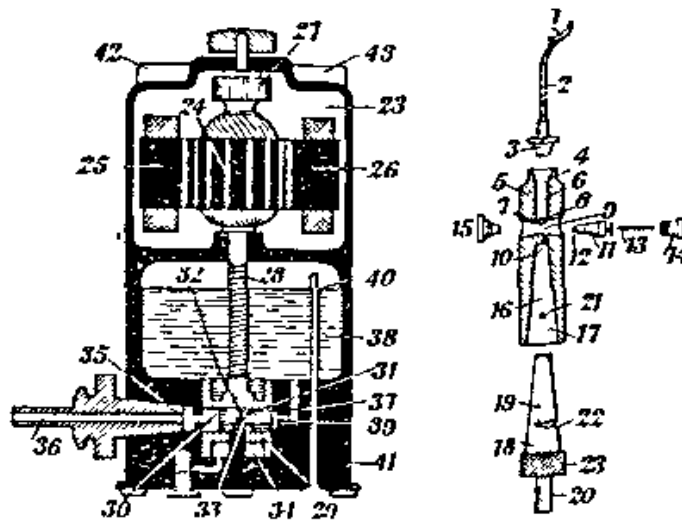

Fig. 48

Fig 39 from Barraquer.
Vertical section of pump and handpiece.

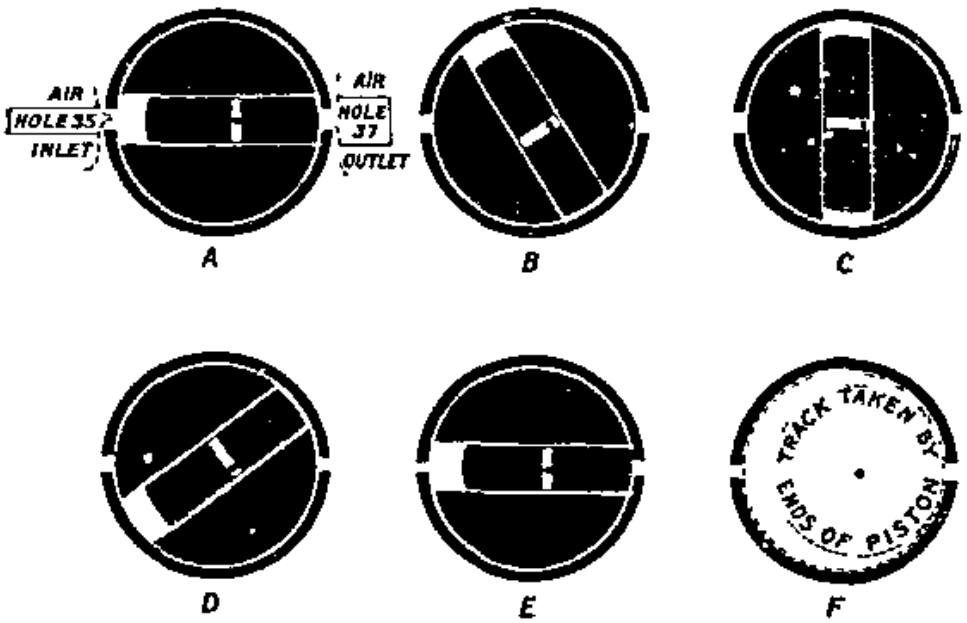

Fig. 49

Transverse section through pump at various stages in the cycle of operations.

middle of this piston, on its under surface, is a transverse slot in which works a small eccentric projection (A) of the pin (33) fixed in the case.

The working of the pump is easily explained by the diagrams in Fig. 49 which represent horizontal sections through holes 35 and 37, and the piston tunnel at successive phases in one revolution of the central cylinder. The small eccentric pin attached to the case is set so that at the starting point when the tunnel is in line with the two holes 25 and 37, the end of the piston which is opposite hole 37 is in contact with the walls of the case; the end opposite hole 35 is furthest away from them. The next three diagrams represent the intermediate stages, the fourth—the completion of half a revolution, while in the last—the track taken by the ends of the piston is dotted out. It will be seen how they gradually leave the wall of the case as they pass from hole 37 towards hole 35, so producing a space in the tunnel into which the oil cannot get to fill it up as fast as it is formed, for the parts are as accurately machined and fitted together as the engine of a Rolls-Royce motor car. When the tunnel reaches hole 35 air rushes from the latter into the space to fill up the vacuum which has been formed in it. In the second half of the cycle the piston again approaches the walls of the case, so compressing the air in the tunnel, and expelling it finally through hole 37.

It is thus clear that once in each half revolution air is sucked in from the tubing attached to hole 35, and a sudden alteration is produced in the pressure of that

which remains behind—the variation in the intensity of the vacuum, termed by Professor Barraquer its interruption or vibration. The rate at which these variations succeed one another is 5,000 per minute, according to his account, which involves the pump running at 2,500 r.p.m. The degree to which it is capable of exhausting the air in a closed chamber attached to it is dependent on several factors, the vapour pressure of the oil used, being the ultimate theoretical limit. In practice the speed at which it works has some bearing, and varies with the viscosity of the oil used and the voltage of the current applied to the motor. Professor Barraquer supplies oil of relatively high viscosity, but Weiss told me that they found it to be most efficient with the thinnest oil available.

The device, which is used to regulate the intensity of the vacuum and the amplitude of the variations in it, is most ingenious. It is attached in different machines to different parts of the apparatus, and has been altered in detail in successive models, but in all it is in principle the same. It is a variable air leak, Fig. 50, which can be set to let air into the apparatus at any desired rate. In its latest form it consists of two parts, an inner and an outer metal tube whose adjacent surfaces are machined to a conical shape and fit one another accurately. There is a hole drilled through the inner part which is the only communication between the exterior and the interior of the apparatus except that at the cup of the Erisifaco. This latter is normally sealed by the lens when it is in action or shut

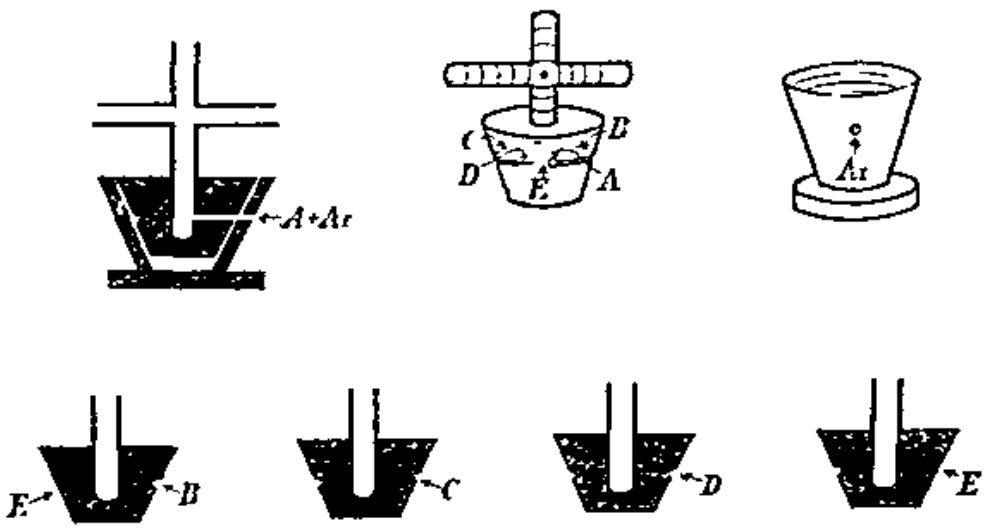

Fig 50

Diagram of variable air leak.

off by the valve in the handpiece. On the outer conical surface of the inner tube is a V-shaped groove which starts from the hole and passes round in a circle almost but not quite to the hole again. It gets gradually shallower until it finally fades away into a short piece of smooth surface lying between its own end and the hole. The outer part has also a hole through it, which, when the two are fitted together, overlies the hole in the inner part or some point on the circle in which the groove in it is cut. The two parts are not secured to one another mechanically, but can be twisted round freely to occupy any desired relation and fixed in position by simply pressing them together. It is clear that when the two holes overlie one another, air can get into the apparatus as fast as the pump can take it out. As the outer hole is turned round over the groove the channel through which air can enter gets smaller and smaller. Finally, when it lies over the small piece of smooth surface on the inner portion between the end of the groove and the hole in the latter, there is complete obstruction to the passage of air if the two parts of the regulator are pressed firmly together.

When the air leak is set fully open there can be no vacuum produced in the tubing; there is merely a discontinuous flow of air through it. As the regulator is turned round an obstruction is set up to the entry of air and becomes gradually greater, since the size of the hole through which it must enter becomes smaller and smaller. The intensity of the vacuum produced in the interior of the apparatus is determined by equilibrium

being reached between the rate at which air enters it through the air leak and that at which air is extracted by the pump from it. The same factors are responsible for the difference in the amplitude of the periodic variations in its intensity (the vibrations or interruptions of Barraquer) when the vacuum is high and low in degree. But before proceeding to elucidate these points I wish for the sake of convenience to make one change in Barraquer's terminology. He says that the intensity of the vacuum required varies between 50 and 70 cm. Hg. These figures clearly refer to the difference between the pressure of the atmosphere, 76 cm. Hg. and the mean pressure of the air inside the apparatus. But the intensity of the vacuum is more correctly measured in terms of the latter—that is the custom in most physical experiments on expansion of gases. That is to say, Barraquer's vacua of 50 and 70 cm. Hg. would be better described as being of 26 and 6 cm. Hg. It is a small point, but helps to simplify the explanation of the diagrams in Figs. 51 and 52.

We must first make sure of our definitions. What exactly is meant by the phrase "rate of air flow" through a hole or channel? How can we compare one rate with another? The simplest method is to compare units of *weight* of air passing a given point in a unit of time. If we compare units of volume per unit of time we must measure those volumes at the same pressure, for by Boyle's Law of the expansion of gases the volume of a given weight of a gas is inversely proportional to its pressure.

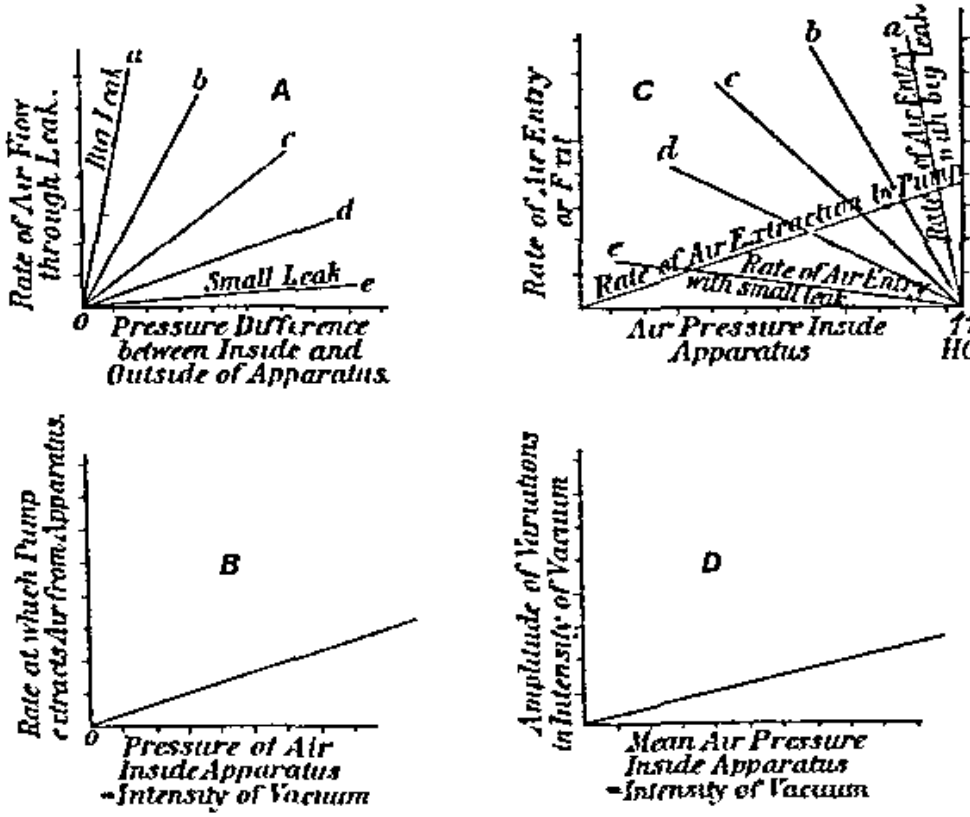
Rate of Air Flow through Leak.
Big Leak
a
b
A
c
d
Small Leak
e
0
Pressure Difference between Inside and Outside of Apparatus.
Rate of Air Entry or Flow
C
c
b
a
d
e
Rate of Air Extraction in Full Vacuum
Rate of Air Entry with big Leak
Rate of Air Entry with small Leak
Air Pressure Inside Apparatus
HG
Rate at which Pump extracts Air from Apparatus
B
0
Pressure of Air Inside Apparatus = Intensity of Vacuum
Amplitude of Variations in Intensity of Vacuum
D
Mean Air Pressure Inside Apparatus = Intensity of Vacuum

Fig. 51

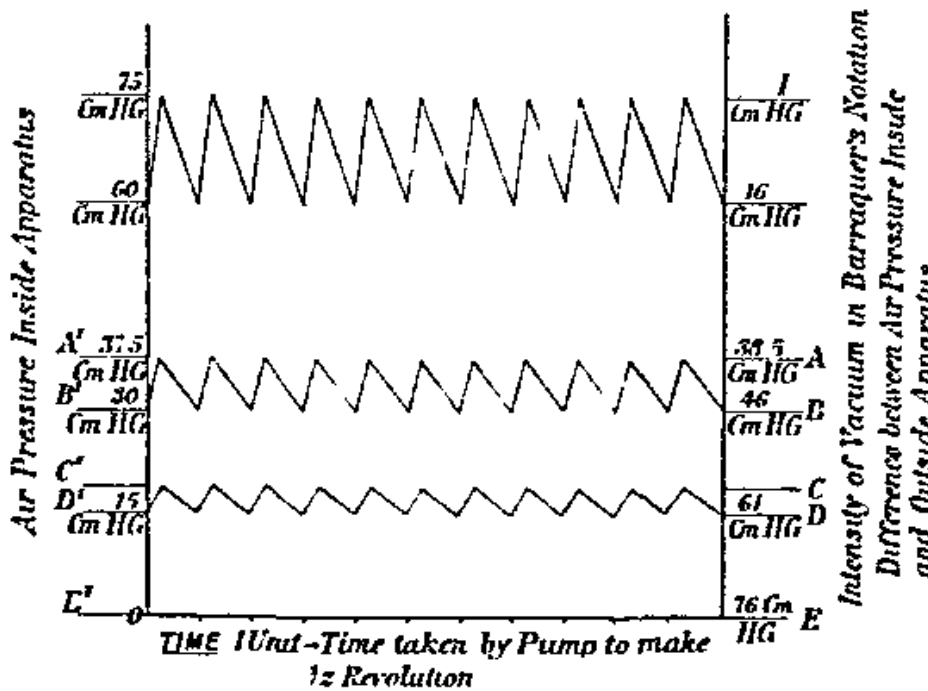
Air Pressure Inside Apparatus
75 Cm HG
60 Cm HG
A' 37.5 Cm HG
B' 30 Cm HG
C'
D' 15 Cm HG
E'
0
1 Cm HG
16 Cm HG
38.5 Cm HG A
46 Cm HG B
C
61 Cm HG D
76 Cm HG E
Intensity of Vacuum in Barraquer's Notation
Difference between Air Pressure Inside and Outside Apparatus
TIME 1 Unit = Time taken by Pump to make ½ Revolution

Fig. 52

The graphs in Figs. 51 and 52 are frankly diagrammatic and are based on a deduction of what ought to happen from theoretical consideration only. The first, Fig. 51 A, shows how the rate of air flow through the air leak is affected by variations in the intensity of the vacuum. The former is plotted vertically against the pressure difference between the outside and the inside of the air leak. It is directly proportional to the latter, the size of the air leak remaining constant and the ensuing graph is a straight line. The different lines are the graphs with different sizes of air leak, being horizontal when there is no leak at all, increasing in slope to nearly vertical as the air leak is opened to its full size. Fig. 51 B shows how the rate at which the pump can extract air from the apparatus varies with the intensity of the vacuum in the latter. It is nil when the intensity is highest, *i.e.*, the air pressure in the apparatus is lowest and rises steadily in correspondence with increase in that pressure. It is directly proportional to the weight of air extracted by the pump at each half revolution if we assume for a moment that the speed of the latter remains constant. The volume of this weight of air is constant, since the size of the empty space which it fills in the piston tunnel cannot alter. Since the weight of a given volume of gas varies directly as its pressure, we see that the rate at which air is passed through the pump must be directly proportional to the pressure of the air inside the tubing. This gives us the straight line graph shown in Fig. 51 B.

In Fig. 51 C the two diagrams are superimposed on one another by taking the mirror image of Fig. 51 A

and placing its zero at the point corresponding to a pressure of 76 cm. Hg on Fig. 51 B. The points at which the graphs of Fig. 51 A intersect with that of Fig. 51 B give us the mean intensity of the vacuum produced with air leaks of different sizes, for at those pressures equilibrium is reached between the rates of entry of air through the air leak into, and of its extraction from the apparatus by the pump.

Now the volume of the tubing may be assumed for practical purposes to be constant. Hence the amplitude of the periodic variations of the pressure of the air within it must be proportional to the weight of air extracted from it by the pump at each stroke. For it is the fact that this extraction occurs during a short part only of the time occupied by a half revolution which is responsible for the presence of the variations. We have already seen that this weight is directly proportional to the mean intensity of the vacuum, measured in terms of the actual pressure of the air in the tubing. This gives us Fig. 51 D in which the amplitude of the variations is plotted vertically, the pressure of the air in the tubing horizontally, and the resulting graph is a straight line.

In Fig. 52 the same thing is represented in a form which better strikes the eye, the pressure of the air inside the tubing at any instant being plotted vertically, the time horizontally. The resulting curves show the periodic rise and fall of the former, and how this is greatest when the vacuum is on the point of collapsing, is practically nil when it is most intense. Compare this with the tracings in Fig. 53 (Fig. 58 of Barraquer's article)

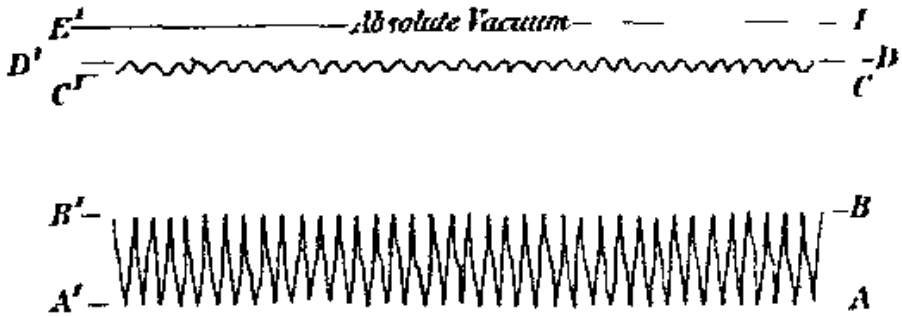

Fig. 53

From Barraquer showing tracings of vibrations by Prof E Gallemaerts. The lines A, B, C, D, A1, B1, C1 D1 and EE1 have been added for purposes of comparison with Fig 5 The position of EE1 has been calculated from the equation AB/AE = CD/CE and since AB = 8 mm , BC = 12 mm , CD = 15 mm therefore DE = 3 mm , approximately

quoted from Gallemaerts and we see that they represent the same thing, only that in the latter the intensity of the vacuum is not measured in absolute terms, but in terms of the difference between the air-pressure inside and outside the apparatus, *i.e.*, in Barraquer's original notation. Hence the two tracings are inversions of one another, with but one slight difference. In my diagram the frequency with which the " vibrations " occur is represented as the same whatever the intensity of the vacuum on the assumption that the pump maintains a constant speed throughout. Now this is not quite a reasonable assumption, for one might expect that there would be some difference in the load on the motor with a difference in the intensity of the vacuum against which it had to work—hence the speed at which it would drive the pump would vary too. This view is confirmed from professor Gallemaerts' tracings, for the ratio of the frequency of the " vibrations " at a high and a low vacuum is as 34.5 to 38, and is substantiated in the text, for on page 100 it is stated that: " In an Erisifaco that low voltage will operate because it has been constructed and arranged in accordance with the density and viscosity adequate for it. The number of the interruptions increases as the intensity of the vacuum is diminished by the regulator."

It is clear then that the " vibrations " or " interruptions " of the vacuum in the Erisifaco are present all right, though I have heard men deny that they exist. I think my explanation of how they are produced and of the way in which they vary is sound.

Now we must consider the claims made for these vibrations. Fig 54 represents an experiment alleged to have been performed by Prof. Esriche on which these claims are based. In Figs. 55 and 56 are reproduced diagrams from Barraquer's article to illustrate what is said to occur, and quote chapter and verse from the text in support of these diagrams. On page 90 the Figs. 99 and 100 represent two cataracts; the first extracted by an Erisifaco poorly regulated with insufficient altitude of vibration; the second shows a "correct" extraction. We note with the aid of a binocular immersion microscope the different lengths of its fibres and compare both with those of a lens removed with a pair of forceps (Fig. 92.) Opposite these diagrams I have placed some others in Fig. 55 which represent the reverse side of the medal, the state of the eye, as represented by Barraquer, after facoerisis, after Daviel's operation, and during expression of the lens by brute force applied from without. After the first there is a horrid mess, after the second all looks clean and tidy, the intact zonule hanging in a neat fringe from the ciliary body. But in the last of the three the artist seems to have made a slip of the pen. The lens capsule seems perfectly smooth and the whole of the zonule is depicted as remaining attached to the ciliary body just as after facoerisis. I have no doubt that Barraquer will correct this in the next edition of Dr. Fisher's book, for surely, in this method the zonule is torn out by its roots leaving the ciliary body in a sorry state—torn, harrowed, and bleeding!

We now have to deal with the instructions given for

Fig 55

Figs 92 99, 100 form Barraquer

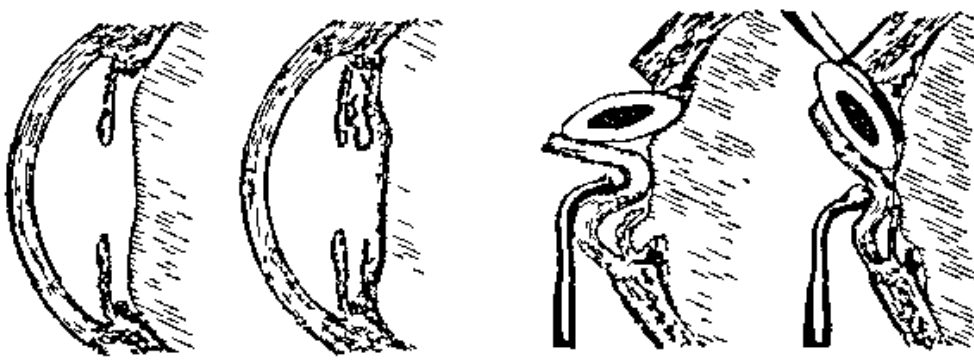

Fig. 56

Figs 38 and 28 from Barraquer

the regulation of the Erisifaco in practice. On page 58 we find: "The intensity to be used in each case varies between 50 and 70 cm. Hg according to the elasticity of the lens or the state of maturity of the cataract. These figures hold a certain relation to the age of the subject; the only thing that indicates the degree of vacuum to employ in each case is the practice of making preliminary and careful examination of the cataract—Fig. 110." Figs. 108 and 109 of Barraquer's article might equally well be referred to here, for the three represent respectively (*a*) a slit-lamp and corneal microscope, (*b*) a way of using them, and (*c*) what is seen with them. Then on page 104 we find: "The Erisifaco is a pneumatic forceps and zonulatome and ought to be kept perfectly regulated in accordance with the physical condition of the eye to be operated." It is clear that before we can begin to think about regulating the Erisifaco, we must understand the variations to be met with in the physical condition of the eye.

On page 82 Barraquer states: "With the cataractous process zonular fragility is increased; in myopic subjects the zonula are also more fragile than in emmetropes and hypermetropes. In zonula of individuals more than 40 years old the linear stretching amounts to only one milimetre which these fibres can stand, whereas in young individuals its elasticity is so great that the elasticity may be twice as much. A weight of 30 grams suffices to break the zonula in an emmetropic eye, more than 40 years old, whilst in the cataractous, this weight diminishes in

proprtion to the maturity of the cataract." This statement is not in accordance with Colonel Smith's experience, which is that the strength of the zonule decreases

Now for the influence of the type and stage of development of the cataract on the strength of the lens capsule. Barraquer states on pages 99 and 100: "A very hard cataract causes more deformity than a white one on account of the great necessity of a very intense vacuum, whereas a white soft cataract is deformed with more facility, and like that in the stage of intumescence the capsule is distended and drawn; a less intense vacuum causes an exaggerated deformity and may produce its rupture." Some hard thinking is needed to interpret this passage. To my mind the only construction it will bear is that the more nearly a cataract approaches the soft Morgagnian type the weaker is its capsule, which is in agreement with Colonel Smith's experience in as far as senile cataract is concerned. And I think that in connection with the strength of the zonule we can bring order out of chaos by assuming that Barraquer is confusing maturity with softness and in reality agrees with Colonel Smith that in a patient of any given age the softer the cataract the weaker is the zonule. .In short, the age in any given type determines the firmness of the anchorage of the lens.

Let us apply to these facts the basic principle which is claimed to underlie facoerisis, that the greater the "altitude" of the vibrations the nearer to the suction cup of the pneumatic forceps is the point at which the zonule is ruptured. It would be logical to extend the

application of this principle and to include the lens capsule in its range, assuming that with excessive "altitude" of the vibrations the latter and not the zonule would be ruptured. On page 59 Barraquer states: "As the intensity corresponds to the height of the wave, with insufficient intensity the fibres of the zonule do not rupture, with an excessive intensity we may break the capsule." To my mind the first sentence of this paragraph can only be taken to bear out my previous presumption—that with excessive "altitude" of the vibrations there is danger of bursting the lens capsule and not the zonule. Otherwise why was it included in the paragraph at all?

Now the plain commonsense view would be that a high vacuum is more likely to burst a weak capsule than a low one. Barraquer subscribes to this view frequently, both in the remainder of the paragraph—just quoted, in the paragraph quoted previously from pages 99 and 100 in which he gives his views of the physical condition of the different types of cataract and again on page 72, where he states that: "Rupture of the zonule may occur at the moment the cataract is drawn upon, indicating that we have made a mistake by employing a vacuum of excessive intensity." But it is puzzling when one tries to reconcile this commonsense view with the vibratory theory. For I have previously shown that the correspondence of the intensity is, measured in Barraquer's notation, a correspondence in inverse proportion. *The two aspects seem irreconcilable.*

Finally, we must consider the adjustment of the intensity of the vacuum and the "altitude" of the vibra-

tions to the strength of the zonule. We are agreed that in a patient of a given age the strength of the zonule decreases *pari passu* with the softness of the cataract. It would again be only plain commonsense to agree that with a strong zonule, in a hard cataract, the suction cup of the pneumatic forceps ought to have a firmer grip than with a weak zonule, for it would be more liable to come off when we pulled. Barraquer again subscribes to this view frequently, to requote from pages 99 and 100: "A hard cataract causes more deformity than a white one on account of the great necessity of a very intense vacuum," from page 101: "The surgeon ought to try to regulate the intensity of the vacuum in proportion to the hardness of the cataract." But again there comes a difficulty in fitting this in with the vibratory theory. For, with a very intense vacuum the "altitude" of the vibrations is nil, with a low degree of intensity they are at their greatest. How does it come about that the stronger the zonule the weaker, on this view, are the vibrations suited to its rupture, the weaker it is the greater must be their amplitude? One seems to catch a glimpse of Barraquer himself being a little perplexed about the matter, for in the second paragraph on page 100 he seems to contradict his instructions which immediately precede and follow. He states: "When the cataractous process is less advanced as a rule the zonule is less friable, which necessitates the employment of a greater number of interruptions of the vacuum. In an Erisifaco the number of interruptions *increases as the* intensity of the vacuum is diminished by the regulator,"

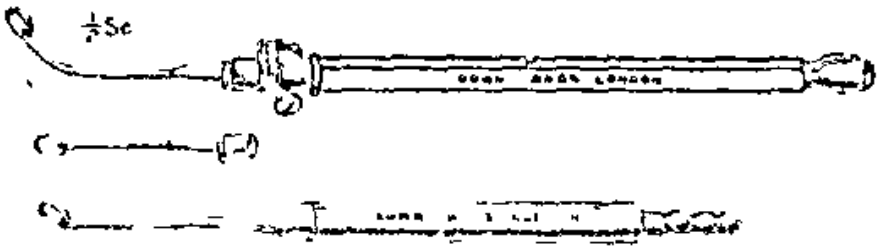

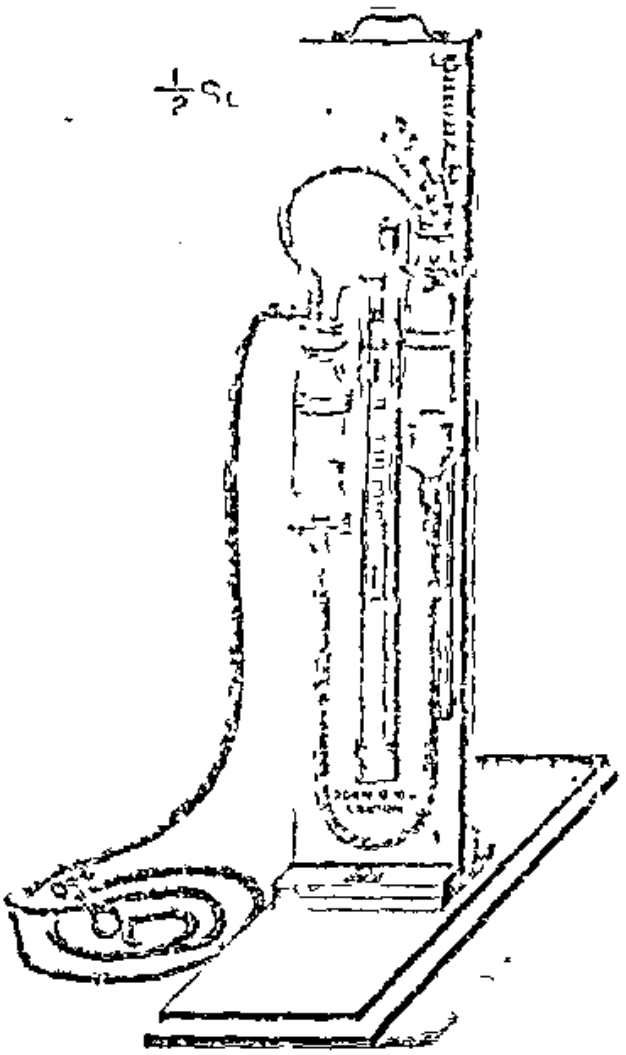

Fig. 67

Down's Mercury Vacuum Apparatus

i.e., the machine moves faster as the load is diminished. In fact within the space of twenty lines of print he first recommends a vacuum of high intensity for the extraction of a cataract whose zonule is tough, and in consequence low "altitude" of vibrations, then the reverse, and finally returns to the original instructions. But I am sure Professor Barraquer will be able to explain these apparent inconsistencies to my satisfaction. I have been unable to study his writings in the original Spanish text, and the explanation must lie in errors which have crept in during its translation into English.

So much for the theoretical aspect of facoerisis. I was fortunate enough to have been able to study its practical aspect during the last winter, when I had the opportunity of visiting and working at a number of clinics in Northern and Western India, where intracapsular extraction of cataract is performed on an extensive scale. I have seen in action most of the methods which are before the profession at the present time, including the "pneumatic forceps" with both Down's mercury vacuum apparatus (Fig. 56) behind it and Barraquer's latest type of outfit. The men whom I saw at work were very highly skilled in the technique of expressing the lens in its capsule by pressure from without, and had the experience of some thousands of cases to their credit. They had acquired by long practice a lightness of touch and a dexterity in the manipulation of their tools which is to be gained in no other way. Yet at the time at which I saw them at work with the pneumatic forceps they were having one disastrous accident after another.

With Down's mercury vacuum apparatus there was such a violent rush of air through the anterior chamber, if the suction cup was misapplied to the lens when the vacuum was transmitted to it, or if the zonule was so strong that it lost its hold and came off when they pulled, that the lens was blown straight back into the vitreous, to be recovered with difficulty if at all. The control of the vacuum was in the hands of an assistant who pressed a spring clip on the rubber tubing to transmit it to the suction cup when the word was given. He had instructions to shut it off at once if he heard the hiss of air entering the suction cup. But before he could possibly have time to do so a quantity of vitreous had been sucked into the apparatus, and could be seen in the watery fluid which gradually accumulated on top of the mercury in the vacuum chamber. I suggested to the surgeon concerned that, if his assistant released the spring clip at once when he had pressed it and transmitted the vacuum to the suction cup, the latter would keep its grip on the lens just as well as if it was still in communication with the vacuum chamber. If it came off during the subsequent manipulations, air would only enter in small amount to fill up the tubing as far as the clip, not in the great rush which was inevitable with the way in which he was handling the apparatus at the time. When he tried this he found it to be the case. When the zonule was too strong for the grip of the suction cup no disasters ensued when it was pulled off the lens. But this initial stage is not the only one at which its grip can fail. I saw it do so more than once even after the lens had been

dislocated. When it did so the vitreous, which was sucked into it, was now held up at the clip, and instead of passing over into the vacuum chamber streamed out from the handpiece on its withdrawal, like a thin watery jelly, in full view of the audience.

Barraquer's pump does not suck air in through the open spoon as fast as does the mercury vacuum apparatus. With it there is in consequence less danger of the lens being blown back into the vitreous if things go wrong. The accidents I saw with it were a little less frequent and a little less violent. But despite the addition of the vibrations the log book still showed a sorry tale of woe. Burst capsules I exclude from consideration, for they were clearly due to faulty diagnosis and regulation of the apparatus, not to lack of manipulative skill. But there was to my mind a prohibitive proportion of cases in which the lens had to be dug up out of the vitreous with a spoon, or was lost not to be seen again.

The situation puzzled me. For though a man might publish that he had failed a thousand times with the Erisifaco, he would still have to face the fact that Barraquer himself can do the job with it perfectly. Everyone who has seen him at work, either in Barcelona or elsewhere is agreed that in his hands all goes like clockwork. What one man can do another should be able to do. Yet here were men making a complete hash of the job, over whose skill and experience I will not grant Barraquer the right to claim any superiority. I tried my hand on a few cases with Barraquer's apparatus

and had no more success than the others. The mystery deepened, though once I thought I saw the glimmer of a solution in that ancient maxim: "The diagnosis first and the treatment afterwards." It might be that the diagnostic armament was at fault. We had to rely on the unaided powers of observation of the naked eye, for there was no slit-lamp at hand to help us.

I had had for long suspicions about the accuracy of some of the statements made in Barraquer's article and had failed to confirm certain of his findings, and a chance remark coupled with statements in an article by Capt. Cruickshank, I.M.S. (*Brit. Jl. of Ophthal.*, July 1925) gave me the clue to what seemed the solution of the problem.

Are the vibrations, such as they are, responsible for the zonule being ruptured close to the periphery of the lens when it is extracted by facoerisis, and is it dragged out by the roots from the ciliary body, as is implied to be the case, in other methods of extraction? The whole of the claims for facoerisis have been built on the hypothesis that both these things occur. It is not sufficient for Barraquer to demonstrate the truth of the former alone, he must also demonstrate that of the latter. Now since the earliest days in which Colonel Smith began to express cataract in its capsule by "brute force" this question of where the zonule gives way has interested him. He always showed visitors to his clinic that no trace even of tags of the zonule were visible on the capsule, however examined; much less, the veritable halo which Barraquer would have us believe should have surrounded the lens.

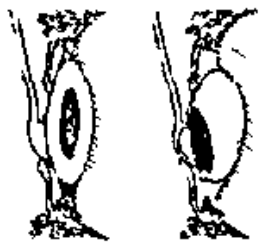

Fig 58

(Fig 57 from Barraquer)

Barraquer's representation of effect of applying vacuum, *i e*, immediate dislocation of the lens in *all* cases, and the nucleus being gripped by the suction cup *through an intact capsule*

Early in 1921, on a visit to Barcelona, both Barraquer and he extracted a lens by their respective methods. The elder Professor Fuchs (late of Vienna) who was present, examined and said : " In the hands of the two experts I see nothing to choose." I have yet to meet anyone who can demonstrate any difference, in the matter of the presence of tags of zonule, between senile cataractous lenses, extracted in their capsules from the living human eye, which is in any way dependent on the method by which they were extracted.

The inconsistencies present in Barraquer's own account of how to " regulate " the vibrations in accordance with the physical conditions in the eye to be operated on should be obvious. He is convicted out of his own mouth. For on page 96 he says that when he operated with a constant vacuum he " ruptured the fibres of the zonule to extract the lens which then appears with a crown of zonule fibres like the representation in Fig. 92." This diagram (which has been reproduced in Fig. 55) shows the lens with what clearly is intended to portray the whole zonule attached to it. Yet in the very next sentence he tells us that " by examining those patients with the corneal miscroscope it was noticed that, in some, remains of zonule fibres are incarcerated in the lips of the wound." I need say no more. The vibrations, such as they are (for as a matter of fact they hardly exist at all,) have absolutely no influence on the place at which the zonule ruptures.

There is one other aspect of the action of the vacuum in dislocating the lens which deserves attention. Repro-

duced in Fig. 58 is a diagram which figures repeatedly in Barraquer's article. It purports to show how the lens is dislocated immediately by the application to it of the vacuum and vibrations. One point about it at once strikes the eye as queer—for though the lens capsule is intact, the nucleus is portrayed as being displaced through the soft cortical matter towards the suction cup and gripped by it. In the text (page 57), the representation is confirmed : " By the rarefaction of the air in the suction cup, it adheres to lens. . . . deforms it by shortening its greatest diameter *and displaces the nucleus.*" A simple experiment with fresh human cataractous lenses will serve to convince us that this unlikely happening does not in fact take place. The capsule and as much soft fluid cortex as it will hold is sucked into the suction cup. If the nucleus is large and the cortical matter small in amount the capsule is drawn tightly round the former. If the cataract is of the Morgagnian type, the small nucleus sinks to the bottom of the fluid in the bag in which it is contained. Applying these facts to consideration of the sequence of events inside the eye, we see that the only effect of the application of the vacuum is to take up a little of the slack in the anterior lens capsule. What happens then depends on the circumstances (Fig. 59) for this by itself will only effect dislocation if the zonular attachment is very weak. If it is strong the moorings of the lens will not part until the strain on them is increased by pulling or pushing, and when they do part they will do so at their weakest point, vibrations or no vibrations. On the other hand the capsule may

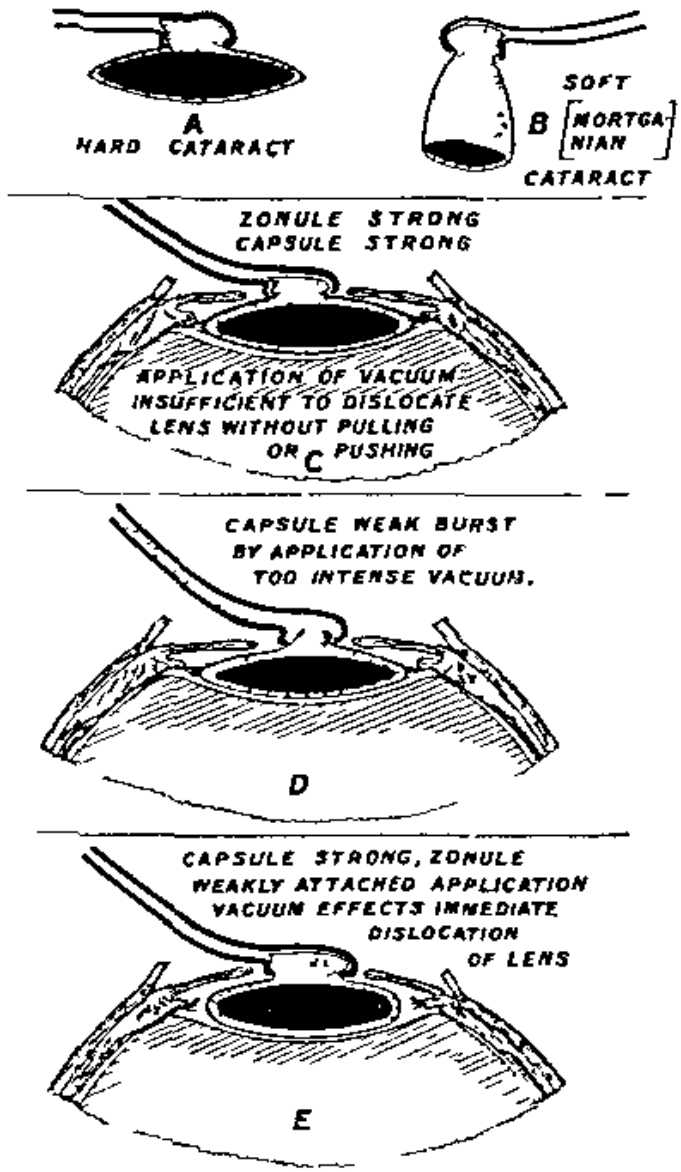

Fig 59

Representation of actual sequence of events when vacuum is applied.

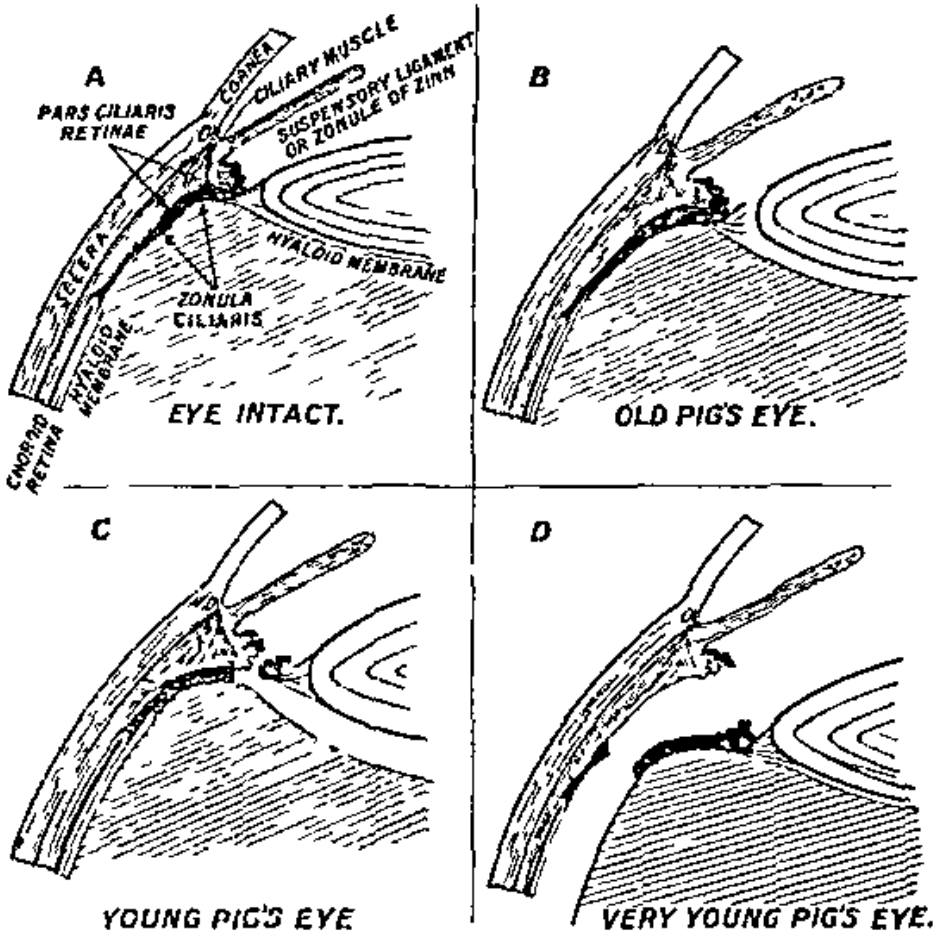

Fig. 60

Natural planes of cleavage in the structures which anchor the lens to the fibrous coats of the eye.



Fig 61

(Fig 102 from Barraquer Compare with Fig. 14 D)

I must compliment Barraquer on the skill with which he has dissected the ciliary epithelium off the zonule ciliaries of the hyaloid membrane, feat which I have not been successful in repeating myself

burst, if it is weak in relation to the intensity of vacuum employed, the suddenness with which the latter is let on, or the sharpness of the edges of the suction cup.

An experiment on the eyes of young animals fresh from the slaughter house (pigs' eyes are very suitable) gives us interesting information as to the situation of these weak links in the chain which moors the lens to the fibrous tunic of the eye. (Fig. 60.) The age of the pig may be estimated roughly by the size of the eye. Make a section which admits of an easy passage for the exit of the lens. Punch it out boldly by pressure applied from the outside so as to bring it out upside down. In the eyes of the older animals the zonule can be seen to strip off the capsule of the lens and leave the latter quite smooth and bare. In younger animals the zonule comes with the lens, but brings with it a narrow black pigmented fringe consisting of that part of the epithelial covering of the ciliary body (the pars ciliaris retinæ) which overlies it and to which it is attached. In the youngest animals the continuation of the zonule back into that thickened portion of the hyaloid membrane which is termed the "zonula ciliaris" is so strong that the whole hyaloid and vitreous come with the lens. With them is brought the whole of the pars ciliaris retina, which encircles the lens, as it sits on the vitreous, like a broad black halo. It is simple to cut through this halo into the canal of Petit and to extend the cut right round the circle. The lens peels off the vitreous and the hyaloid membrane which lines the patellar fossa is clearly displayed.

I should warn the reader that the pig's eyes must be fairly fresh, for in the process of decomposition the attachment of the zonule to the lens capsule is the first place to be weakened.

Now though Colonel Smith has more than once been successful in expressing cataract in its capsule in children, yet, in them the zonule is as a rule so firmly attached to the capsule that he has long since given up doing it as routine. It is not because he is afraid that the pressure required, which is considerable, would be injurious to the structures inside the eye. Nothing of the sort is the case. Nor is it because he has seen the lens bring with it a black halo of epithelium off the ciliary body as in the case of the young pig's eye. It is because in most cases the pressure required is such that it is difficult to prevent the instrument from plunging, when the zonule loses its hold, and so expressing a quantity of vitreous with the lens. In very rare cases of cataract in childhood the lightest touch will suffice for dislocation, but they are so rare as to be a curiosity, impossible to diagnose before operation.

Knowledge of these facts led me to think more than once over a chance remark by an American surgeon who had just visited Barcelona. He had seen Barraquer take out a congenital cataract in a child "perfectly." The whole tone of his remark gave me the impression that Barraquer had laid his hand to that child's cataract without the quiver of an eyelash, absolutely sanguine of success, and had regarded it as just an ordinary everyday-routine event. Now, what I had seen of the "pneuma-

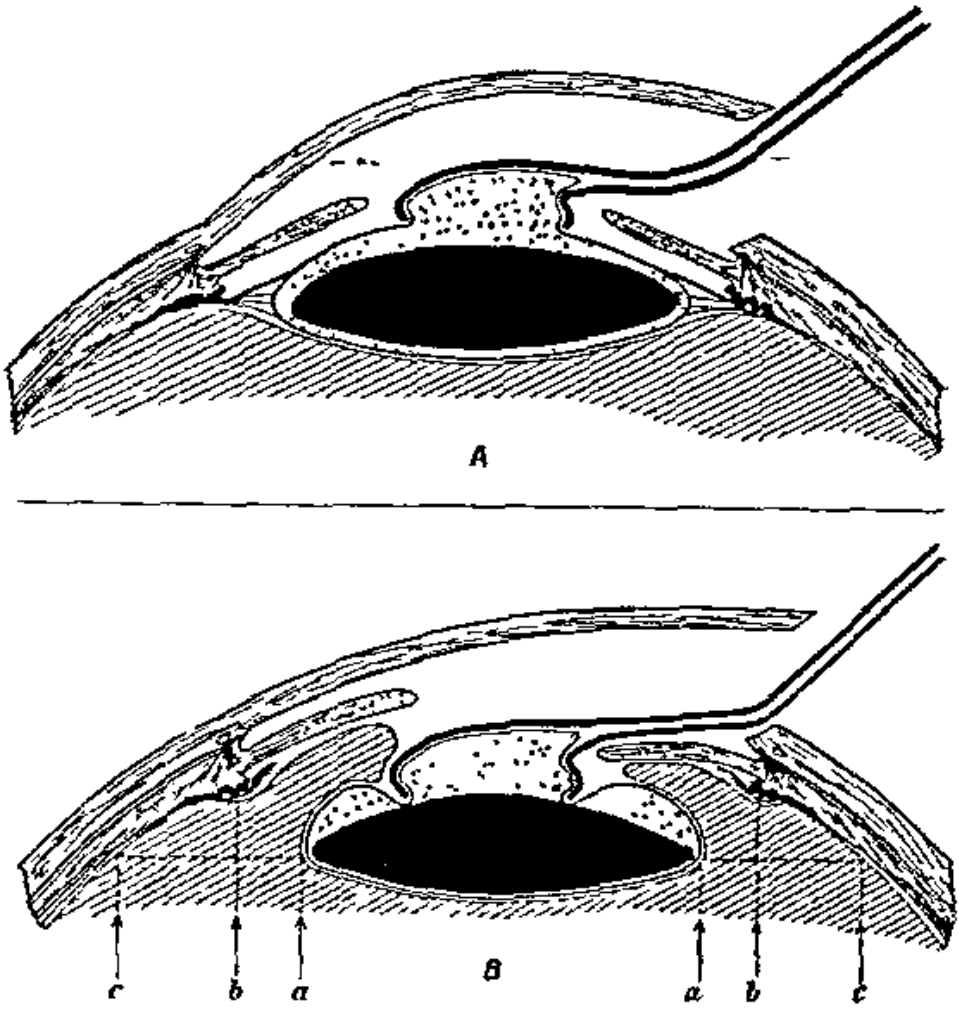

Fig 62

In A the suction cup has gripped the lens, but the zonule is too firmly attached for dislocation to be effected by pulling In B, the lens is shown pushed back quite a short way into the vitreous, which has burst its way forwards, through the hyaloid membrane and the zonule, but does not come in front of the plane of the iris, as there is no pressure on the outside of the globe to make it do so Note two things First the extra space given by this manoeuvre both from side to side (c b), and from front to back behind the cornea, second the way in which the shaft of the pneumatic forceps is set at an angle of 45° to the transverse axis, lying in the plane of the suction cup about which the lens must be rotated

tic forceps " in action had convinced me that, even with the machinery behind it in perfect working order, its grip was inadequate for the removal of any but the most *lightly* anchored senile cataract by pulling. For I had frequently seen it lose its hold and come off when the zonule was but a little over the normal in strength. Yet here was Barraquer achieving success with a cataract whose anchorage was ten times as strong as that of any on which I had seen his instrument fail. It became clear to me that his success in that case could not have been achieved by pulling. He must have dislocated the lens by pushing it boldly back into the vitreous, a course which would impose no strain on the grip of the instrument which it was not fit to stand. The vitreous would press well forward round the periphery of the lens to fill the space vacated by the latter. But there is no reason why it should do more than this, why it should come forward in front of the iris, or come out of the eye. For Barraquer applies no pressure to the outside of the walls of the globe to deform them, and so to reduce the capacity of the vessel in which the vitreous is contained (Fig. 62.)

I then recalled to my mind the article before mentioned, by Capt. M. M. Cruickshank, I.M.S., who has, I believe, been up to the present the most successful exponent of the art of facoerisis in the Indian Empire. He himself seems to believe firmly that he is getting the lens out by pulling. But his instructions as to how to avoid disaster display plainly, when read between the lines, that he is actually doing nothing of the sort. Labour-

ing under the misconception, whose fallacy I have already pointed out, that the suction cup actually *grasps* the *nucleus* through the capsule, he goes into an elaborate explanation of why the surgeon must not attempt to turn the lens over on its back inside the eye before extracting it, by simply rolling the handle of the pneumatic forceps between the thumb and fingers. In it, however, he seems to have missed the real reason, which is that while the lens must be rotated about a transverse axis which lies in the plane of the suction cup, the shaft and handle of the instrument are set at an angle of about 45° with that plane. This at one and the same time gives the surgeon a leverage which enables him to apply immense force to the lens without realizing it, and compels him in using the instrument to swing the handle about that axis by movements of pronation or supination of the wrist and forearm. When one sees superadded to this, movements of the elbow and shoulder joints, with perhaps the hand not even steadied on the patient's head, one realizes that under these conditions the sensations of the finger tips will by themselves be a poor guide as to what is happening at the business end of the pneumatic forceps. And even they are blunted by the fact that it is necessary to grip the instrument the whole time in order to keep the valve pressed which transmits the vacuum to the suction cup. I was told by one man, who previously had been very successful, that there was some trick in the use of the instrument which his hand would take a little time to re-acquire, but which he could not explain in words. The reason

for this difficulty in explanation was simple enough. He was under the impression that his fingers had been pulling on the lens while in reality they had been pushing.

Let us re-examine Barraquer's diagrams and his instructions for manipulating the pneumatic forceps in the light of the hypothesis that the secret of safety and success with it lies in using it to remove the lens as much as possible by pushing, as little as possible by pulling, because its grip is inadequate for the latter course. We shall find that it gives us a rational explanation of how he has arrived at his present method of "tumbling" the lens so as to deliver it lower edge foremost (page 63, "My Usual Method").

In Cruickshank's article it is said that during the final stage of delivering the lens in this way it must not be pressed against the posterior surface of the cornea under the impression that by doing so any tendency for the lens to slip, or be dragged off the suction cup, as it engages the incision, can be prevented. The natural inference would be that such an accident, among others, would thereby be made more, not less, likely to happen. If the smooth posterior surface of the cornea can form such a serious impediment in the way of safe delivery, how much more serious an obstacle must be presented by that sharp scleral lip of the wound when the lens is brought out head first. Accidental pressure with the lens against it is a thing which is not unlikely to happen in that method of delivery. For in it the suction cup remains in front, the lens behind against the scleral lip, during the actual passage through the wound.

This is not the only way in which the scleral lip is an awkward corner to negotiate during the upright delivery with the pneumatic forceps. The cohesion between the posterior surface of the lens and the vitreous, two smooth moist surfaces perfectly adapted to one another, is such that, if an attempt is made to separate them by pulling the lens straight forward, the vitreous will tend to stick to it and hold it back. The grip of the suction cup may be inadequate to the task of pulling them apart in this way. It may lose its hold if asked to do so. Then as we have seen trouble begins. The lens must be disengaged from the vitreous by swinging it round on a transverse axis so as to slide apart the two surfaces in contact. (*See* Fig. 63, A and B, that is, Fig. 33 from Barraquer in which he himself recognizes this fact.) In upright delivery the nose of the lens may strike against the inner surface of that scleral lip of the wound. It will stay behind unless it is lifted over the stile by pulling it forward, and pulling is gambling with fate. (*See Fig. 64.*)

Finally, we can see from Barraquer's own account, that even the intact iris presents an obstacle to upright delivery, which he may not be able to surmount. For in that method the instrument must be asked to pull the lens through the pupil and it is more than likely to jib at the task. This is the only reason which I can see for his statement under Fig. 31 of his article: "In cases of hard cataract total extraction succeeds only and invariably with an iridectomy." The picture represents a cataract being delivered upright in its capsule, impaled

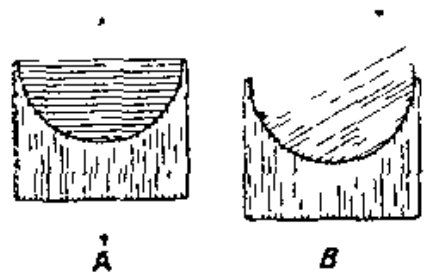

(Fig 6)

(Fig 6) from Barraquer)

"In A, by making pressure in the direction of the arrows adhesion prevents us from separating the convex lens from the concave if the two have identical curvature It is necessary to disarticulate them as in B, to accomplish a movement of rotation"

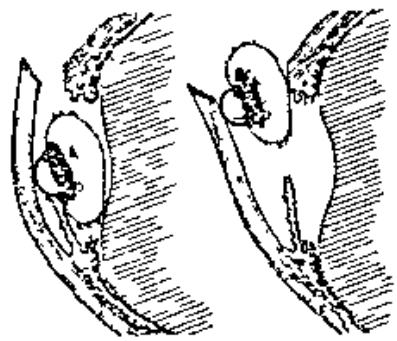

Fig. 64

(Fig. 64 from Barraquer.)

Showing upright delivery. Note how the lens is represented as being *pulled* forwards off the vitreous in order to clear the awkward projection of the scleral lip of the wound. Yet Barraquer himself in Fig. 17 demonstrates the difficulty of so doing.

on a needle. I have no experience of this particular method but in so far as simple straightforward expression from without is concerned Barraquer's statement is entirely untrue. With it there is no difficulty whatever in pushing the lens through a pupil contracted to a pin point with opium; it is only a matter of patience. Again on page 53 he says, "If it is a question of a more voluminous cataract, very intumescent, an iridectomy is indicated."

The secrets of success are now plain. Any lens can be dislocated with perfect safety by pushing it boldly back into the vitreous. Once dislocated "version" can be done without fear of accidents, by working back in the vitreous where there is plenty of room. (*See* Fig. 62B and note on page 20 of Cruickshank's article, the warning against striking the lower edge of the lens against the sclero-cornea.) Once the suction cup is behind the lens it can be disengaged from the vitreous and got through an intact pupil by *pushing instead of pulling*. And, finally, when it has got into the anterior chamber it can be negotiated round that awkward corner formed by the scleral lip of the wound with the back of the suction cup against it instead of the back of the lens.

There is one point which requires emphasis, the matter of making sure that the lens is completely dislocated before beginning to do the version. When I re-examined, in the light of the hypothesis of pushing instead of pulling, the events in the very few cases on which I had used Barraquer's instrument myself, the reasons for my success and failure became apparent. I

had been successful with the hard cataract and had failed with the soft (burst capsules are here expressly excluded from consideration, as they are a matter of faulty diagnosis rather than faulty manipulation).

I had started on a movement of pronation of the forearm as soon as I had got hold of the lens, so driving its upper border back into the vitreous. In the former type the pressure I was making unawares on a rigid body had dislocated it below as well as above and all went well thereafter. In the soft cataract the suction cup simply slid over the small nucleus, which was floating in fluid cortical matter, and the zonule remained attached below. Then when I tried to swing the lower edge of the lens up through the pupil I had to begin pulling. There was a tug-of-war between the zonule and the suction cup in which the former had the mastery. The cup came off and the lens dropped back into depths of the vitreous from which it had to be dug up with a spoon.

Here is the point at which to draw attention to Barraquer's Instructions on page 71: "In case the iris gets between the lens and suction cup. It suffices after having given the lens the turn within the anterior chamber to interrupt the passage of the vacuum allowing entrance of the atmospheric pressure into the suction cup by which the cataract is loosened and to take hold again." Now while this course is quite feasible if the iris is caught up in the suction cup above or at one side, it is not possible if it is caught up below. For then the lower border of the lens cannot be swung up through the pupil; the cup comes off; and the lens is lost.

The moral to draw from this is that the surgeon who uses the pneumatic forceps should be particularly careful not to ensnare the iris below and should always commence by dislocating the lens below, pressing it backwards there by supinating the forearm, then turn his attention to the zonule above, detaching it there by pressing backwards with a movement of pronation. Only when he is certain that the lens is completely dislocated should he begin to do the version. While doing it, in the words of Capt. Cruickshank, he must not attempt to steady an unruly eye with the instrument. He must be in no hurry whatever, but must exercise his patience and go dead slow from start to finish. And above all his hand must not tremble. For if he does any of these things he may inadvertently strike the lens against one of the numerous obstacles which lie in its path, and drag it off the suction cup. If it slips off after it has been completely detached from the zonule, there is nothing to prevent it from dropping back into the depths of the vitreous, never to be seen again. For the hyaloid membrane, lining the patellar fossa, has been torn to shreds and can give it no support from the rear.

Having formulated this hypothesis I put it to the test of practice on embedded pigs' eyes. To my joy I found everything go smoothly. After a time I became wildly enthusiastic over the merits of the pneumatic forceps for it became clear to me that could I lay my hand with it to a congenital cataract in the eye of a foetus as yet unborn, there would be but one thing which would baulk me of my prey. Should the subject

not have reached the stage of development at which the remains of the hyaloid artery have disappeared I would have to start pulling in order to rupture them, and that would be fatal to success. And I would be a little apprehensive that in the event of success the lens might emerge crowned with an artistic black halo of epithelium off the ciliary body. For the weakest link in the chain which moored it to the fibrous tunic of the eye would be the one which would give way, vibrations or no vibrations.

I think it is fairly clear that Barraquer's instructions are not likely to assist his would-be disciple in succeeding with his method. Turn to the "Advice to the Beginner," on page 103. Section 5 enjoins him: "Do not in your first operation try to change in the least possible way the details of the technique described, and be most exact in following them out." If the beginner wishes to succeed in his first operation he must depart radically in every particular from the technique described, from the very first step to the very last. On page 49 a section "including the superior 2/5 of the cornea" is recommended. It is next door to impossible to express cataract in its capsule by pressure from without through a routine incision of this size—the minimum safe standard is half of the corneal circumference, or 180°. With the bulk of an instrument added to that of the lens, 190° is the minimum, when that instrument has as light a hold as has the pneumatic forceps, 200° would be better. This was the size of incision which was being made by the most successful of the men whom I saw at work with

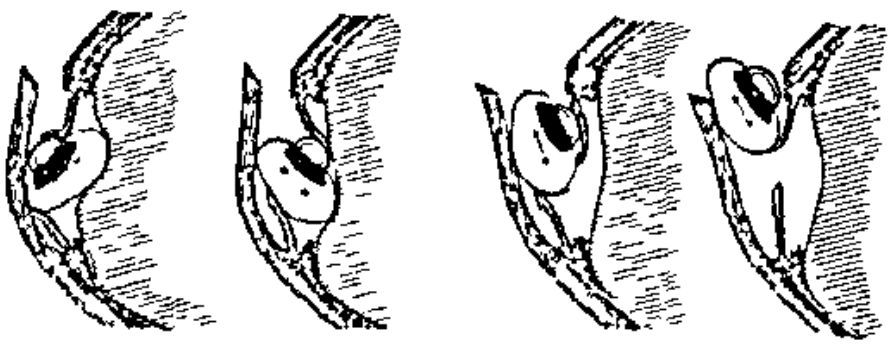

Fig. 65.

(Figs. 73 and 74 from Barraquer.)

Delivery as a Tumbler. Note how Barraquer represents the lens as being rubbed against the cornea from start to finish.

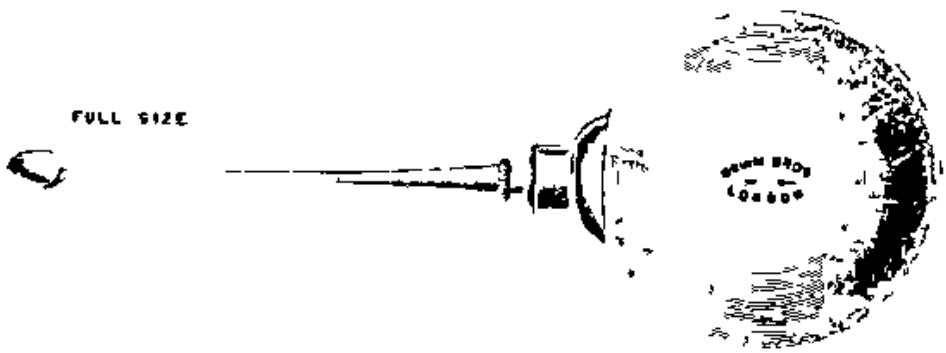

Fig 66

Pneumatic Forceps of Stoewers (1906).

it. (In Capt. Cruickshank's article the same thing is emphasized, though perhaps not so explicitly.). It is quite a safe size in so far as the vitality of the cornea is concerned.

Barraquer repeatedly utters a warning not to make any pressure with the instrument on the lens, not to compress the vitreous and in his diagrams he represents the hyaloid membrane as remaining intact to the end, the vitreous as undisturbed. I do not need to deal with this again. In his illustrations of how he delivers the lens as a " tumbler " (*see* Fig. 65, that is Figs. 73 and 74 from Barraquer) he depicts it as being rubbed against the inside of the cornea from start to finish. I have already quoted Cruickshank's views on that issue but Barraquer himself sheds an interesting sidelight in it. For on page 59 we find a warning not to " produce friction on the posterior of the lens." It is interesting to note that in this passage it is the vitreous, not the lens, for which he is displaying great concern.

Finally, there comes the matter of escape of vitreous. He claims immunity from it on page 74 and both here and on page 74 ascribes this immunity to the use of novocaine to paralyze the orbicularis. Though elsewhere he does allude to the fact that the lids should be held away from the eye, yet he does not tell us whether his assistant who is looking after them is charged with the duty of retracting the eyebrow to guard against the very real danger of the novocaine failing to act.

The pneumatic forceps was as far as I know first introduced into surgery by Stoewers. For an instru-

ment bearing his name figured in Messrs. Down Bros. catalogue for 1906. The next man to take it up was Dr. Vard Hulen of San Francisco, who reported six cases in 1910. Professor Barraquer deserves great credit for the thought and energy which he has brought to bear on the problem of how to use it. But I do not think we can allow his claim to pass, that his instrument is a "vibratory zonulatome" possessed of magic powers, and that his operation consists "in drawing the crystalline lens by its anterior surface, separating it mechanically without either traction or violence of the zonule, and extracting it completely out of the eye without having produced ectopias or traumatism of the intraocular structures." I should like to rechristen the operation and call it "pushing the lens violently to the exterior."

E.—*The Correct use and Construction of Capsule Forceps, and their Application to the Problem of Removing Cataract in its Capsule from Young, Adult and Juvenile Patients.*

In senile cataract the recent developments of the Indian method render the use of capsule forceps, whether of the Kalt (mechanical) or of the pneumatic type, not only unnecessary but inadvisable. The manipulation of these instruments calls for a higher degree of manual dexterity, than does that of the squint hook and spatula; and in senile cataract they present no advantages to compensate for their dangers. It is very easy with them to dislocate a lightly anchored lens before a grip is obtained on it, while the merest touch with a metal instrument

is liable to burst the fragile capsule of the swollen Morgagnian type of cataract. In the case of more firmly anchored lenses it is more than likely that a piece will be torn out of the capsule without effecting dislocation, when traction is alone employed for this purpose as has hitherto been the practice. The addition of pressure from without with a lens hook helps matters if it is properly applied, but removes the *raison d'etre* of the instrument inside the eye, for in senile cataract the job can be done quite simply without it.

In view however of the fact that until very recently the use of some form of Kalt forceps has been the only practicable method of extracting cataract in the capsule which has been at the disposal of the profession in the West, and that it may take some time for those who are already using such forceps to bring themselves to dispense with them, it will be as well just to deal briefly with the correct construction and the correct method of using these instruments. In the first place they should be of the double cross legged type as used by Dr. Sinclair of Edinburgh, which automatically maintains its grip of the capsule once this has been obtained.

It goes without saying that the lens must be tumbled. Traction alone must not be relied on to dislocate it—pressure with an instrument applied to the sclerotic below must be called to our aid as a routine. The best instrument for this purpose is an ordinary lens hook, whether the front or the heel is used is immaterial as either of them is small enough to concentrate the pressure on a small area. The hook should be swept up

from the lower fornix so as to make sure that it is below the lens, for if it is applied near the sclero-cornea in the first instance it is very liable to be in front of the lower pole of a large lens (much as in Fig. 43, A), in which case it will be working at cross purposes with the forceps inside the eye. Finally there must be some means of applying counter-pressure over the upper pole of the lens to prevent it from dislocating at the wound, with consequent loss of vitreous as in Fig. 41, A.

This can best be done by constructing the forceps with bent jaws so that the part which is pressed into the eye lies roughly at right angles to the shaft of the instrument, while a small flange passes backwards and outwards from the bend of each jaw. The instrument is passed into the eye from above through the middle of the wound, and the capsule is grasped as low down as possible. By tilting the shaft back towards the brow the flanges are brought into the contact with the wound and keep the upper pole of the lens in position as its lower pole is levered forwards. (Fig. 67, A.) Once the lens has been dislocated here the hook is used to insinuate the cornea behind it by pressure from without. (Fig. 67, B.) As time goes on the operator will undoubtedly find himself doing more and more pressure with the lens hook outside the eye and relying less and less on traction with the forceps. He will pass first through the stage of removing this instrument, as Knapp does, immediately the lens has been dislocated, and will finally come to dispense with it altogether and take to using the spatula

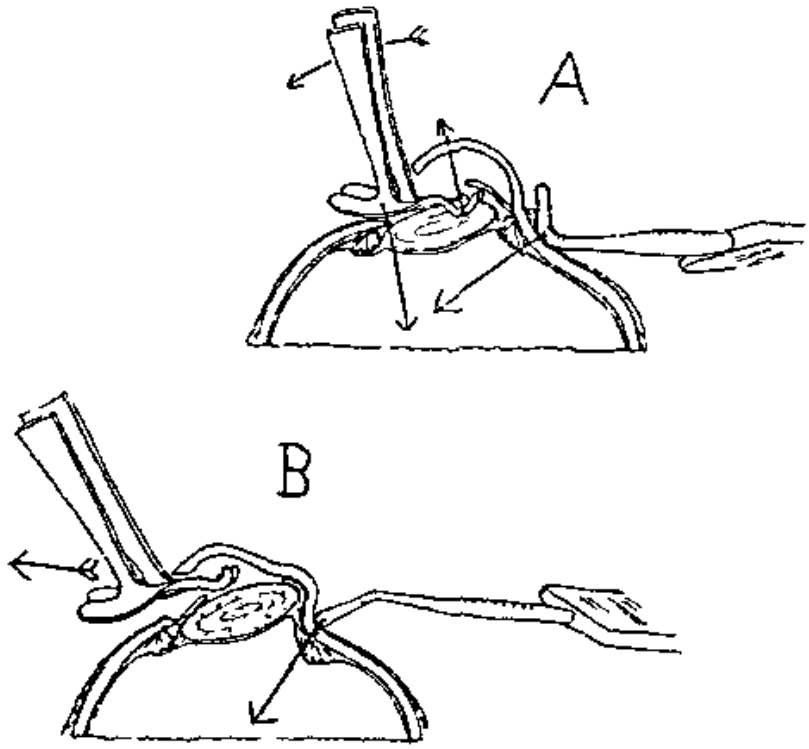

Fig. 67

Use of the Capsule Forceps.

A.—The capsule has been grasped near the lower pole of the lens. By tilting the handle of the forceps back the flange is pressed on the upper pole of the lens and keeps it back while its lower pole is levered forwards. The bent lens hook is shewn applied over the ciliary region.

B.—The zonule has given way below, the lens has tumbled up, the forceps are taken off, removed, and delivery will be completed with the hook alone.

over the wound as described on a preceding section and as depicted in Fig. 42.

Consideration of the technique of "Facoerisis" teaches us a valuable lesson in the use of capsule forceps in those cases in which their assistance really is required, *i. e.*, cataract in young adult and juvenile patients, which is outside the range of the Indian method of expression from without. Though the capsule in these cases is strong, the zonular attachment is stronger still, and pulling on the capsule will only tear a piece out of it. But the lens can be dislocated with perfect safety by pushing it back into the vitreous—if pressure on the outside of the eye is dispensed with, there will be no loss of vitreous. For this purpose the forceps must be constructed with a smooth back, as broad as possible so as to distribute the pressure evenly over the surface of the lens. The surgeon has the choice of two techniques. He may dislocate the lower border of the lens only, bringing it up again out of the vitreous so that the coats of the eye can be invaginated behind it with a squint hook from the outside. It is then expressed as a tumbler after removing the forceps. Or he may adopt Barraquer's method, and, dispensing with pressure from the exterior, push the lens bodily backwards, turn it upside down, inside the eye and push it forward through the pupil with the instrument behind it.

F.—*Daviel's or the Capsulotomy Operation.*

The general principle in Daviel's operation has remained the same since its inception. The modifications which have been suggested since his time are of

trifling importance, consisting as they do merely of some change in the form of instruments, or some alteration in the method of squeezing out the nucleus and getting rid of the lens matter. But their very multiplicity together with the fact that not one of them has been universally adopted are an indication that ophthalmic surgeons the world over have been dissatisfied with the results they have been getting, though they may not have had the courage to say so in public. They are some of the straws which show the way the wind is blowing, others of which are the numerous abortive attempts throughout the history of this operation to break away from it and to perfect a technique for extraction in the capsule.

The principal points in the technique of Daviel's operation can be dealt with very briefly.

(1) *Control of the lids and orbicularis.*—There is not the same necessity for thoroughness in this as in intracapsular extraction, and the speculum may be retained throughout the operation. But every ophthalmic surgeon should be familiar with the way to control the lids and have his assistant trained to do it properly. Otherwise when complications arise he will be unable to deal with them with the necessary ease and deliberation.

(2) *The Incision.*—I have dealt with this before. It is an advantage to have it ending in the sclero-cornea, in order to facilitate expression of the cortical lens matter, and to make a conjunctival flap, in order to seal over any tags of capsule which may become incarcerated in the wound. The size of incision recommended in the

text-books for senile cataract is one-third of the corneal circumference. This should be extended to at least two-fifths, and there would be many advantages in making it the full half circumference. For there would then be no necessity to enlarge it in order to deal with such complications as dislocation of a hypermature lens with the capsulotome.

(3) *An iridectomy or no iridectomy.*—A complete iridectomy is in my opinion necessary to enable us to squeeze out the cortial lens matter properly, apart entirely from any question of prolapse. This is not so frequent as after the intracapsular extraction since the iris often gets stuck down to the after-cataract by adhesions before the wound ceases leaking.

(4) *The Capsulotomy.*—The best method is to insert a pair of curved iris forceps milled to the angle into the anterior chamber with the points beyond the lower margin of the iris and behind it, open them wide and take a large grasp of the anterior capsule and bring out what is in their grasp. In this way a large piece will be torn out of the anterior capsule which will leave no tags to flap loose and be carried into the wound, there to act as a drain and keep it open. It will also tend to make the after-cataract less dense. The disadvantage of this method, to a man who is not ready to deal with emergencies, is that if the patient is over fifty he may dislocate the lens and bring it with him. If his incision is too small, he will then be in trouble. Especially is this the case in cataracts of the type "hypermature ab initio." In patients over seventy if the surgeon is at all heavy

handed he can easily dislocate the lens and tear the capsule at the same time. If he does dislocate the lens he must enlarge his incision and express it in the capsule if that is intact, while if the capsule is torn as well, he must get out both it and the nucleus in the best way he can, even at the cost of a little escape of vitreous. But in children and young adults the lens is so firmly anchored that these dangers are practically absent.

If a capsulotome is used it should have a bend in the shaft so that it can be introduced easily. I prefer to make the laceration in the capsule transverse, as the flap will then be in the most likely position to get swept into it and can thus be sometimes caught with a pair of dissecting forceps and extracted after the lens matter has escaped.

If the laceration is made in a transverse direction some would have us believe that they can grasp the upper flap of the capsule when it is rolled out of the wound by the emerging nucleus, and tear it away with forceps. This is another of the manoeuvres which look very pretty in diagrams on paper, but which fail to work out so happily in practice. Owing to the elasticity of its attachments the flap is generally retracted back into the eye when the nucleus has escaped, and it is often not possible to be quick enough to seize it.

(4) *The expulsion of the nucleus and the lens matter.*—*The surgeon should press his spatula gently on* the upper lip of the wound, holding it in his left hand, more for the purpose of steadying the eye than for any

other reason. He should place the heel of the lens hook over the lower part of the cornea, with its convexity backwards, not on the flat, and express the nucleus by firm, steady but not heavy pressure. As it emerges he must follow it up by sliding the hook over the cornea right up to the wound, maintaining all the time exactly the same pressure. By this means he will express the nucleus with most of the lens matter at the first sweep. If he relaxes his pressure after the nucleus has emerged before the hook has reached the lip of the wound, a large mass of lens matter will be left behind in the eye. The subsequent expulsion of what remains, be it small or large, is not an easy matter. I prefer to do it by massage through the cornea with the lens hook, driving the cortical lens matter from under the iris into the pupil, and having gathered it there to express it out by a repetition of the original sweep. The uninitiated may think that this amount of massaging will injure the cornea. As a matter of fact the outer surface of the cornea will tolerate any amount of massaging without showing any reaction. It is the under surface which is intolerant of instrumentation. Hence other things being equal the less we introduce instruments into the eye the better.

The alternative way of getting rid of the lens matter is by means of McKeown's douche. The fluid used should be sterilized normal saline solution made up with distilled water, and contained in a reservoir capable of being raised a few feet above the table and lowered as required, attached to the douche nozzle by rubber tubing.

The eye must be steadied with fixation forceps while the nozzle is inside it. This instrument requires much lighter fingers for its successful use than most men would imagine. Its advocates do not tell us of the frequency with which the nozzle of the instrument is pushed back into the vitreous when the patient misbehaves.

(5) *Reposition of the iris.*—There is nothing special to note about this.

(6) *After treatment.*—If atropine is to be used to minimise adhesion of the iris to the after-cataract, as I prefer, the best method is to have the patient thoroughly under its influence before operation. We can then avoid subsequently meddlesome daily dressings.

(7) *The treatment of the after-cataract.*—I wish to emphasise that the evacuation of the nucleus and lens matter should be considered but the first stage of a two stage operation. The question of after-cataract and its treatment raises controversial issues of such importance that I am considering them in detail in a later section.

CHAPTER III

Routine After-Treatment.

CHAPTER III

THE ROUTINE AFTER-TREATMENT OF CATARACT OPERATIONS.

THE TREATMENT OF AFTER-COMPLICATIONS

This should be in accordance with the same principles that govern us in clean surgery in other parts of the body. It should be such as to secure the maximum rest for the wound and there should be no meddlesome interference without very sound reasons. Daily dressing and inspection of the eye merely satisfy a morbid curiosity. They do infinite harm and not the least good. Every exposure of the eye to light and every instillation of drugs causes the patient to wince. This puts pressure on the eye and may burst the wound open, when the iris will be carried into it with the rush of escaping aqueous and stay prolapsed when it heals. In my early days at this work I used to remove the bandages and inspect the eyes on the fourth day. But I very soon found that when I looked at them the next day there was prolapse of iris in many cases in which there had been none the day before. So I gradually postponed the first dressing until I now advocate leaving the eye unopened as a routine until the tenth day. I have seen prolapse occur on the sixth day and I cannot lay too much stress on exposure as one of the chief causes.

After intracapsular extraction in healthy eyes there is no lens matter left behind to irritate, no after-cataract to which the iris can adhere and no reason why anything should go wrong. If there is any likelihood of complications, whether because we are doing Daviel's operation or because the case is one of secondary or complicated cataract, we should have taken time by the forelock and instituted prophylactic treatment beforehand. Our drugs will then act promptly when required without waste of time and we will be able to avoid meddling with the healing wound. If anything does go wrong the information we can gain by inspecting the eye will not enable us to institute treatment of such value as to compensate for the risk of bursting the wound open or infecting it. If we are compelled for any reason to remove the dressing to see what is going on, it will be obvious at once if the lids are œdematous that the eye is infected. If they are not, the utmost we should do is to draw down the lower lid gently and look at the conjunctiva, this will not irritate the patient by letting in the light or make him wince. If there is no chemosis then there is no complication of grave import present. In the presence of complications the only drugs which are of any use for instillation into the conjunctival sac are atropine or eserine. If we have to use them for such events, they should be made up in the form of an ointment, a little of which should be placed inside the drawn down lower lid without uncovering the cornea.

Even this very cautious inspection of the conjunctiva should not be made unless the pain of which the

patient complains is severe and persistent. On the second or third day if constipated he will frequently complain of some discomfort not quite amounting to pain. This will vanish at once if he is given a mild purge, Blue Pill gr. V followed by a Seidlitz powder. If he has actual pain, half a dozen leeches to the temple will generally control it. The eye should never be opened until enough time has elapsed to see if these measures will be sufficient by themselves, reinforced if necessary by a hot fomentation applied lightly, efficiently and carefully. The commonest cause of real pain is the wound being squeezed open and a plug of sensitive iris being forced into it. The patient complains of it coming on sharply all of a sudden, but if he is left alone it will wear off in an hour or so and give place to a mere sense of discomfort. No harm ensues, and inspection can only make matters worse.

Bearing these points in mind I will run over some details.

(*i*) *The Dressings and Bandages.*

These should cover both eyes for the reasons discussed previously The unoperated eye should not be opened any sooner than the operated eye if the patient will put up with being kept in darkness. If he finds it very irksome, he may be given the use of his sound eye on the seventh day, while in some old patients who have a tendency to become delirious, it may have to be opened earlier. Doing so will generally relieve the conditions. Apart from this if dressings slip they should be readjusted without inspecting the eye.

When the time comes for the eye to be exposed for inspection, this should be done in a dull light and the soreness should have been eased by thorough fomentation. The patient is very intolerant of light, and if he winces may burst the wound open even on the tenth day. Professor Barraquer's Spanish patients must be extraordinarily tolerant, for he recommends daily examination with the slit lamp after operation. (*Vide* Fisher's Senile Cataract, 1923 Edition.) He would certainly not succeed in doing this with my Indian patients, nor would I allow any one to try.

While drawing the lids apart for inspection the patient should be told to make no effort. The lower lid should be pulled down with the ball of one thumb, the brow retracted with the other, the greatest care being taken that no pressure is made on the globe itself, while the orbicularis is fixed against the bony prominences so that the patient cannot squeeze effectively.

(ii) *Posture.*

The patient must rest in the horizontal position for the first twenty-four hours after operation, on account of the occasional occurrence of choroidal hæmorrhage. If the head is fixed on the chest, the congestion of the veins consequent thereon causes much discomfort in the eye. When this happens it usually does so within two hours of the operation, but I have seen it as late as sixteen and eighteen hours after in eyes which were apparently normal before operation, and in which there had been no complication during the operation. After

twenty-four hours he may be propped up or sit up in bed, as to keep a man on his back longer is sheer torture.

(*iii*) *Diet.*

This should be light, but of the same variety as that to which the patient is normally accustomed. Change of diet often upsets his digestion, for example the people of the Punjab suffer from diarrhoea if put on a purely milk diet and from tympanitis if given soup. A tobacco smoker should have his smoke, a liquor drinker or an opium eater his usual ration.

(*iv*) *Drugs.*

The bowels must be kept acting easily so that the patient does not have to strain at stool. I wish to emphasise here again that constipation seems to be a potent source of the discomfort which is often experienced on the second or third day. For it disappears promptly on the administration of a purge, Blue Pill gr. V followed by a Seidlitz Powder. It is not bad practice to give this as a routine on the second night. If the discomfort amounts to pain, the purge should be reinforced by applying at least six leeches to the temple. If these fail, a gentle hot fomentation should be tried in addition before we go the length of inspecting the eye prematurely.

(*v*) *Friends and Relatives.*

These should be encouraged to visit the patient so long as they do not disturb or excite him. He is much more at ease in their presence than if confined to the company of a strange nurse, and will be less fidgety and give less trouble.

(vi) Time of Discharge.

Indian patients will not stay with us for more than a day or so after the bandages are removed, so I make them go home with their eyes bandaged up, with orders to foment the eye freely, and to wear a shade till it loses all irritability. In the case of better class patients, I like to keep in touch with them for three weeks at least. The ordinary village patient can as a rule safely be discharged ten days after operation.

(vii) Spectacles.

They should wear plain dark glasses till the eye can bear light without inconvenience, and they should avoid dust. After six weeks they should be able to wear a + 10 D or + 11 D sphere for distant vision. After three months they may be allowed an extra 3 D for reading. It is not worth while refracting them accurately and correcting astigmatism until six months have elapsed, for it takes that time to reach a steady value.

If the patient experiences discomfort when he starts the use of spectacles it means that he is beginning too soon, and he should leave them aside again for a time. It is very important, especially in intracapsular cases to impress on the patient that he should not use his eyes for any exacting work for three months after operation as they are liable to shew signs of irritability from such causes. I well remember the case of a European lady who was given a shade at the end of fourteen days. On the fifteenth she complained of considerable irritation and photophobia and general congestion was evident. In

trying to discover the cause of this I found out with some difficulty that she had spent the previous evening with a hand lens trying to read an illustrated paper examining the pictures. A few leeches to the temple and exclusion from light for a few days set matters all right.

THE CAUSE, RECOGNITION AND TREATMENT OF AFTER-COMPLICATIONS.

Prolapse of Iris.

Prolapse occurs after the wound has become overtight on the third or fourth day. I have seen it occur as late as the tenth day. The cause of this, *viz.*, the patient suddenly squeezing the eye with the orbicularis and bursting the wound open, and the means by which it may be minimised, have been fully discussed in the section on iridectomy. I will only repeat here that *the theory will not hold water that it only occurs if the* iris has been stretched or bruised, and so paralysed during the expression of the lens. This theory is advanced by surgeons who perform the capsulotomy operation, in which the iris gets bound down to the after-cataract before the wound stops leaking, and in consequence is not so free to move when the wound is burst open. One has only to see an iridectomy performed in the manner described in the final chapter of this book to realise the absurdity of this theory. For in it an untouched healthy iris is swept into a very small wound by the gush of aqueous which escapes when the knife has emerged.

The most potent cause in provoking the patient to squeeze is the habit of dressing the eye and exposing it to light daily. I cannot lay too much stress on the dangers of this meddlesome habit. Were my practice of leaving the eye untouched for ten days more common, prolapse would be less so.

When prolapse occurs it will announce itself by the onset of a sudden sharp pain after the patient has squeezed the eye. This will wear off after a few hours to a mere sense of discomfort, and no harm will ensue. There is no need to inspect the eye. The practice advocated by some of replacing or excising the prolapse at once is positively pernicious. It is not necessary, for the iris promptly adheres to the surrounding structures and seals off the anterior chamber. Meddling with the wound only increases the chance of infecting it.

If prolapse is present at the first dressing on the tenth day, the eye should be rebandaged till the fourteenth day. The wound is not so soundly healed before this that we can afford to risk a struggle with the patient in excising it, and there is no advantage in attempting to do so. On the fourteenth day it should be excised under cocain with the orbicularis properly controlled by a competent assistant, who uses a squint hook for the upper lid, not a speculum. The prolapse is generally ballooned by the tension within the eye, but if it is not, a little pressure with the point of the fixation forceps will cause it to be so. It can then be cut off with a good pair of iris scissors laid astride it. If a head of vitreous escapes, it is no harm. The lids of the wound will drop

together and heal up without any trouble. The eye should be rebandaged for four days.

Iritis and Iridocyclitis.

The treatment of these complications must be as far as possible prophylactic, the most important of the measures available being extraction of the cataract in the capsule and not by capsulotomy. For the lens matter which remains behind in the latter operation is irritating to the structures inside the eye, and is the most important provocative cause in these complications. I think this is now becoming the accepted theory of the day, for the freedom of the intracapsular operation from these complications in healthy eyes has rendered untenable the hypothesis which was fashionable two decades ago, that they were due to bruising and stretching of the iris during expression of the nucleus and lens matter. This particular line of prophylaxis is more important than ever if there is reason for being especially apprehensive of these complications, as in the case of secondary or complicated cataract.

The only drugs which are of any value are mercury and atropine. The surgeon should have no hesitation about getting his patient fully under their influence before operation if he has any qualms as to the results that may ensue in the particular case. (Diabetics are very subject to iritis.) For if required at all, their action will be required promptly, and every hour wasted in getting them to act will be of importance. The rationale of the use of atropine has been discussed before, *i. e.*,

that its advantages outweigh its disadvantages only if it is successful in dilating the pupil. Mercury seems to assist it to achieve this object when iritis is present. If with its assistance atropine fails to dilate the pupil within seven days, it will be doing more harm than good and its use should be abandoned.

In combination with these drugs leeches should be used freely. The natural leech is far more effective than the artificial one: there is something peculiar about their action which has not yet been explained. If used in sufficient numbers, it is an invaluable weapon for the relief of pain and for reducing congestion in these and other inflamations of the deeper structures of the eye. In company with the leeches we should order frequent hot fomentations.

An iritis treated in this manner will generally recover, though if Daviel's operation has been performed enduring adhesions to the after-cataract will be the rule.

When an iritis or iridocylitis sets in the pain is not always proportionate to the severity of the disease. In this case the lids are always œdematous. If we have our drugs acting in anticipation, we should refrain from inspecting the eye until the wound has healed soundly. If the complication takes us unawares in the first week, we should restrain our curiosity and content ourselves with pulling down the lower lid to see if it is chemotic. If it is, our suspicions are confirmed and we should place a little atropine ointment inside it and close up again while we get on with the other measures.

There is no good purpose served by exposing the cornea and no necessity for it. If chemosis is not present then any complication which has occurred is of slight import, and can well await discovery till the dressings are removed at the end of the normal ten days. Chemosis remaining at the end of that time should be freely scarified under cocaine and hot fomentations applied over the eye.

Expulsive Choroidal Hæmorrhage.

I have mentioned before that the usual time of its occurrence is within two hours of the operation, though if the surgeon has been unwise or unlucky enough to tackle a glaucomatous cataract it will often occur on the operating table. I have seen it follow trephining for glaucoma. The symptoms which herald its onset are characteristic. The patient feels a sudden excruciating pain in the eye. He becomes over dizzy—and may even vomit. Then the vitreous begins to flow out and this is followed by free and prolonged bleeding from the interior of the eye. A good nurse will be conversant with the symptoms and their meaning. The patient is generally thirsty and demands a drink. He should be refused it as it promotes vomiting. Food should not be given him till he becomes hungry as otherwise it remains undigested in the stomach and may cause vomiting a few hours later.

It is not, as my opponents would have one believe, a more likely sequence of the intracapsular operation. It is dependent entirely upon choroidal disease which either has not been or cannot be diagnosed before operation. If such eyes are touched, it will occur with equal

frequency whatever the operation performed. I do not pretend to give figures to illustrate this, for if my word is doubted so will my statistics be. I endeavoured for a long time to obtain the statistics of two large Indian hospitals in which the capsulotomy operation is performed, in order to compare the frequency with which complications follow that method and my own. I was steadfastly refused the figures But the Report for 1920, of the Madras Government Ophthalmic Hospital gives some information. Apparently, in 1,525 cataracts dealt with by the capsulotomy operation there were 16 cases of what is called " turned section " or " eversion " of the corneal flap.

I have frequently heard men speak of this complication, but until recently I have always been at a loss to know what was really meant. But when I was shewn an alleged case I realised that I had been perfectly familiar with the condition, though I had never dreamt of calling it by that name The cornea does not simply evert of its own sweet will to suit some momentary whim, even with an incision of 180°. The wound is actually propped open by a plug of vitreous which has in its turn been pushed forward by a small choroidal haemorrhage, not large enough to declare itself on the exterior. A queer point which I have never been able to explain about these partial haemorrhages is that they are confined to the upper sector of the choroid opposite the middle of the wound.

We see then if my interpretation is correct that in the Madras Government Ophthalmic Hospital the capsul-

otomy operation, with its smaller incision, was followed in 1920 by concealed choroidal hæmorrhage in 1% of the cases, concealed in more sense than one for it was masquerading under the alias of "eversion of the corneal flap." Presumably there were some frank hæmorrhages as well. These figures dispose of the claim that the capsulotomy operation is relatively immune from this complication apart from my own experience. For there is no question that surgeons who extract cataract in the capsule are readier to tackle the poor risks than are those who extract by capsulotomy. Yet in my experience after intracapsular extractions the total incidence of choroidal hæmorrhage, both evident and concealed together, is less than 5 per 1,000 cases. Even this amount could be avoided if our powers of diagnosis were greater. For in disseminated choroiditis the reaction of the pupil may remain sharp and the recognition of light good, even though the disease is far advanced. On the degree of risk the operator is willing to take, the proportion of choroidal hæmorrhages depends.

In a frank expulsive hæmorrhage we may have to excise the eye, if only for the reason that the bleeding shows every sign of going on to an objectionable degree. The concealed variety needs no treatment. The eye will settle down in time as a blind organ.

Detachment of the Retina.

I have met very little of this complication following cataract extraction. The cases I have had, have occurred within ten days of the operation, and have been almost

confined to eyes in which a high degree of myopia has been present. It is not surprising that an operation should provoke it to occur in them, for we know them to be subject to it entirely apart from operation.

I doubt whether detachment of the retina, from any cause, is ever cured, either by the efforts of nature alone or with the assistance of the surgeon.

Septic Infection of the Eye.

This should occur very rarely if reasonable precautions have been taken. When it does occur, one will nearly always find that one has overlooked some pre-existent suppurative lesion about the eyelids or lachrymal apparatus. In the borderland cases complicated with chronic trachoma and dirty conjunctivæ on which one is compelled to operate in Northern India, it is much more frequent after the capsulotomy operation than after intracapsular extraction. The irritation caused by the lens matter remaining in the eye in the former and the facility with which tags of capsule get caught up in the wound and acting as a drain keep it open, have in my opinion a lot to do with this.

If the infection is confined to the wound, cauterisation with the thermocautery or nitrate of silver stick is said to be worth trying. I have never seen it successful. If it is not interfered with the condition will subside after a time and the eye will shrink up. In my experience sympathetic iritis never follows a suppurative panophthalmitis, and as our Indian patients generally object to the removal even of a useless eye, I do not ask to do it.

If it is done, evisceration is said to be a better operation than enucleation owing to the risk in the latter of septic infection spreading up inside the sheath of the optic nerve which contains a prolongation of the subarachnoid space of the meninges, though in the many such eyes I had enucleated, I had never seen such a result.

Acute Post-Operative Glaucoma.

There is a theory held in certain quarters that this complication is the result of vitreous coming forward into the anterior chamber and silting up the spaces of Fontana in the filtration angle, on account of the frequency with which it follows needling of the after-cataract in Daviel's operation. The protagonists of this theory would have us believe that it is possible to needle an after-cataract without injury to the hyaloid membrane, and so avoid this complication completely. How they manage to perform this feat passes my comprehension. In fact I would go so far as to say that needling an after-cataract is never successful, *unless a plug of vitreous comes forward and keeps the margin of the tear apart.*

A consideration of the main features of post-operative glaucoma will convince us of the inadequacy of this theory to explain the facts. For it is a complication which is not uncommon in the capsulotomy operation even apart from the times when it is provoked by needling an after-cataract, setting in about the fourteenth day when the wound is soundly healed. The earlier needling is done the more likely is it to be provoked. In fact it is one of the penalties we have to pay for inter-

fering with an eye which has not recovered its physiological equilibrium

Consider with this that it is a rare complication after intracapsular extraction, confined, at that, almost entirely to cases complicated by Bright's disease, gout, or the diabetes of advanced life. To a lesser extent we must be on the look out for it in the overfed corpulent type of patient. And in this operation it is readily amenable to treatment, under which it will subside completely, leaving no permanent damage behind it If it were due to vitreous silting up the spaces of Fontana I do not see that any treatment could be of avail.

Consideration of these facts must convince us that post-operative glaucoma is inflammatory in origin and that no mere mechanical theory is adequate to explain it, but that as in ordinary acute glaucoma transient œdema of the vitreous probably plays a large part in it.

The symptoms of the condition are those of ordinary acute glaucoma. There may be no iritis or iridocyclitis associated with it, nor any sign of inflammation of the deep intra-ocular structures Leeches must be applied freely, the bowels thoroughly cleared out, and hot fomentations used liberally. Eserine is useless, but if these measures do not produce an effect very speedily, there should be no hesitation in tapping the anterior chamber and letting out the aqueous, a Graefe's knife being slipped in under cover of the conjunctiva for the purpose. The condition will react magically if this is repeated daily for a few days if necessary, and will subside not to come

back again. If a bead of vitreous escapes at each tapping, it is no harm.

Late Pain.—Pain of a severe nature occasionally sets in during the third week, for which there is no evident reason beyond a congested "angry" look about the eye. The iris has its normal lustre and there is no *increase of tension. It can usually be controlled by a* few leeches to the temple, hot fomentation, a mercurial purge and ten grains of aspirin t. d. s. After a few days all goes well.

Subsequently if the patient has trouble when he uses *his eyes for accurate work or exposes them to glare, it* means that he is beginning too soon. He should return to his plain or dark glasses for a time and apply hot fomentations till all irritation has subsided.

The Treatment of After-Cataract.

This used to be one of the evergreens of ophthalmic surgery. Before 1903 there was hardly an Annual Meeting of an Association of Ophthalmic Surgeons in any *country at which it was not a subject for discussion.* It was often treated as a more important matter than the primary operation of which it is a necessary sequence and in my opinion, rightly. At the B. M. A. Annual Meeting in 1901, Sir Richardson Cross who opened a discussion in the ophthalmic section on this subject, laid down that the ideal operation for cataract is extraction in the capsule, but unfortunately it "is impossible." This was tacitly admitted by the Meeting. There was little idea then that a spirit was already moving on the

UDAIPUR

waters which would shortly show the "impossibility" to be not only possible, but eminently practicable.

In 1903 I read a paper on intracapsular extraction at the B. M. A. Annual Meeting in Swansea, I think the first ever read in England. Since that date after-cataract has waned in popularity as a subject for discussion, for a full dress debate would display too nakedly to the world the unsatisfactory state of the capsulotomy operation and the merits of its rival. The advocates of the former prefer to gloss it over, while painting the danger of intracapsular extraction in lurid colours, regardless of their absolute lack of practical experience of it. They do not now tell us of the sudden disasters which frequently destroy the eye when the "trifling" operation of needling is performed on the after-cataract. These disasters are certainly not less frequent than they used to be. For the surgeon who extracts cataract by capsulotomy is now-a-days forced by the pressure of competition to extend his sphere of action to the immature stage. The density and toughness of the after-cataract which ensues drive him to needle it while it is still young and tender, before the eye has lost its intolerance to further operative interference and has recovered a stable equilibrium.

If the reader wishes to study the literature of after-cataract he will have to go to the papers written before 1903 to find the bare unvarnished truth. Since that date it has been too dangerous with a rival in the field to admit that all was not well with capsulotomy in the best of all possible worlds.

In considering the problem let us start at the beginning.

Is the treatment of the after-cataract an integral part of the capsulotomy operation, of which the extraction of the nucleus was but the first stage?

The least of which the after-cataract can consist is the capsule of the lens. This is the irreducible minimum, which is found only when the cataract at the time of the operation was of the Morgagnian type in its fully mature stage, with the cortex completely liquefied. Even this minimum is in my experience never wholly transparent, never wholly negligible from the patient's point of view. This I have ascertained is also the opinion of many of the leading ophthalmic surgeons who operate on cataract by capsulotomy. Hence if the best possible visual results are to be obtained, a hole will have to be made in this after-cataract by some means, at some time in every single case. But the old generation of capsulotomy operators were often content with less than the maximum visual results, for they recognised the dangers of needling, and often did not interfere with the after-cataract if the patient had vision enough to do coarse work. In my opinion there was much to be said for this attitude.

It must be realised that such an after-cataract is the exception, not the rule, even when the primary operation has been done in the mature stage. If it has been done in the immature stage, the cortical lens matter is still a living tissue, still viscid, still firmly adherent

to the capsule, from which there is no satisfactory method of separating it. It remains in the eye and with the capsule rapidly organises into a dense fibrous sheet which obstructs vision as much as would a piece of linen. This state of affairs is aggravated if post-operative iritis ensues and the iris gets firmly bound down to the after-cataract. This complication was common enough in the days when immature cataract was regarded as beyond the range of operation by capsulotomy. With the modern practice of attempting to bring this stage within its range it must be much more common, for the mass of lens matter remaining in the eye is greater and therefore more provocative of evil It is clear then that there are very few exceptions to the rule that the after-cataract will require to be needled or extracted in every single case.

Apart from being an obstruction to vision, is the after-cataract an entirely harmless structure?

It is very far from being so. A patient who has one in his eye, whether it has been needled or not, even if he has escaped post-operative iritis, often tells us that the organ is constantly reminding him of its existence He feels it tender when he sneezes, coughs, or strains at stool. We know that such eyes are liable to serious intraocular trouble on the slightest provocation—provocation which would not influence the normal eye or the eye from which the cataract has been removed in the capsule. In short an after-cataract is a dead foreign body, which has no function to perform. Like all such foreign bodies, however innocent, however quiescent, it upsets the physiological equilibrium of the organ in

which it is, and is a potential source of mischief, an ever present threat to the continued existence of the eye.

Is an operation on an after-cataract a trivial matter, which can be undertaken without the slightest hesitation?

This question must be considered from two aspects, the psychological and physiological.

No patient makes light of repeated operations on the eye. If he has been warned before the primary operation as he should always be, that a subsequent needling will be necessary, he may submit to it phlegmatically. If he has not been so warned, or if as so often happens, the first needling is not successful, it is the most depressing moment in his life when he comes to realise that still another operation is necessary. All the nerve is taken out of him. He is at a time of life when mental and physical energy are on the wane, and I have known men holding important public positions prefer to remain in partial darkness during the evening of their years, doing their writing by dictation and having their letters read to them, rather than face further interference with their eye. Such may sound incredible but it is a fact which must be faced. We have to recognise that we are dealing with patients not merely with cataracts and at that with old patients whom worry and disappointment will send early to their grave. Any man of experience knows well that I am not painting an exaggerated picture of this aspect of the question.

The second aspect of the problem concerns the risks which interference with after-cataract carries with it.

These risks are by no means as negligible as the capsulotomy school would have us believe, but are every bit as great, if not actually greater than those present at the original extraction of the nucleus. This will become apparent in the consideration of the next question.

At What Time should the After-Cataract be Dealt with?

Here we are between the horns of a dilemma. Every surgeon must agree with me that the eye should be given as long time as possible to settle down after the primary operation before we interfere with it again. In my experience of the capsulotomy operation which is as great as that of any other man, the least period which must be allowed to elapse after it before the eye will tolerate interference, at all kindly, is three months. This is the minimum which holds good only if there has been no hitch of any kind in convalescence and all has gone completely well. I have frequently seen eyes, in which there were but slight adhesions of the iris to the after-cataract, respond to needling at this time and even much later with a violent reaction though to all outward appearance they were perfectly quiet. There would be fewer disasters if the general practice were to leave the after-cataract alone for six months after the primary operation.

But here is the second horn of the dilemma. If sufficient time is allowed to elapse for the eye to recover its equilibrium, the after-cataract will be so sclerosed and tough that no mere needling will be adequate to deal with it in a large proportion of cases. It might be repeated a

dozen times and not be successful, for the margin of the tear will come together again as soon as the instrument which makes it, is withdrawn. At this time no procedure short of deliberate extraction will be satisfactory. This is a simple procedure at whose entire neglect by the capsulotomy school I have often wondered.

If needling is to be successful it must be done while the after-cataract is still young and tender, and the risk must be taken of stirring up a violent reaction in the eye. The disasters that ensue, and destroy the eye with explosive violence, are many, but it is nowadays not considered politic to allude to them in public.

If the after-cataract must be interfered with early, it would be far better practice to do so at the earliest possible moment, that is to say at the primary operation when the eye is still open, immediately after the expression of the nucleus and the lens matter. The pupil must have been properly dilated with atropine. After taking out the speculum the lids and orbicularis should be handed over to the care of a competent assistant as in intracapsular extraction. The after-cataract should then be deliberately extracted by driving a pair of iris forceps through the posterior capsule, with their points wide open, closing them and bringing them out with what is in their grasp. The lens capsule will often come away in its entirety, but if it does not, at least a large hole will be torn out of the centre of the after-cataract. There may be some escape of vitreous, but it will not be much if the assistant is competent and anyhow it is of no consequence. I do not know why a trifling escape of vitreous

is regarded with almost religious horror as a disaster of the first magnitude, for in practice no harm ensues from it.

I have done what I relate frequently. It is not difficult. It is a sound job, far sounder than needling at any time. The eye often settles down after it with less reaction than if it had been left undone, why I do not know. There is from the beginning a large hole in the after-cataract which will always remain open. The eye will never need to be meddled with again. But I do not expect the advocates of capsulotomy to give it their benediction. For if they did so, they would admit the whole bill against them and would have no excuse for not extracting in the capsule except the perfectly sound and legitimate one of incompetence to do so.

By What Method should the Hole in the After-Cataract be Made ?

We have here the choice between needling and extraction. For either operation the patient should be put thoroughly under the influence of mercury and of atropine, both in anticipation of complications and to help in the operation itself. The bowels also should have been thoroughly cleared out.

(1) *Needling:*—This will only be successful in the young and tender stage, and even then its success is problematic and may be short-lived. It depends entirely on a plug of vitreous coming forward through the hole and staying there to keep it open. For if it does not, the margins of the tear will simply drop together. And even

if it does do so at first, later on when sclerosis sets in and the after-cataract loses its elasticity, it very often happens that the hole closes up again. When the after-cataract is old and tough, cuts in it will not draw apart at all to let the vitreous through.

If needling is done in the first few weeks, it does not matter what instrument is used for the purpose. It is so fragile that a blunt pointed probe would be quite good enough. Later, when it is tough, some really sharp cutting weapon is needed, and must be such that the edge can be *drawn across* the tissue which it is asked to cut. No knife will cut an elastic membrane such as an after-cataract if it is simply pressed against it. The best weapon for the purpose is an ordinary straight Graefe's knife, preferably a narrow one which has been resharpened several times, for it fulfils all the requisites. The various patterns of curved knives and needles are useless. No instrument maker can put a really sharp edge on the concavity of a curved instrument. The use of such instruments as Zeigler's sickle shaped knife is confined to men who are interfering with after-cataracts too early, when a blunt weapon would be just as effective.

The eye should be steadied with fixation forceps, while the knife is entered on the flat through the sclero-cornea. It is passed through the pupil and behind the iris on the opposite side as far as is possible without endangering the ciliary region. As it is withdrawn the handle of the knife should be raised so that its point is lowered, while its edge is brought against the after-cataract by twisting it back in the sclero-cornea at the wound. It is

prevented from enlarging the wound by keeping the back of the blade pressed against the cornea which is used as a fulcrum.

This manœuvre should make the knife cut the whole time as it is being withdrawn, and the after-cataract will be split from top to bottom if the pupil has been properly dilated with atropine. If a second cut at right angles is desired the first cut should be made a little to one side, so that a single cut in the larger flap will suffice. For this can only be done by cutting it from the periphery towards the first cut, and the anterior chamber must be given a few days to reform before the knife can be re-entered to do so.

This is the most satisfactory way to needle an after-cataract, for it gives the vitreous the best chance of coming forward and separating the margins of the cuts. But even with it the results are precarious, while if iris adhesions are present they may be disastrous. I am of the opinion that if needling were entirely omitted from the armamentarium of the ophthalmic surgeon it would on the balance be a good thing. In after-cataract it should be abandoned in favour of extracting the offending body. The apparent innocence of needling makes it seductive to the uninitiated in dealing with juvenile cataract and cataract secondary to iritis. In reality it gives good results in only a limited class of the former, while in the latter it is little short of criminal.

(2) *Extraction.*—When there has been no post-operative iritis and the after-cataract is not adherent to

the scar of the original incision a large sized iridectomy incision should be made at the centre of the old wound, the speculum removed and the lids and orbicularies being handed over to the care of a competent assistant, as in intracapsular extraction. The iris is more or less adherent to the after-cataract in almost all cases, but at the pupillary margin only, so that there is *always* a definite posterior chamber containing aqueous between the two. A short blunt pointed probe curved to a circle of ¾ inch in diameter should be slipped into this chamber, an iridectomy being made for the purpose if it has not been done already, or a piece more being taken out if it has been done, if the probe cannot be got between the iris and the after-cataract. The point of the probe should then be swept right round between the two, detaching the iris little by little till it has been completely freed. Thorough preliminary atropinisation is a great help, for it will shew up the adhesions if they are few, and will retract the iris as it is detached. The adhesions are generally much weaker than would be imagined and are quite easily broken down.

Free bleeding from the iris always follows such rough handling but it is of no consequence. The blood and clot should be massaged out with the heel of a lens hook till the bleeding ceases. The after-cataract should then be extracted by passing in a good pair of curved iris forceps milled to the angle, closed, to well below the middle of the pupil allowing them to open wide and then driving the points well back through the after-cataract and bringing out what is in their grasp.

This is in effect doing after the lapse of several months what I previously advised should be done at the time of the primary operation rather than take the risk of early needling. As in that case if a drop of vitreous escapes it is of no consequence, and the final result will be that the whole after-cataract will come away or that a large hole will be torn out of it.

This proceeding would, I know, be regarded in many quarters as reckless daring. But the eye tolerates it far better than needling and will settle down wonderfully quietly. By doing it I have more than once terminated recurrent attacks of iritis following a previous operation by capsulotomy—a clear indication that the after-cataract itself was largely responsible for them. It is quite a simple thing to do if the surgeon has the courage to go ahead. In my opinion it should replace needling altogether. It is doing later what should have been done at the primary operation, *viz.* extracting the offending body in its entirety. I have frequently done it to the complete satisfaction both of the patient and myself, in cases which had been condemned by experienced capsulotomy operators as past further interference. I have a small museum of such after-cataracts for I have very rarely failed with them.

CHAPTER IV

Lens Couching, etc

CHAPTER IV

A SHORT ACCOUNT OF LENS COUCHING AS PERFORMED BY THE RAWALS, SOME OBSERVATIONS ON THE HISTORICAL ASPECT OF THE SURGICAL TREATMENT OF CATARACT, AND A CONSIDERATION, OF THE RELATIVE MERITS OF INTRACAPSULAR EXTRACTION AND THE CAPSULOTOMY OPERATION.

Lens couching has beeen practised in the East from time immemorial. It is the parent of all modern operations on cataract and *alone* deserves the name of classical. History no more relates its origin than that of the practice which was the parent of all modern vaccination, the inoculation of a healthy individual with the juice from the pustule of a small pox patient, with the object of provoking a mild attack of the disease which would give a subsequent immunity to it. Both were important observations in their time. Both were given by the East to the West.

The Indian lens coucher belongs to a hereditary caste known in the Punjab as "Rawals," though by other names elsewhere. That province is the home and is studded with villages which take their name from the caste of their inhabitants, being called "Rawalpindi"

or the village of the "Rawals." I know of three such in the Jullundur District alone. The name is known to the world at large in another connection, for along-side one of these villages there has been built the largest Military Cantonment in the Indian Empire, which has taken its name from it.

In the cold weather the inhabitants of these villages debouch over the plains, itinerating through the country, and couching cataracts as they go along. They spread far beyond the Punjab, for they supply the lens couchers not only of the whole Indian Empire but almost of the whole world. At the time of writing the first edition of this book, I knew of three "Rawals" from the Jullundur District of the Punjab who were practising their art in Europe; among other things ophthalmic. One was in Hull, one in Manchester, and the third was itinerant in Italy and Austria. From a financial point of view they were all undoubtedly doing well.

The generality of them are grossly ignorant of all other diseases of the eye, which they treat indiscriminately by the application of black antimony powder to the conjunctival sac, and are not even adept at their own art of lens couching. They do not confine themselves to matters ophthalmic but also carry on a trade in juggling and palmistry, etc. The Indian fortune tellers who board steamers at Port Said and Aden are in my observation mainly "Rawals" from the Punjab.

There is another caste whose habits and customs are so strikingly similar to those of the "Rawals" that they

are of interest to mention. There are one or two villages in the Punjab whose inhabitants follow the hereditary profession of coining and supply the coiners of the most of the Orient. They are well known to the police but are far too skilful ever to be caught up in the practice of their art, for they ply their trade only when away from home. Periodically they return to their villages, there to lead the life of peaceful honest citizens.

I once got one of the most distinguished "Rawals" in the Jullundur District to demonstrated to me in every detail on a post mortem subject how he preformed his operation. His aseptic precautions were absolutely nil. He wiped his instruments before use on a dirty piece of rag. He neither washed his hands nor flushed out the conjunctival sac. He used cocaine powder. He inserted a sort of speculum and steadied the eye by catching the conjunctiva above with a fixation forceps. He made a puncture in the sclero-cornea below with a bleeding lancet. Through this he inserted a triangular probe, blunt in the point as well as in the edges, similar to that in an ordinary surgeon's pocket dressing case. He passed this in front of the iris below, across the pupil, and behind the iris above, until the point had reached beyond the upper border of the lens. He then dislocated the lens and pushed it down clean out of sight below the pupil by raising the handle of the probe. He then made a sweep round with the point towards the temporal side and another towards the nasal side in order to make sure that he had detached the suspensory ligament as completely as possible.

Throughout, his great object was to avoid rupturing the capsule, and it will be realised that it requires a very delicate touch to avoid doing so. In a profusely illustrated book on the extraction of cataract which is now in wide circulation one of the authors depicts this procedure. But he makes the surgeon insert a sharp lancet pointed needle mounted in a handle through the sclera into the ciliary body, behind the iris, negotiate the sharp point of it between the latter and the anterior capsule of the lens. Oblivious of the impossibility of this being done without catching up the iris or puncturing the lens capsule, he goes on to depict the same sharp weapon being used for the actual couching, its point having been inserted only as far as the centre of the pupil. How he expects the capsule not to be torn at this stage I do not know. The illustrations show the activity of a very fertile imagination.

From the patient's point of view the immediate result of lens couching is magical. He can see at once. He has no pain. There are no dressings. He is not laid up in bed at all, and the lens coucher does not wish to see him again. He is naturally not told that this is on account of the complications that follow in a large proportion of cases, sepsis, acute glaucoma and so forth, for which the lens coucher can do nothing. In fact he seldom likes to stay more than a day in one village and would be apprehensive of a beating if he returned soon.

But with ordinary aseptic precautions these complications could be largely avoided. And when all goes well

the cosmetic result is perfect, seldom equalled and never surpassed by any modern procedure.

In my early years at Jullundur a considerable proportion of my cases had been through the hands of the "Rawals." I soon observed that night-blindness invariably set in sooner or later in the successful cases. As in the form of the disease which is not uncommon in the Punjab apart from lens couching, the retinal changes are those of simple progressive atrophy, without pigmentary deposits, spreading with the lapse of time from the periphery towards the macula. In distinction from the type of the disease which is met with in Western countries it has been called *retinitis pigmentosa sine pigmento*.

The speed with which this retinal atrophy develops is in my experience proportional to the size of the nucleus of the lens when it was couched. With a hard cataract useful vision seldom lasts for more than three years. With a Morgagnian cataract, containing a small nucleus and much fluid lens matter which is soon absorbed, I have seen good vision still present as long as seven years afterwards, though with a diminished field.

The late Sir Jonathan Hutchinson was the only man I met who knew this fact. He told me that lens couching was the operation performed at Moorfields in his early days, and that it would never have been given up when the advent of Listerism made open operation on the eye practicable, if the initial good result had been lasting. If it were lasting and the disasters not prohibitive, I would be a lens coucher myself.

The facts I have related should surely dispose of the complacent claim by the performers of capsulotomy that it is the "classical and the conservative operation." Lens couching has the sole right to both titles, for it was the general practice even in the West before Daviel was heard of and continued to be so for a century after his death, and it is the only operation which conserves the pathological lesion in its entirety.

Daviel's operation has not even superior claim over intracapsular extraction to the title of "classical." Before his time the couched lens had been extracted in the capsule when it floated up in front of the iris—a rare occurrence—in which position it causes much mischief. As far as published records go, Samuel Sharp (1700-1773) performed intracapsular extraction before Daviel came on the scene with capsulotomy in 1745. La Fay of Paris was the first man to suggest a knife with which to make the corneal incision. Not long afterwards (1773), A. C. Richter passed a needle through the sclera, impaled the lens and manipulated it into the anterior chamber, after which he delivered it in its capsule through a lower corneal section without an iridectomy. J. J. Von Mahrenheim (1781) suggested that all cataracts be delivered in the capsule after completion of the incision. G. J. Baer revived Richter's operation in 1799. Christsen (1845) expressed the lens in its capsule by finger pressure on the upper lid. Few writers made much mention of the subject until in 1866 Pagenstecher of Wiesbaden and later his brother Herman described their method of

extracting cataract in the capsule by lifting it out with a spoon.

It will thus be seen that not only was intracapsular extraction performed before Daviel's time, but that even when his reputation was at its height, it continued to exercise the minds of the foremost ophthalmic surgeons of Europe. Throughout it must have been a serious rival of the capsulotomy operation, though neither could keep pace with lens couching nor were either performed in Europe in anything but negligible quantity until Listerism had been firmly established.

The real foundations of modern cataract surgery were laid, not by Daviel in France in 1745, but a century later by Col. M. C. McNamara, I.M.S., Professor of Ophthalmology in the Calcutta Medical College. He commenced in 1864 and describes the procedure in the three editions of his book, the first published in 1868, the third in 1884.

His words are as follow :—

" The object we have in view in this proceeding is to remove the lens without opening its capsule. The advantages it offers are that no capsular cataract can possibly form and there is no chance of any soft lenticular matter being left clinging to the iris and setting up irritation and inflammation in that delicate structure.

" Atropine having been applied so as fully to dilate the pupil, the patient is to be laid on his back and chloroform administered (there was no cocaine in those days).

The surgeon standing by the side of his patient applies the stop speculum; and the eye being fixed with a pair of forceps, a flap is to be made through the lower section of the *sclerotic* immediately beyond the margin of the cornea, the same precautions being taken as I have already described in the case of ordinary flap extraction. A portion of the lower part of the iris is then to be excised, and gentle pressure exercised with the curette upon the lower part of the sclerotic and at the same time pressure is to be made with the point of the finger upon the upper part of the eyeball. In this way the lens in its capsule may be forced out of the eye. If the lens is not rapidly displaced upon slight pressure being made on the globe of the eye the curette may be inserted behind it and a gentle traction exerted on the lens so as to start it from its position.

"In making the flap we must keep slightly external to the margin of the cornea so as to leave as large an opening as possible, through which the lens may escape, its bulk when contained within the capsule being considerable.

"This operation is no doubt a very valuable one and often leads to most favourable results. Even though there is a difficulty in extracting the lens in its capsule the latter may be opened and the operation completed as an ordinary flap extraction; in fact, it will be always advisable to resort to this proceeding, unless the lens and capsule are forced through the section in the cornea upon slight pressure being made on the eyeball; any extra

force is likely to squeeze out a considerable quantity of the vitreous."

Wright of Columbus, Ohio, published a paper in 1884 and another recently in Fisher's book on cataract on this subject. Many of his countrymen claim for him precedence. Let such compare his papers with the above quotation and they will see that Wright's procedure is exactly the same without modification—no doubt a coincidence, though McNamara's book was read the world over by ophthalmologists. It was the foremost book of its time. It was larger than any treatise on practice of medicine in the sixties.

Next in time comes Colonel Molroney, I.M.S. His method was essentially the same as McNamara's (*vide* Rai Bahadur Mehr Chand's paper in the proceedings of the Indian Medical Congress of 1894), but to him belongs the credit of extending it to all senile cataracts—a very great advance.

As far as I can see, the intra-capsular operation would have ended with Molroney—as he never wrote a paper on the subject—had some one else not come on the scene.

I happened to be that some one: I developed a technique radically different from that of my predecessors, except in that the essential expression was maintained. They were at the mercy of the patient if a difficulty arose, for they left the orbicularis uncontrolled. I overcame that problem. I wrote up the case repeatedly, held the field against all comers, and taught all who wished to

come to me as pupils, until the case was established. The profession began to think. Capsule forceps, pneumatic and others, came on the scene in an endeavour to simplify the operation, but with scant success. In the end, the method of expression from without has proved supreme, having been developed last and foremost by officers of the Indian Medical Service.

The Relative Merits of Intra-capsular Extraction and the Capsulotomy Operation.

In my experience the incidence of after complications and the immediate mortality of eyes is far less after intra-capsular extraction than after extraction by capsulotomy. With the absence of an after-cataract the visual results are better and are more permanent, while the eye itself wears better and is less liable to give trouble on slight provocation.

The reader will at once demand to know the grounds on which I base this sweeping statement. He will find in the Appendix three detailed reports of visual results and the ocular conditions in a series of cases. The first, by myself (reprinted from the *Archives of Ophthalmology*, 1912), gives the vision obtained on discharge from hospital (amounting to an average of 6/5) in 132 cases selected for this purpose *before operation*. The Second, made out for the first edition of this monograph by Lt.-Col. A. E. J. Lister, F.R.C.S., I.M.S. (Retd.), gives the end results after varying periods of years, in 98 cases

selected for the reason that they had been complicated by escape of vitreous at the operation. It demonstrates, in a manner which cannot fail to carry conviction to an unbiassed mind, the truth of my contention that a small escape of vitreous is without any deleterious consequences whatever. The third is the paper read by Dr. Arnold Knapp of New York, my first pupil at Jullundur, to the Congress of English Speaking ophthalmologists held in London in 1925. He describes in detail the end results of those cases in his practice in which he had performed intra-capsular extraction, the earliest dating back to 1910, the latest to 1919. It is interesting to compare these with Daviel's original paper from the Memoirs of the Royal Academy of Medicine of Paris.

I have however always held that if my sober judgment, based on an experience of over 50,000 cases, is called in question, so will any document I may produce which purports to give details of a series of cases, however large. There is a far better method of assessing the relative value of these rival operations, one which admits of no dispute as to the personal equation of a surgeon reporting his own and other men's cases. It lies in consideration of the cataract statistics of the Indian Empire as a whole. The Annual Provincial Medical Reports, giving the work of the Government Hospitals and Charitable Dispensaries for the last 50 years, are available in the Library of the India Office to any one who takes the trouble to ask for them. A study of them, comparing the figures of one Province with another, year by year, admits of but one conclusion.

Statistics of Cataract Extraction in Civil Hospitals and Dispensaries.

(Extracted from the Official Records of the India Office.)

Year.	Punjab Including N. W. Frontier Province up to 1913.	Total of U.P., Bengal, Madras and Bombay.	United Provinces of Agra and Oudh.	Bengal (Including Calcutta).	Madras Presidency and City.	Bombay Presidency and City.
1881	265	—	2,649	357	—	—
1882	507	—	3,321	350	450	—
1883	435	5,480	4,641	391	255	193
1884	596	7,000	6,048	500	222	230
1885	948	7,451	6,048	763	443	197
1886	1,501	6,683	5,506	551	407	219
1887	2,459	7,093	5,625	635	511	322
1888	2,658	7,855	5,966	893	730	266
1889	3,857	8,988	6,739	1,235	749	265
1890	4,013	11,175	7,615	2,017	1,227	316
1891	4,482	12,521	9,445	1,683	1,103	290
1892	4,294	12,339	8,880	1,597	1,307	355
1893	5,309	12,238	9,124	1,481	1,271	362
1894	5,305	12,269	9,222	1,407	1,233	407
1895	6,216	14,197	10,563	1,913	1,254	487
1896	5,323	13,683	8,923	2,845	1,425	490
1897	4,667	11,192	6,514	3,134	1,562	382
1898	4,534	11,918	5,613	2,560	1,222	523
1899	5,319	10,664	5,734	3,051	1,301	578
1900	5,014	11,202	5,971	2,862	1,472	697
1901	6,590	11,276	5,787	3,159	1,621	709
1902	5,909	11,594	5,335	3,885	1,495	879
1903	6,107	11,504	5,157	3,537	1,418	942
1904	7,465	9,859	3,023	3,514	1,346	1,012
1905	7,929	10,113	4,994	3,053	1,149	917
1906	8,317	12,316	6,421	3,653	1,232	1,010
1907	8,122	11,800	5,568	3,866	1,404	962
1908	8,099	11,813	5,474	4,322	1,034	985
1909	11,156	12,267	5,442	4,745	1,442	1,238
1910	11,397	13,137	6,165	4,266	1,187	1,419

Year.	Punjab Including N. W. Frontier Province up to 1913.	Total of U.P., Bengal, Madras and Bombay.	United Provinces of Agra and Oudh.	Bengal (Including Calcutta).	Madras Presidency and City.	Bombay Presidency and City.
1911	12,290	14,550	6,829	4,953	1,344	1,424
1912	15,576	14,303	8,846	2,464	1,526	1,467
1913	16,236	14,437	9,905	1,291	1,655	1,586
1914	14,907	13,421	8,712	1,391	1,751	1,567
1915	16,457	13,185	8,322	1,357	1,833	1,673
1916	15,542	13,560	8,059	1,283	2 132	2,086
1917	14,794	14,353	7,512	2,772	2,374	1,695
1918	13,112	13,950	7,897	2,554	2,067	1,402
1919	19,093	13,645	6,828	2,329	2,866	1,622
1920	19,721	13,245	5,716	2,308	2,994	2,227
1921	15,092	12,028	4,165	2,170	3,351	2,262
1922	17,488	...	5,208	—	3,190	1,942
1923	17,617	14,139	6,019	2,599	3,527	1,994
1924	18,825	14,237	5,753	3,124	4,136	1,224
Population Census 1911	22,171,889	175,238,174	47,182,044	79,973,084	41,405,404	16,672,642

The figures for the Central Provinces and the Foreign Department (Native States), which together form more than 1/3 of India, were not available, nor were those for the North West Frontier Province since 1913. Before that date this Province was included in the Punjab, hence the figures for the latter should be somewhat larger than represented above since that date for purposes of comparison with earlier years. The figures of the work done by the Mission Hospitals are not included, *i.e.* those for the Bombay Presidency take no account of the 1,500 cases operated on annually by Dr. H. T. Holland, of the C. M. S. Mission, at Shikarpur in Sind during the months of January and February.

Analysis of these figures shews that in the years round 1895 some 5,000 cataracts were extracted annually in the Punjab, mainly by capsulotomy for intra-capsular extraction was then in its infancy. At that time one in three of the cases seen at the "outdoor" had received the ministrations of the itinerant lens coucher with whom the capsulotomy operation was having a hard struggle to hold its own. In a very few years the Jullundur Hospital had grown to be the largest cataract clinic in the world, solely on the basis of intracapsular extraction, which in the course of three decades has raised the figures for the Punjab and N. W. Frontier to over 20,000 cases annually, has driven the lens coucher from the road and the capsulotomy operation from the hospitals. In the other four Provinces, in which capsulotomy is still the vogue, the figures have remained almost stationary at some 12,000 to 14,000 cases annually and the lens coucher still plies a flourishing trade.

[Big fluctuations in individual Provinces are concerned with the rise and fall of individual surgeons, but it will be seen that this factor evens out when the figures for the U. P., Bengal, Madras and Bombay are added together.]

A similar tale is told on a smaller scale by the Bombay Presidency. During two months of the year Holland at Shikarpur in Sind extracts in the capsule some 1,500 cases—as many as are done during the whole year in the rest of the Presidency, to which intracapsular extraction has not yet penetrated and in which the lens couchers handwork is still only too painfully evident.

These are the figures which dominate the situation in the controversy over the relative merits of capsulotomy and intra-capsular extraction of cataract. They will admit of but one conclusion, with which there can be no quarrel on the grounds that like is not compared with like [*vide* such statements as that made in a recent review, in the *British Medical Journal*, of the book on cataract by Major Nesfields, I.M.S. (Retd.) : " We would never allow European eyes to be subjected to the violence to which these Indian eyes can be subjected," and the argument which is always advanced that Indian patients are satisfied with poorer visual results than European patients. This incidentally is far from being the case. The peasantry of the Punjab are as highly utilitarian and as exacting in their visual requirements as any peasantry in the world]; nor can there be any quarrel with it on the ground that the cases have not been followed up.

They have been followed up by the most impartial and most critical of observers, the patients own friends who are themselves contemplating an operation for cataract, who have no interest in details of operative technique but are solely concerned with the quality of vision and its endurance. The patient and his friends gather round the village *hookah* and discuss all matters from every angle with the itinerant priest, who passes on the news from village to village. It is here that the reputation of hospitals is made and lost, the fate of rival operations is decided. These figures are the verdict of the village *hookah* on the matter. They form an argument in favour of extraction in the capsule which cannot be

ignored. The obstacle is now removed which in the past has quite rightly prevented the profession in the West from adopting it—that with its more limited opportunities for acquiring the necessary technical skill there was no method at its disposal with which it could hope to attain success. For the latest developments of the Indian method have reduced its technique to a simplicity hitherto undreamt of, which should enable it to be performed in relatively unskilled hands not merely with a lower incidence of loss of vitreous than the capsulotomy operation when in the later an adequate attempt is made to clear the eye of cortical lens matter, but even without that rupture of the hyoloid membrane which is an inevitable result of interfering with an after-cataract.

CHAPTER V

Treatment of Glaucoma, etc.

CHAPTER V

THE TREATMENT OF GLAUCOMA AND SOME OTHER COMMON OCULAR AFFECTIONS.

GLAUCOMA.

Ever since the day when Von Graefe did the first iridectomy for glaucoma it has remained the basis of all forms of the surgical treatment of the disease. That it has some mysterious influence on its progress there can be no doubt. But exactly what the influence is, is another matter. There have been more wild and groundless hypothesis put forward to explain it than I know of in any another department of ophthalmology. One which is fashionable at the present time is that the lymphatics of the iris do not seal up when they are cut across, but remain permanently open and form a channel by which the aqueous can escape. We are asked to believe that the iris behaves differently in this respect from every other tissue in the body—a thing that is *prima facie* absurd. When we remember the prediliction of the iris for throwing out an exudate at the slightest provocation, for adhering to an *after-cataract* or *sealing off a perforating corneal* ulcer, it is hard to imagine that the cut edges will not be sealed over with fibrin in a very short time, which will rapidly organise into a groundwork over which the epithelium will grow.

The only theory which recommends itself to me is that in acute glaucoma the vitreous shares in the general œdema of the other structures of the eye; an œdema which is caused by some toxin circulating in the blood. By its swelling it pushes the iris forward and mechanically blocks the filtration angle. The incision which is made for the iridectomy lets down the tension temporarily, relieves the acute emergency, and gives Nature time to eliminate the toxins, and cure the disease before the eye has been destroyed, a process in which she may be much assisted by the use of leeches and of hot fomentations. What the subsequent influence of the iridectomy is I do not pretend to know.

When we come to consider chronic glaucoma the question arises of the value of anterior sclerectomy, introduced by Lagrange of Bordeaux. I have some doubts of the permanent utility of the operation, for if the hole in the sclerotic is too small it will close up and the influence of the iridectomy alone will be left, while if it is large enough to remain open permanently, the eye will be soft. We cannot expect an artificial drain to perform a physiological function properly, and to replace the delicately regulated channels by which nature allows the aqueous to escape.

In my opinion the beneficial effect of a small anterior sclerectomy lies solely in the hole taking longer to close up than a simple incision. This gives Nature a little more time in which to re-establish the normal physiological equilibrium between the rates at which the

aqueous is secreted and is drained away It is no substitute for an iridectomy done properly

For this last reason I abominate trephining introduced by Freedland Fergus of Glasgow, in imitation of Lagrange's method *and as a substitute for it* It is impossible to do an iridectomy efficiently through a trephine hole I defy any man to make through it more than a small button hole in the underlying portion of the iris, ragged tags of which get incarcerated in the hole, blocking it up in the first instance, and later giving rise to trouble by the formation of cysts In fact the sclero corneal trephine is in the same class as all the other machines, such as Murphy s button, which are introduced periodically into surgery It is a very poor substitute for a good pair of hands It is destined to go the way of its companions and join them on the shelves of a museum of discarded surgical instruments

Finally, the latest development of trephine deserves a word of mention Herbert after taking out the disc of sclerotic leaves the iris in place He alleges that it acts as a drain and keeps the hole open *The absurdity of this is apparent* when we remember the way in which the iris comes forward and seals off a perforating corneal ulcer, in which it sticks to the after-cataract in the capsulotomy operation or if left intact in the intra-capsular operation prolapses into the wound and adheres to it We might as well expect the iris not to stick itself to any raw or inflamed surface with which it comes in contact as the omentum not to do the same thing in the abdomen. In view of its proclivities for sealing off any

hole or localising an inflammatory process, the former as much deserves to be called the "policeman of the eye" as the latter the "policeman of the abdomen."

In addition to the impossibility of Herbert's procedure being successful, there is the grave risk in it of sympathetic ophthalmia ensuing at a later date, if the portion of iris prolapsed into the trephine hole includes with it any part of the ciliary body, a thing it is not unlikely to do.

There are some points in the actual performance of an iridectomy which are worth mention.

(1) *The Conjunctival Flap.*—I need hardly stress the importance when a conjunctival flap is being dissected up prior to the performance of Lagrange's operation or trephining, of including *all* the subconjunctival tissue with it. It is widely recognised that failure to do so has been responsible for many of the cases of late sepsis after either operation.

(2) *How to make the Incision.*—I hate a keratome for this purpose, for it always seems to cut as if it were blunt and it is not nearly so readily controlled as a Graefe's knife. The latter will be better if fairly stout in the front. The eye is steadied with fixation forceps, taking hold of the conjunctiva opposite the point at which the knife is to be inserted.

The knife is directed towards the centre of the pupil and entered on the flat at least 3 mm. behind the sclerocornea. The root of the iris is far further back than is

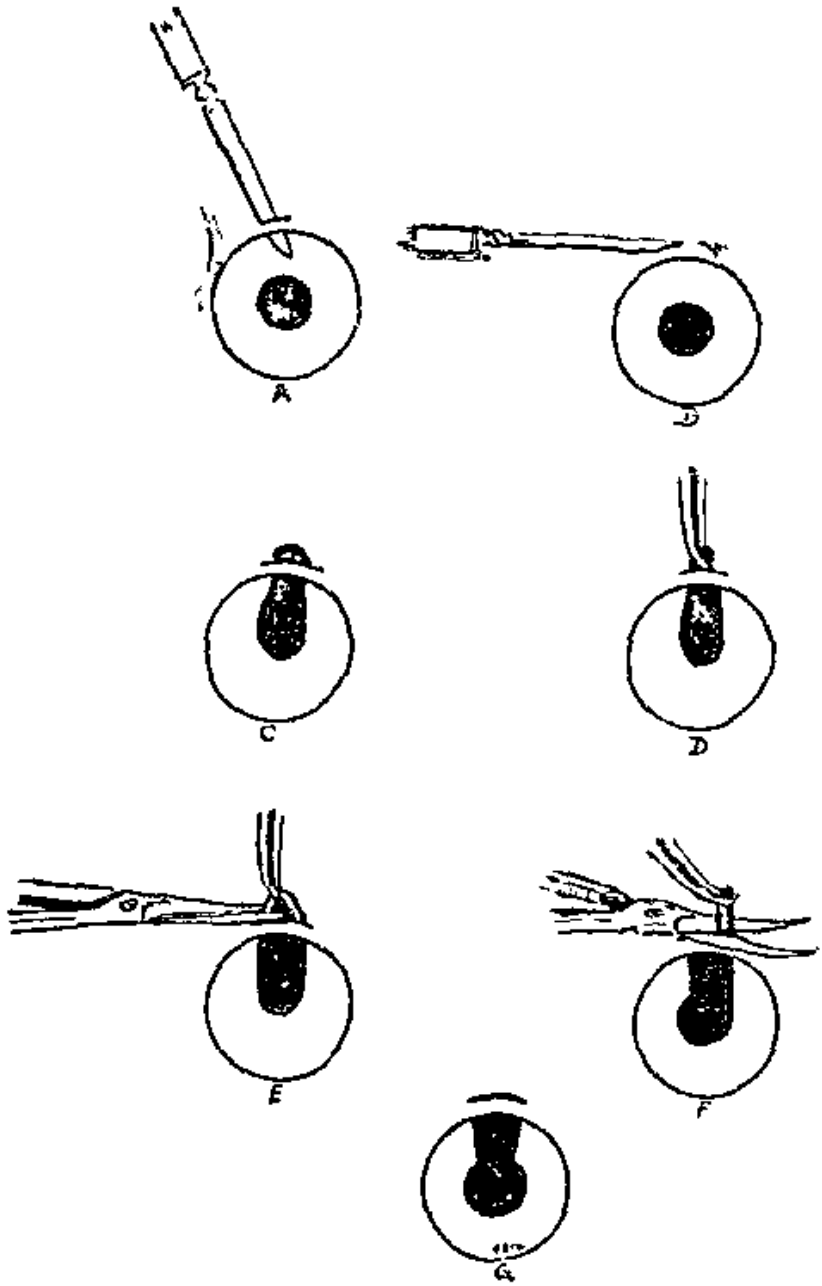

Fig. 68

Illustrating the Iridectomy for Glaucoma.

A—The point of the knife is thrust through the sclerotic and emerges in the anterior chamber at the extreme angle B—The handle is then depressed to nearly right angles at the point, cuts its way out with a snap. C—The iris protrudes by depressing the upper (sclerotic) wound causing a hernia. D—The hernia is grasped by forceps. E—The scissors cut one side of the pupil margin to iris periphery F—The scissors completes the iridectomy G—the result

generally imagined, and there is no danger of wounding it or the ciliary body by entering the knife in this position With the blade held on the flat the natural tendency of the knife to split the sclerotic is given full scope, and it will slip into the shallowest anterior chamber without picking up the iris

The point of the knife is passed well in towards the centre of the pupil (Fig 68, A) The handle is then dropped while the edge is turned slightly backwards which will bring it up into the filtration angle behind the sclera If the knife is stout in the point it can then be made to cut straight out without counterpuncturing (Fig 68, B) A slender point will be liable to break off if this is done and the incision should be finished by counterpuncturing and driving the knife on

(3) *How to do the Iridectomy* —If the incision is made this way no aqueous escapes till it is completed, when the sudden gush flushes the iris into the wound, which seals it again It can be picked up with forceps and drawn out, the sign that the pupillary margin is out being a gush of aqueous escaping from the wound When the operation is being done for glaucoma the iris must be pulled right out till it strips off from the ciliary region opposite the point where it is in the grasp of the forceps It will then have the appearance of an inverted V, and should be pulled almost till it will come no further One limb should be cut through and the other limb drawn out still more before it is snipped off (Fig 68, E & F) If done this way there will be no replacement to be done except at the side where it was first cut, and a really

broad strip of iris will have been torn from its ciliary attachment. (Fig. 68, G.)

The removal of a piece of the scleral lip of the wound in doing Lagrange's operation:—

The best weapon for this purpose is a small punch forceps, though a good pair of scissors curved on the flat is almost as useful and in an emergency it can be done with a Graefe's knife.

Myotics in the treatment of simple chronic glaucoma are useless in my experience.

Iritis.

These common types met with are usually classified as Syphilitic, Gonorrhœal, and Rheumatic, that is to say in the last type the æteology is indefinite but it is at the present time the custom to attribute it to focal sepsis elsewhere in the body, *i.e.*, dead teeth, etc. Clinically, the Syphilitic type is insidious in onset, is marked by the relative absence of pain and in the early stages by the presentation of a less violent reaction than in the two last, in which pain is a prominent feature. Apart from this the ocular appearances are indistinguishable. The circum-corneal vessels become injected. The iris loses its lustre and becomes muddy looking, a fibrinous exudate on it may be visible to the naked eye, the pupil is typically contracted, its reaction to light—sluggish in the early stages, is soon lost altogether with the formation of adhesions between the iris and the lens, while examination of the cornea with a loupe shews the

presence of punctate deposits on Descemets membrane, the so-called Keratitis Punctata In the acute stages of the disease the ocular tension is not raised.

The treatment of the condition is very important. It admits of no delay, for much damage may be done to the eye if general and local measures are not adopted promptly—if we wait for the result of the blood tests in the syphilitic cases, organised adhesions will form between iris and lens which salvarsan will not cure Our first object in these cases should be to get the patient under the influence of mercury in the minimum of time If we administer ½ gr of calomel or 1 grain Blue Pill with ⅙ gr of opium every two hours we will be pretty certain to have him on the border of salvation within 24 hours —after which we can reduce the frequency of the dose Local measures consist in free instillation of a 1 per cent atropine ointment in the conjunctival sac and the application of half a dozen leeches to the temple on the affected side, and the use of hot fomentation properly applied every three hours The natural leech possesses a powerful influence in these ocular conditions for which we are at present unable to account, but which is none the less there, and with the fomentations greatly intensifies the effect of the mercury and atropine The object of the atropine is to dilate the pupil and either prevent the *formation of posterior synechiæ or break down such as* may have already formed If it does not achieve this object within three days, its influence is harmful and its use should be discontinued

Having attended to these measures, steps should be taken to deal with the general condition of the patient, salvarsan, etc., in the syphilitic cases, attention to the urethra in gonorrhœal cases and eradication of septic foci if such are present in the remainder.

When posterior synechia form and are permanent—as will be the case if atropine fails to dilate the pupil within three days, the eye is left in an irritable state and liable to frequent relapses until finally the pupillary margin of the iris is bound down to the lens all round, its periphery being bulged forward into the filtiation angle by the pressure of aqueous in the posterior chamber and a *condition of secondary glaucoma is set up.* The only way to deal with such cases is to perform an iridectomy during a quiescent period—seems for some reason to have every favourable inflence in the prevention of relapses.

Trachoma.

We do not know the cause of trachoma, till we find out and—perhaps even after, our treatment must remain empirical. I will not attempt to discuss all the various methods advocated but will content myself with considering those that I have found successful in practice.

(*a*) *The Mild Cases.*—I turn out the lids and cocainise them in that position, keeping them pressed together so that no cocaine gets on to the cornea. The cocaine is washed off with distilled water and the exposed *surface is brushed freely with a strong solution of nitrate* of silver, gr. 60 to the ounce, which is neutralised with

common salt solution when it has acted sufficiently With ordinary care no silver solution will get on to the eyeball, but if applied carelessly, it will get on to the cornea and injure it owing to the cocaine having broken the reflex arc by which the secretion of tears is normally initiated in response to an irritant If used without cocaine no harm will result, the chlorides of the tears neutralising the silver nitrate before it has had time to act on the corneal epithelium The reaction set up is fairly intense and should be controlled by fomentations The procedure is repeated every second day for a few times and will quickly control all ordinary cases of trachoma

This procedure is not more painful than an application of copper sulphate crystal I have tried all the organic silver compounds and many other preparations and have found nothing so efficient as nitrate of silver

(*b*) *The Bad Cases*—For these, operative procedures have been advocated ranging from expression of the follicles to excision of the tarsal cartilage I mention the latter only to condemn it It is not more successful than milder methods and is unnecessarily severe When the tarsal cartilage has been removed there is nothing to maintain the form of the upper lid which contracts in consequence to an objectionable degree What I find most satisfactory is to rub the affected region with nitrate of silver stick, using the precautions noted above to prevent the cornea from its action This induces a very sharp reaction causing œdema of the lids which will need to be controlled with hot fomentations properly

applied. In three days, treatment is continued with nitrate of silver solution, gr. 60 to the ounce. I have never seen the cornea injured by this treatment if due care is taken, and I have not seen a case which was not controlled by it for the time, though of course there is always a considerable liability to recurrence in this disease.

For superficial cautery work there is no agent to equal silver nitrate in delicacy and ease of control. Its action is purely superficial, for it is at once neutralised by the chlorides which it encounters in the deeper layers of the tissues, and can be stopped at once with common salt solution when it has done what has been required. Carbolic acid, corrosive sublimate and other strong agents are not under nearly as delicate control.

Corneal Ulceration, Pannus, Corneal Opacity, Interstitial Keratitis.

Corneal Ulceration and Pannus, may or may not be associated with Trachoma. In the former case the pannus is local, being the reaction of the tissues to a long standing local ulcer. In the latter it is general, and forms the very common type met with in India, the vessels infiltrating the cornea being superficial and derived from the conjunctival vessels. In Interstitial Keratitis the vessels are deep and derived from the deep vascular supply of the sclerotic.

Corneal opacity, when local, is the result of past ulceration, and is dependent in its depth and extent on the depth and extent of the proceeding ulceration. When

general, as in the so called "ground glass cornea," it is generally due to interstitial keratitis, itself a manifestation of congenital syphilis, and is situated in the deeper layers of the cornea Further than this I will not go into the pathology of these conditions, their treatment having much in common

Corneal Ulceration —I wish in this connection to draw attention to the time honoured ritual, the use of atropine—the most widely abused drug in the ophthalmic surgeons' pharmacopœia This is far from being the harmless agent that it is given out to be in the Medical Schools, where it is taught that it may be used freely in almost any ocular condition with the exception of glaucoma The rationale advanced for its use in corneal ulceration is that it dilates the pupil and keeping the iris away from the seat of ulcer prevents this body from becoming adherent or prolapsing, should perforation occur Even if it did succeed in this it would not be an advantage, for adhesion of the lens is an infinitely greater evil than adhesion of the iris An optical iridectomy will have to be done subsequently in any case when the ulcer is healed adhesion or no adhesion and there is really no object in keeping the iris away from the ulcer And in practice atropine does not effect this object—however dilated the pupil may be it contracts down as soon as perforation occurs and the ocular tension is reduced, the iris rushing for the hole to plug it and seal it up What object could there be in preventing the 'omentum of the eye' in performing this very useful function, even were it possible to do so Further-

more the use of atropine undoubtedly raises the ocular tension, increases the risk of perforation occurring, and reduces the nutrition of the cornea.

A very common prescription with a certain class of Indian practitioners is drops containing atropine and cocaine to reduce the pain and photophobia in corneal ulceration. It is about as deadly as the use of morphia to stop the pain and diarrhœa in bacillary dysentery, the cocaine paralysing the natural defensive and reparative mechanisms of the cornea so that the eye goes from bad to worse with lightning rapidity.

The treatment I found most satisfactory is to brush the ulcer with a strong solution of nitrate of silver, gr. 60 to the ounce, no cocaine being used the lachrymal reflex and the tears promptly neutralise the silver salt and confine its action to the superficial layers of the ulcer itself. If cocaine is used, of course much damage may be done. Silver nitrate has the advantage over carbolic acid that its use may be left in the hands of comparatively ignorant persons.

Any associated trachoma must be treated on the lines indicated previously. If the tension is raised and perforation threatens to occur, I slip Graefe's knife subconjunctivally through the sclerotic into the anterior chamber and let out some aqueous; this procedure may be repeated subsequently if necessary and is in my experience more satisfactory than section through the ulcer itself. If the case hangs fire a subconjunctival injection of 25 ms. of a 1/5,000 solution of cyanide of mercury (not

oxycyanide), containing 1 per cent of acoin to relieve the immediate pain and followed by a hypodermic injection of gr ⅓ of morphia to control after-pain, will set up an intense reaction and will often work wonders The pain and photophobia disappear at once indicating that active inflammation has ceased In obstinate intractable cases which have wandered from person to person without relief I have more than once seen good result from an iridectomy why I cannot tell Of course I am not advocating this except as a last resort

I am assuming of course that such causes for the ulceration as trichiasis have been looked for and dealt with

Pannus —There are two procedures to be considered here peritomy and subconjunctival injection of an irritant The former will be successful only if care is taken to excise a strip of conjunctiva and all the subconjunctival tissues *right down to the sclerotic* For the latter the best agent is cyanide of mercury, 25 m of solution ranging in strength from 1/3 000 for children to 1/6,000 for adults combined as previously directed with 1 per cent of acoin, the late pain being controlled with a hypodermic injection of morphia, and the reaction induced, which will include œdema of the lids, with hot fomentations When the reaction has subsided the conjunctiva will be found to be sealed down to the sclerotic and the vessels to have been obliterated

Corneal Opacity —What a number of these we see in India, ranging in density from a mere nebula to a

leucoma, extending through the whole thickness of the cornea. Even in the densest cases there is usually a nebular margin, and treatment should be directed in the first instance towards clearing this up. Here again we call to our aid the old stand-by—a subconjunctival injection of cyanide of mercury 1/3,000 to 1/6,000 according to the age of the patient. When the immediate reaction subsides it is kept going for a time with some mildly irritant ointment—yellow oxide of mercury from 3 to 8 grains to the ounce according to taste, being instilled into the conjunctival sac and massage applied through the lids, signs of benefit will be a blueing of the margins of the opacity, and nebulæ, even of long standing will often be completely cleared up with it. The recuperative power of the cornea, especially in childhood, is marvellous.

When the opacity has been cleared up as much as possible the question of an optical iridectomy will have to be considered. It should be performed through an anterior sclerotomy so that the scar does not impinge on the clear cornea. The method of making the incision has been described in the earlier section of this chapter which deals with glaucoma; but here a small rather than a large iridectomy is desirable.

Interstitial Keratitis.—Once seen, this condition can never afterwards be mistaken—the ground glass or steamy appearance of the cornea being quite characteristic. Like other manifestations of congenital syphilis, the natural course of the condition is very tedious, and treatment must be undertaken in no half hearted fashion, and may

be considered under the heads of constitutional and local There is a general consensus of opinion that the arseno benzol preparations have no influence on the local condi tion nevertheless they should be used as a preventative measure against the appearance of periostial modes and other manifestations of the disease elsewhere in the body Mercury and iodide of potass have just as little effect as has salvarsan on the local condition but should also nevertheless be exhibited Local treatment is for some reason generally neglected but if undertaken energetically will do more in a month than will constitutional treat ment in a year I have more than once had surprising ly good results in cases which had wandered for years from person to person without effect with the old stand by—a subconjunctival injection of cyanide of mercury, the reaction being kept up with yellow oxide of mercury ointment

Some of the Recipe of Moorfields Hospital

Leucoma Ocul

Zinc oxide gr 40
Ammon chlor gr 10
Hyd subchlor gr 10

Eye Lotion

Copper Sulph gr 2
Zinc chloride gr 1
Vin opii m x
Aqua ad ℥ j

Eye Drop

Copper Sulph
Alum
Ammon chloride
Pot Nit in powder
powder & throw it into a hot heat to make a Phiala

Take this Phiala ʒ ii
Aqua distillata ℥ iv
Glycerin ʒ viii

In Leucoma Corne

Ung for Cornea Ulcer

Eye Water

Zinc Sulph gr 2

APPENDIX

APPENDIX

DETAILS OF VISION OF 132 CASES OF INTRACAPSULAR EXTRACTION OF CATARACT ON DISCHARGE FROM HOSPITAL.

By LIEUTENANT-COLONEL HENRY SMITH, M.CH., I.M.S.
HONORARY SURGEON TO HIS EXCELLENCY THE VICEROY.

(*Reprinted by permission of the "Archives of Ophthalmology"* 1912)

Mr. Eason in the July number of the *Lancet*, 1911, writes a paper on Cataract Extraction, the basis of which is not his own personal experience but a paper published in the *Royal London Ophthalmic Hospital Reports*, vol. xvi., part iii., October, 1905, by Mr. E. Treacher Collins, a paper by Mr Charles Higgins (*Lancet*, 13|4|07), a paper published by Major Kilkelly in the *Indian Medical Gazette* of May, 1910, on twenty-three cases operated on by me in his hospital in Bombay while at the Bombay Medical Congress, and on my monograph on the treatment of Cataract.

He complains that I have not published details of any series of cases. He puts the results of these Bombay cases against the results of Mr. Treacher Collins and Mr. Higgins in their papers above noted. It should be observed that Mr. Collins's cases and Mr. Higgins's cases received thereafter treatment from their operators and were reported on by their operators, and that my twenty-three cases were not under me but under Major Kilkelly, and were reported on by Major Kilkelly; so far the conditions are not analogous. It should also be observed that they were reported on by Major Kilkelly and Dr. Pontius, hostile witnesses, a fact which will be at once apparent to any one who reads the controversy which followed. It is strange

that Mr. Eason read Mr. Kilkelly's paper and quotes it as bona-fide, but happens to have not read the remainder of the controversy in which these twenty-three cases were wiped out as of absolutely no scientific importance; neither does he quote the results of the thirteen cases I happened to have in the hospital in the middle of the hot weather when I first replied to Major Kilkelly, and which were reported in the *Indian Medical Gazette*, July, 1910 The details of these are included in the 132 cases now reported on The details of my remaining 119 cases noted below are as follows: In my recent slack season I did these cases *myself* (in the busy season I put all cases except complicated ones at the disposal of my pupils) with a view to writing this paper The eyes were selected by me before operation as normal in every respect apart from cataract. I selected 150 thus for operation. Of these 119 turned up for examination. The remaining 31, when the dressings were removed at the end of ten days, were just the same as the rest and were to be brought to my bungalow in the evening for examination, but as is so usual with the native patients, when the dressings were removed, they slipped away to their villages without informing the hospital staff. It is, therefore, not to be inferred that the eyes of these 31 patients were in any way better or worse than those examined.

They were examined for vision from ten to twenty-one days after operation. They were examined partly by myself, and partly by my wife, who is a member of the profession and an ophthalmologist. A diaphragm was used behind the lens in all these cases in order to get the stupid patients to look through the proper part of the lens, and also to shut off the glare, which is much more trying in the intracapsular operation than in the capsulotomy one in the early stages owing to the clearer medium and consequently brighter light which reaches the retina

Mr. Treacher Collins, referring to his results in the capsulotomy operation, says: "The writer doubts if by any other procedure for the removal of cataract full vision could be obtain-

ed in twenty-five per cent. of the cases with one operation." This is as much as to say that the world we live in is the best of all possible worlds. I quite agree with Mr. Treacher Collins as far as the capsulotomy operation is concerned; but considering that the intracapsular operation had been prominently brought before the profession at the annual meeting of the British Medical Association of 1903 and proved to be an eminently satisfactory and feasible operation, Mr. Treacher Collins's position is surely pessimistic.

Let us see the relative merits of this operation. In my 132 cases below noted, there was one prolapse of iris, one iris caught in one angle of the wound, and in three cases the cornea was slightly hazy. There were no drawn-up pupils. There was no case of iritis or of iridocylitis. There was vitreous escape (a bead) in three cases. There was capsule left behind in one case (this case had 6|12 vision). There were no other complications.

Details of vision.—Distant vision tested in 132 cases: /1 in 22; 6/9 in 3; 6/6 in 26; 6/5 in 22; 6/4½ in 61; 6/4 in 16.

Two were so stupid that though they could see distant objects and details of them well, we could not get them to understand what we wanted.

Details of 119 cases in which near vision was tested: Jaeger 1 in 10; thread needle with great ease, 14; thread needle, 84; thread needle with difficulty, 9.

The same two above noted were too stupid to get anything out of them.

Those tested with Jaeger type were English-speaking. The others could not read Roman or Urdu character; they were tested for distant vision with bull's-eyes, and for near vision the test used for them was to thread an ordinary cambric needle (not a darning or packing needle). The people who threaded a needle

with ease were intelligent women and tailors. Those under classes "Thread needle" and "Thread needle with difficulty" were most of them old people not accustomed to threading needles and a number of them with shaky hands. It took on an average twenty minutes to make them understand what we wanted them to do. The intelligent people could tell us at once what they could and what they could not see. The others would try the patience of a Job. Threading a needle requires more senses than sight and is thus more difficult than reading Jaeger I, but it was the most exacting test we could think of.

The lenses used were from plus 9 D. to plus 11 D. for distance. For near distance mostly plus 13 D.; a few required plus 14 D.

The patients were not examined for astigmatism but my experience is that the astigmatism in these cases averages about 0.75 D.

Mr. Eason attributes the superior vision of Mr. Treacher Collins's cases over that of Mr. Higgins's and others to the absence of anterior capsule in the former cases. By parity of reasoning the superior vision obtained in my cases is due to the entire absence of capsule both anterior and posterior, and to this also is due the absence of complications in my cases.

Mr. Higgins gives us full details of the vision of his 130 cases, but it is not fair to compare these either with Mr. Treacher Collins's cases or with mine as they were not selected before operation. But it is quite fair to compare mine with Mr. Treacher Collins's who states that his were selected as uncomplicated senile cataracts, but he only gives the general statement that 25 per cent. of them had vision equal to 6|6 without needling and that he does not needle if the patient has vision =6|18 or better.

Considering that Mr. Higgins's cases were unselected and contained the usual proportion of eyes operable though diseased apart from cataract, his results seem to me to be as good as the first-class operator by the capsulotomy method may expect. Mr. Treacher Collins states that his two hundred cases were selected as uncomplicated apart from cataract. Mr. Eason in his comparison does not note this important fact. Mr. Treacher Collins gives us no idea as to the time after operation at which his visual results were obtained—an all-important fact in cases in which the capsule is left behind owing to the steadily growing obstruction of light by the capsule; for example, cases whose vision is 6|6 a fortnight or three weeks after operation will seldom be more than 6|12 after a year and 6|18 after two years, which latter according to Mr. Treacher Collins does not require needling, a fact which indicates in itself that needling is regarded as an operation of considerable risk when operators by the capsulotomy method are satisfied with such poor vision. Mr. Treacher Collins designates 6|6 as full vision. In my observation 6|4½ or 6|4 much nearer normal or full vision.

In cases of intracapsular extraction the reverse order occurs, as after three months and more the vision is much better than it is at the end of three weeks, owing to the patient being less sensitive to glare, and owing to the cornea having resumed its normal transparency. This is shown by a comparison of the 61 of my cases (uncomplicated apart from the escape of vitreous) which were kindly examined for me and reported on by Captain Lister from one to five years after operation:

6|3 in 4; 6|3.5 in 6; 6|4 in 4; 6|4.5 in 5; 6|5 in 4; 6|6 in 33; 6|8 in 2; 6|9 in 3. Total 61.

These visual results were obtained with spherical lenses; a number of them are better than any reported on in my recent list. 56 out of 61 cases range from 6|3 to 6|6 with one operation. How does Mr. Treacher Collins's assertion stand in the face of these facts?

THE AFTER-EFFECTS OF ESCAPE OF THE VITREOUS, DURING THE OPERATION OF EXTRACTION OF CATARACT IN THE CAPSULE BY SMITH'S METHOD WITH A TABULATED STATEMENT AND ANALYSIS OF 98 CASES IN WHICH ESCAPE OF VITREOUS OCCURRED.

By Captain A. E. J. LISTER, M.B., B.S. (Lond.), F.R.C.S. (Eng.), I.M.S.

In the various discussions which have taken place from time to time, as to the advantages and disadvantages of this operation, it has been contended by the opponents of the operation for the extraction of cataract in the capsule, that one of the chief objections to this operation is the frequency of the escape of vitreous. This being the only complication, which is at all frequent, and the one which is most commonly met with by beginners in this operation, I enquired from Major Smith on my arrival in Jullundur in 1906, if any series of cases had ever been published, in which the after-effects of escape of vitreous in this operation were given. Major Smith informed me, that as far as he was aware, no such series of cases had ever been published, either after this, or the capsulotomy operation.

I then offered to undertake a research into the subject and received permission from Major Smith to make every use of his hospital records which were placed at my disposal for this purpose.

Every assistance was rendered me by Major Smith, whom press of work alone had prevented from carrying out this work before. Many thousands of cases in the operation books were gone through, and the names of patients, in whose eyes escape of vitreous had occurred, were noted Each patient was then

written to, and of them 95 presented themselves for examination. In certain of the tables it will be seen that the amount of vitreous and the remarks made at the time of operation are not given. The reason of this is, that in the operation book a note only was made of the fact that vitreous had escaped; the details are noted by Major Smith on the patients' tickets always under four headings:—

(i) Drop = 2 to 4 minims.
(ii) Trace = 4 to 5 „
(iii) Slight = 5 to 10 „
(iv) Some = 10 minims to one-third of the vitreous.

The cases will be found classified in the tables appended under these headings.

As the cases went back as far as nine years, it is not surprising, considering the many thousands of hospital tickets there were, that all the tickets could not be found. Native patients are very apt to take the ticket home with them when they go, and in a large hospital with many hundreds of patients and a very small staff, such as there is at Jullundur, it is not always possible to prevent this. Some patients being satisfied with their condition do not wait to be discharged but depart, taking the tickets with them. These facts will be well-known to surgeons in India, but they are mentioned to make the matter clear to any who do not know India. Three were found to have had escape of vitreous in both eyes, so the number of eyes examined was 98. In 90 of these cases, no portion of the capsule of the lens was found to remain; in eight a portion of it or the whole was found to be present.

Method of Examination.

The vision of the patients was tested by Snellen's test types, if they were able to read; in the case of those unable to read, who formed the bulk of the cases, by groups of dots,

which they were asked to count. Special test cards, with dots of various sizes, corresponding to Snellen's distant test types, were kindly supplied for this purpose by Messrs. Lawrence and Mayo of Calcutta. I found it more convenient to cut out various groups of dots, and to mount them on cardboard, one or two for each corresponding line of Snellen's test types. When dealing with patients lacking in education and advanced in years, this plan will be found an advantage. I have many times tested the results given by the same people, when asked to read the Snellen's test types. I find that on the whole the dots are slightly the harder test of the two, so that all the results given may be taken as absolutely correct.

I found the use of these dots more convenient than Landolt's optotype, which I also used for some cases. At first I endeavoured to test the vision with the glasses found by determining the refraction of each case by retinoscopy. I found after doing a number of cases that the astigmatism was scarcely ever over one diopter, so to save time I gave up doing a retinoscopy in every case, and gave them the plus lens they preferred, which in almost every case was a plus ten diopter lens The excellent results obtained proved the correctness of my observation, as the results obtained were all without the use of cylindrical lenses I have noted in the column of remarks, the cases in which a spherical lens other than +10 0 D. was preferred

The patients in most cases insisted on returning the day they arrived, so that on account of press of work, I was unable to do a retinoscopy in the majority of the cases. As excessive astigmatism has been alleged to be caused by this operation, it may be well to call special attention to these facts. I have also observed a number of cases in which escape of vitreous had not occurred, and I found that in them also the average astigmatism was one diopter. Owing to enforced absence on several occasions, twenty-five of the cases were kindly examined

for me by Major Smith. I had also the advantage of the opinion of Major Smith on the few cases in which disease of the fundus was present, which will be mentioned later. The chief facts revealed by this research are as follows:—

The total number examined was 98; in no case was any detachment of the retina present. Disease of the fundus was found to be present in 8 eyes. A detailed account of these is given elsewhere in this paper. The exact time which had elapsed since the operation was known in every case. It averaged 3.706 years.

The different periods since the time of operation ranged *from six months to nine years.*

Vision of Cases.

Tables will be found at the end of the paper giving the exact vision of each case, with one exception, in which by an oversight I forgot to note it at the time of examination. It may be wondered why the vision of the cases in table "A," does not quite correspond with those in table "B," being in the form shown chiefly as 6|6; the answer is that at first I did not test a patient further if he had a vision of 6|6. Later when I found what excellent vision they had, I endeavoured to estimate it exactly. It will be noted that the average standard of vision is very high indeed; thus in 61 cases in which there was no opacity of the cornea, capsule left behind, or disease of the fundus, the vision was as follows:—

6/3=4, 6/3·5=6, 6/4=4, 6/4·5=5.
6/5=4, 6/6=33, 6/8=2, 6/9=3.

I may remark here that I find in India, owing to, I think, the better light and clearer atmosphere, the patients who come to me for examination usually read a line or two more of the Snellen's test types than they do in England. I find very many British soldiers read 6|3.5 quite readily. This may account to a certain extent for the excellent vision of these cases, but it is

not the chief reason, which is the absence of an after-cataract, leaving a perfectly free pupil also the low degree of astigmatism. An important question is, does the amount of vitreous lost, exercise a marked effect on the vision obtained by the patient? The figures at my disposal are too small to admit of any definite conclusion, but they indicate, as far as they go, that it does not have any marked influence. Reference to the tables shows that it does not appear to have any marked influence. Thus we find in five cases in which the largest amount of vitreous was lost, the vision was—

6|3, 6|5, 6|6, 6|6 and 6|9,

whilst in six cases classed as "*trace*" and "*stight*" in which an average of double the amount of vitreous was lost, as in these cases we find the vision to be 6|3, 6|3·5, 6|5, 6|6, 6|8, 6|9.

The number of cases is far too small to be conclusive, but they are sufficiently striking to point out the need of further investigation on this point. Thus it does not appear from these cases that the amount of vitreous lost, provided that the eye recovers from the immediate result of the operation, is the important factor in determining the ultimate vision of the patient, that might be expected.

I repeat that the number of cases is too small to be conclusive, but they are sufficiently striking to call for further investigation; those operators, who have observed cases in which a large amount, *i.e.*, more than one-third of the vitreous, has been lost, will have noticed that the vision of such patients is often much worse at the time of leaving hospital, than the vision of those patients in which a smaller amount has been lost. I have had the opportunity of observing these patients in a number of cases after leaving hospital, and have come to the *conclusion that the vision of these patients is eventually much* better than one might expect at the time of their leaving hospital; this observation is in accordance with the above facts, and will

be of interest to those who may be intending to adopt the operation of extraction in the capsule. I think it is due to the greater distortion of the cornea which results temporarily, and to the fact that the normal tension and conditions of circulation and nutrition of the eye take longer to be re-established after loss of the vitreous, than when it is not lost. I have noticed this to be particularly the case in very old and feeble patients This fact may have led ophthalmologists who have not had the opportunity of seeing a large number of cases in which escape of vitreous has occurred, at a time when the eye has had sufficient time to completely recover, to regard escape of vitreous as more serious than this paper tends to prove it to be.

CASES IN WHICH DISEASE OF THE FUNDUS WAS PRESENT.

In 8 eyes of the 98 cases examined, disease of the fundus was found to be present. It may, be of use to future observers to mention these in detail. They will be found in table "E"; I will proceed to make a short comment on each:—

Case 1, Table "E"—Is one of syphilitic disease of the fundus and needs no comment.

Case 2, Table "E"—Presents the ordinary history and signs of malarial optic neuritis. I have seen many cases with a similar history and fundus condition. Major Smith says it is quite common in the Punjab and my smaller experience coincides with this.

Case 3, Table "E"—Is an ordinary case of disseminated choroiditis. As it was present in both eyes, and escape of vitreous only occurred in the right eye, it cannot be attributed to escape of vitreous fairly. To discuss the question fully as to whether the condition of the fundus was caused by the extraction of the lens in its capsule, as may be

suggested by the opponents of this operation, is beyond the scope of this paper. I will only say in passing, I do not think it was. Disseminated choroiditis is so commonly seen in the Jullundur clinics, that I do not see any reason to connect it with the operation.

Cases 4, 5, and 6.—These were all cases in which the lens had been previously "*couched*" and presented the typical appearance of the condition, which always follows couching of the lens. This condition has been described fully in the medical press by Major Smith. It is interesting to note, however, that apparently in some cases at least removal of the lens does not prevent the progress of this serious condition.

Case 7.—Is a case of bilateral optic atrophy. Escape of vitreous occurred in one eye only, so it could not have been the cause of the condition in one eye and it is reasonable to assume it did not cause it in the other.

It may be said that the optic atrophy was caused by the operation for extraction of cataract in the capsule, in both eyes. The disease is such a common one in the Jullundur clinic in old men, that I think it is quite as reasonable to say it was unconnected with the operation as with it. This matter needs a separate investigation It should, however, be noted here, in connection with this and the preceding case, that Major Smith always extracts a cataract if there is any hope of improving the vision for a time and that the condition may have been present in its earliest form at the time of operation.

Case 4.—The condition may possibly have been caused by the escape of vitreous, but when the facts are taken into account that the eye was operated on five years before and that the vision was 6|15 when seen, and also that in no other case in

the series has any effect been proved to have followed escape of the vitreous, it seems that it is quite likely to have had another cause. On examining these cases critically, it will appear that the case mentioned last, case 3, table "E" only, may be due to escape of vitreous.

This condition, however, I have seen so commonly in the Jullundur clinic that I do not regard it as being due to loss of vitreous. Major Smith shares this opinion. I, however, leave the truth of this opinion for other observers to prove or disprove. It may be argued that the cause of some of these conditions *may, if not loss of vitreous, be due to the disturbance of the* conditions of the eye caused by the extraction of the cataractous lens in the capsule. This argument, I think, can only be advanced as regards cases numbers 3 and 4; optic atrophy and disseminated choroiditis are, however, very common conditions in patients attending the Jullundur clinic, and I regard these cases as attributable to ordinary causes, but on this point also, further investigation is required. We arrived therefore at the conclusions that of the series of 98 eyes examined, one case of retinal degeneration may possibly be due to loss of vitreous, or to the operation of extraction of the cataractous lens in the capsule, or to a *combination of the two, and that one case of* optic atrophy and one of disseminated choroiditis may possibly be due to extraction of the cataractous lens in the capsule. If we take the escape of vitreous occurring during this operation as being about 5 to 6 per cent. in the hands of skilled operators, and allow that one case out of every 98 in which this accident happens, develops subsequent disease of the fundus, we arrive at the conclusion on the foregoing facts that loss of vitreous in this operation, provided the eye recovers from its immediate effects, is not the serious complication which it at first sight appears. It is interesting to note that this is the opinion arrived *at by Major Smith from a general experience of these cases,* apart from any definite research in this subject, some years ago.

It is especially interesting to note that detachment of the retina, the condition so generally feared as liable to occur after escape of the vitreous, did not occur in a single case. I suggest in conclusion that those ophthalmologists who state that loss of vitreous is such a serious accident in cataract operations, have been guided by the facts as known to them in operations other than those in which the cataractous lens is extracted in its capsule. It is quite probable that the eye in these operations, hampered with debris and the capsule of the lens, which, apart from those cases in which definite iritis occurs, must usually cause some degree of irritation, does suffer more serious damage, when loss of vitreous also occurs, than does the eye, which is free from any irritating material. The fact that the eight cases in which capsule was left, showed no disease of the fundus, is interesting, but it should be remarked that in only one case, was there a large amount of capsule, *i.e.*, case number ten, table C.—the other cases having only a small amount, as Major Smith always endeavours to remove as much of it as possible. On account of having a large wound, it is possible to remove most of the debris so that the condition in these cases was not quite the same as it is in the ordinary capsulotomy operation.

Having regard to the facts given here, I maintain, that though the number of cases is far too small to be conclusive, it is sufficiently large to make us hesitate before we accept any conclusions formed by ophthalmologists, who do not extract cataract by Smith's operation, as to the seriousness of loss of vitreous in this operation. Further investigation will doubtless throw more light on this important subject. I repeat, however, let us be careful before we accept any dicta by any ophthalmologist, however distinguished he may be, on this important subject, unless supported by a series of cases, an account of the operation performed, especially a statement as to whether the capsule was left behind or not, and if iritis or irido-cyclitis followed.

AFTER-EFFECTS OF ESCAPE OF THE VITREOUS.

By Capt. A. E. J. Lister, I.M.S.

Table A.

Showing—

(1) Number of years since the operation.

(2) Vision

(3) Amount of escape of vitreous.

(4) Astigmatism.

(5) Remarks noted on case sheet at time of operation.

(6) Notes on points of interest in brackets in last column.

Number of cases—36.

Number.	Name	Years since operation.	Vision.	Amount of escape of vitreous.	Astigmatism.	Remarks at time of operation.
1	Khara —	5	6 9	Trace —	—	Iridectomy.
2	Akho —	4	6/8	" —	—	Iridectomy. "Very Nervous."
3	Harnam Singh.	5	6/3	" —	—	Iridectomy. Lens lifted on spoon.

Number.	Name.	Years since operation.	Vision.	Amount of escape of vitreous.	Remarks at time of operation.
	Kara —	6	6,6	Slight —	Slight escape of vitreous. No iridectomy. He shot out lens and some vitreous on completion of incision from nervousness.
2	Bhagwani	2	6/5	" —	Iridectomy. Lens extracted on Spoon.
3	Dani —	5	9/3	" —	No iridectomy.

Number.	Name.	Years since operation.	Vision.	Amount of escape of vitreous.	Astigmatism.	Remarks at time of operation.
1	Mammon	1	6/6	Drop —	—	Iridectomy.
2	Fata —	1	6/3	" —	—	"
3	Tabo —	1	6/6	" —	—	"
4	Deva Ditta	2	6/6	" —	—	Lens dislocated by "rawal."
5	Jhandoo —	7	6/6	" —	—	Iridectomy.
6	Fateh Din	5	6/3·5	" —	+0·75 D cylinder	" Very nervous patient.
7	Achroo —	1	6/4·5	" —	—	Iridectomy.
8	Mossaddi	2	6/6	Drop —	+0·75 D cylinder	Iridectomy. (*Note.*—Left eye operated on by rawal. Never saw well with it. Now only sees hand movements.)
9	Sharo —	5	6/4	" —	—	Iridectomy.
10	Atra —	1	6/6	" —	—	Lens expelled on completion of incision with drop of vitreous.
11	Kalo —	2	6/3·5	" —	—	Iridectomy. Vision 6/3·5 obtained with +9·5 D. Sp.
12	Bhagwana	6	6/6	" —	+0·75 D cylinder	No iridectomy. (Vision 6/6 with +9·0 D. Sp. +0·75 cylinder.)
13	Ranji Das	2	6/3·5	" —	—	Iridectomy. (Cornea slightly hazy from old trachoma, above.)
14	Ako —	1½	6/5	" —	+1·25 D cylinder	Iridectomy.
15	Ganda —	1	6/6	" —	—	Iridectomy. Vision 6/6 with +9·0 D. lens.

Number.	Name.	Years since operation.	Vision.	Amount of escape of vitreous.	Astigmatism.	Remarks at time of operation.
16	Ganpat —	2	6/6	" —	+0·75 D cylinder	Iridectomy. (Vision 6/6 with +9·0 D. Sp. +0·75 cylinder.)
17	Daswandhi	7	6/3·5	" —	—	No iridectomy.
18	Inchri —	1	6/6	" —	—	Iridectomy.
19	Biro —	1	6/9	" —	—	Iridectomy. Lens extracted on spoon. Very bad patient.
20	Hukram	1	6/4·5	" —	—	Iridectomy.
21	Jamal Din	6	6/4.5	" —	—	No iridectomy.
22	Natha —	2	6/4	" —	—	Iridectomy.
23	Gangoo	5	6/5	" —	+1·25 D cylinder	Iridectomy. Very nervous patient.
24	Raman San	7	6/3	" —	—	No iridectomy. (Vision 6/3 with +9·0 D. Sp. lens.)
25	Harnam Singh —	7	6/4·5	" —	—	No iridectomy.

Number.	Name.	Years since operation.	Vision.	Amount of escape of vitreous.	Remarks at time of operation.
1	Mamon —	2	6/3	Some —	No iridectomy; lens expelled with some vitreous on completion of incision.
2	Rahmat Ali —	1	6/6	" —	No iridectomy; lens expelled on completion of incision with some vitreous.
3	Gulaba (Two eyes.)	6 ms.	6/5	"	
4 & 5	Harnam Singh.	1	6/9	" —	Iridectomy; lens extracted on spoon. Very bad patient.

TABLE B.

Showing—

(1) Number of years after operation.

(2) Vision.

(3) Astigmatism.

Number of cases—25.

Number.	Name.	Years since operation.	Vision.	Amount of escape of vitreous.	Astigmatism.	Remarks at time of operation.
1	Hira Singh —	1	6/4·5	Unknown.	+0·75 D. cylinder.	
2	Miran Bux —	7½	6/6	"	——	
3	Ghulam Haidar	7	6/8	"	+0·75 D. cylinder.	
4	Roha —	4½	6/6	"	+1·25 D. cylinder.	
5	Mohammed Din	1	6/6	"	——	
6	Roda —	6	6/6	"	——	
7	Omra —	2	6/6	"	——	
8	Mali —	5½	6/6	"	——	
9	Devi Datta —	3	6/6	"	——	
10	Ghanja —	5	6/6	"	——	
11	Badh Singh —	9	6/6	"	——	
12	Kaka Shah —	6	6/3·5	"	+0·75	
13	Iddoo —	6	6/6	"	+0·5	
14	Shah Din —	7½	6/6	"	+0·5 D. cylinder.	
15	Mehtab Singh—	5½	6/6	"	+0·75 D. cylinder.	
16	Mamon —	7	6/6	Unknown	+ 0·5 D.	
17	Dania —	3	6/6	"	——	
18	Harrow —	4	6/6	"	——	
19	Mammond —	2	6/6	"	——	
20	Abdulla —	2	6/6	"	——	
21	Juna —	3½	6/6	"	——	
22	Naonid —	4	6/5	"	——	
23	Tabo —	8½	6/6	"	——	
24	Edoo —	6½	6/6	"	——	
25	Shadi —	3	6/6	"	——	

TABLE C.

Cases in which opacity of the cornea was present.

Showing—

(1) Number of years since the operation.

(2) Vision.

(3) Amount of escape of the vitreous.

(4) Notes made on case sheet at the time of operation.

(5) Notes on points of interest in brackets in the last column.

Number of cases—10 (Nine patients. One double).

Number.	Name.	Years since operation.	Vision.	Amount of escape of Vitreous.	Remarks at time of operation (Notes in brackets).
1	Nathu —	7	6/9	Drop —	Iridectomy.
2	Sabho Davia —	5	6/8	Do. —	Iridectomy.
3	Hurkan —	4	6/12	Do. —	Iridectomy.
4	Gulaba —	6 ms.	6/12	Some —	No iridectomy.
&5					
6	Hurkan —	5	6/12	—	—
7	Suchet Singh —	1	6/15	Drop —	Lens extracted on spoon.
8	Jhandoo —	6	6/15	Do. —	Iridectomy—Nervous patient.
9	Hakom Singh —	1	6/18	Do. —	Iridectomy.
10	Ramai Dai —	6 ms.	Counts fingers at one yard	Do. —	(Corneal opacity very marked, caused by small-pox).

TABLE D.

Cases in which the capsule of the lens was left behind, owing to bursting at the time of operation.

Showing—

(1) Number of years since the operation

(2) Vision.

(3) Amount of vitreous escape (six cases only).

(4) Remarks noted on case sheet at time of operation.

(5) Notes on points of interest in brackets in last column.

Number of cases—8.

Number.	Name.	Years since operation.	Vision.	Amount of escape of vitreous.	Remarks at time of operation. (Notes shown in brackets).
1	Ako —	6 mos.	6/5	——	(Capsule needled previously).
2	Ahmad Khan.	1½	6/6	Drop —	No iridectomy.
3	Nihala —	4½	6/8	——	
4	Natha —	5	6/15	Drop —	
5	Ahmed —	6	Not noted by error.	" —	Drop of vitreous taken out of right eye on account of tension.
6	Diwan Singh —	2	6/12	" —	Iridectomy.
7	Gaunsa —	6	3/60	" —	No iridectomy.
8	Shib Dial —	1	Counts fingers only at 2 yards.	Some —	Iridectomy. (Dense after-cataract seen).

TABLE E.

Detailed notes on eight cases (seven patients, one having escape of vitreous in both eyes).

CASES WITH DISEASED CONDITION OF FUNDUS.

Case 1.—Bago. Operated on 1½ years ago. "Drop" of escape of vitreous in both eyes—both extracted on spoon. Vision=6|18.

States that he had very poor vision in both eyes before cataract developed. Had syphilis. On ophthalmic examination signs of old neuro-retinitis.

Case 2.—Para Singh. Operated on five years ago. Vision—can only count fingers. Sight was all right for two years after operation. Then had high fever with delirium. Pupillary reaction very sluggish Disc pale. Retina atrophied, probably caused by malarial optic neuritis.

Case 3.—Utman Dai. Operated on one year ago Vision—can only see hand movements. Both lenses well extracted in the capsule with a "drop" of escape in the right. Disseminated choroiditis seen in both eyes on ophthalmoscopic examinations.

Case 4.—Edoo. Operated on five years ago. Trace of escape of vitreous in right eye. Left eye lost previously from trachoma. Vision=6|15. Very stupid old man. Could give no clear history of his condition. Retina presents appearance of retinitis pigmentosa sine pigmento in an early stage.

Case 5.—Ram Singh. Operated on 1½ years ago. The right lens is noted as having been previously dislocated by the "rawal" or lens coucher at the time of operation. It was noted also as having been expelled on completion of the incision with

a "drop" of vitreous. Note made "Bad patient." Vision=6|15. On ophthalmoscopic examination the typical condition of retinitis pigmentosa sine pigmento, which always follows couching of the lens.

Case 6.—Hako. Operated on two years ago. Vision *nil.* Drop of escape in the left eye. Lens noted as dislocated at the time of operation. The same fundus condition as in case No. 5 but more advanced

Case 7.—Khuda Bux Age 60 Operated on 4½ years ago. Escape of vitreous in one eye only, amount not noted. Both lenses extracted in the capsule. Primary optic atrophy in both eyes.

NOTE.—The details of eleven cases are not given. The cases were all tabulated, and the data given elsewhere were calculated from these cases. Unfortunately the case sheets with table attached, have been lost, in the course of packing up and destruction of accumulated papers necessitated by a change of station in India. No case had any retinal disease or detachment and all had good vision.

LATE RESULTS OF INTRACAPSULAR CATARACT EXTRACTION.*

BY DR. ARNOLD KNAPP, NEW YORK.

(*Reprinted by P rmission of the* ARCHIVES OF OPTHALMOLOGY.)

Without taking up the question of vitreous loss it is stated that the intracapsular cataract operation unduly traumatizes the eye, displaces the pupil and sets in action degenerative changes in the vitreous which result in ultimate damage to the eye; some even claim that the posterior capsule should be retained as it

* Read at Convention of English-Speaking Ophth., London, July 14-17, 1925.

serves as an important support for the vitreous. These questions can best be answered by the examination, after a number of years, of eyes in which an intracapsular extraction had been performed.

For this purpose I have followed up and re-examined as many as possible, of the 200 successive intracapsular cases, which were operated on by me between 1910 and 1919. These cases were all extracted by the method of preliminary subluxation with the blunt capsule forceps and were described in detail in the ARCHIVES OF OPHTHALMOLOGY in 1915 and 1921.

The following report gives the late results in 85 cases as to vision and to changes in the structures of the eyeball, particularly in the vitreous.

Results: Of these, 16 cases have died; vision, at last examination or from report of relatives, had remained good. In 57, vision was found to be as good as after operation or had improved; in 5 of these there had been slight vitreous loss.

In these 57, the cornea was perfectly clear; the coloboma was generally regular and there was no updrawing of the pupil, except in a few where the pupil was slightly distorted from posterior synechia, from anterior adhesion of one pillar, prolapse of iris or of vitreous loss without affecting the vision.

In the pupillary area the vitreous usually presented in the form of a membrane distinctly seen with the slit-lamp so that it seems to me to be quite proper to speak of a hyaloid. This membrane sometimes bulged forward like a wavy globular mass, or it presented as a more or less flat membrane at or posterior to the level of the pupillary margin. It was either intact, covered with a number of fine brown dots, or there were one or more irregular holes, through which the vitreous presented in irregular masses (in these cases there was no question of vitreous loss at operation). This membrane was

absent in cases with vitreous loss. Back of this hyaloid membrane, the slit-lamp revealed a definite gap before the limiting vitreous structure was seen.

The conditions for the examination of the vitreous in these intracapsular cases are naturally perfect and the vitreous was found unusually clear. A slight haze after operation disappeared in a few weeks. There is no question that the vitreous is much more free from opacities in these cases than in the capsulotomy cases. This is to be expected by the greater freedom from irido-cyclitis and the absence of reaction which sometimes follows the discission. No changes were found in the deeper vitreous layers with the slit-lamp other than those described by Vogt as senile.

I was able to find only two references in the literature on the conditions of the vitreous after intracapsular operation, namely, Munoz Urra (*Archivos de Optalmologia Barcelona*, XXII., Dec., 1922), and Elschnig (A. J. O., p. 355, 1925) who examined the vitreous with the slit-lamp after the Barraquer operation.

Munoz Urra speaks of a "perfectly empty space remaining after total extraction Immediately after operation small infiltrations produced by leucocytes can be seen which are due to slight attacks of cyclitis, but after the first week the vitreous is entirely normal. However, in some cases this vitreous infiltration lasts for a longer time. In a normal operation the infiltration disappears quickly and the transparency is afterwards perfect. These small infiltrations do not prevent perfect vision. Sometimes the vitreous makes a small hernia through the pupillary opening. In this case pigment from the iris is seen on the surface of the hyaloid, where it remains forever."

According to Elschnig, "the vitreous almost always forms a rounded mushroom-shaped prominence which projects into the anterior chamber seldom covered by an intact vitreous mem-

brane but generally by one that seemed to be riddled with small holes. Even in many cases in which no vitreous entered the anterior chamber free floccules of vitreous could be found as far forward as the posterior surface of the cornea. In all cases of extraction within the capsule but least in the Barraquer method, the vitreous membrane and the deeper vitreous layers seemed to be studded by veils, threads and pigment dots. Only further observations over a period of years can show whether such vitreous conditions are prejudicial to the integrity of the eye."

In three of my cases excessive proliferation of the vitreous projected into the anterior chamber through gaps in the hyaloid membrane. These masses were definitely cloudy but did not interfere with the patient's vision and in the course of years underwent but very little change. These cloudy proliferating changes are well known in capsulotomy cases where the capsular epithelium has been held responsible and which the above observation shows not to be the case.

Important complications in the ordinary cataract extraction with needling are *glaucoma* and *detachment of the retina.*

Glaucoma was found only in one of my cases that of R. 107 in whom six years after a successful extraction the patient presented herself with the signs of heterochromic iritis, optic atrophy and glaucoma. It is not definite that the glaucoma was referable to the method of operation. In two cases of chronic glaucoma and cataract, after extraction of the cataract in the capsule, the glaucomatous tension was relieved. It is perhaps worthy of comment in this connection to state that in chronic glaucoma the cataractous lenses are readily subluxated with the capsule forceps and that extraction in the capsule is easily performed. On the other hand, in a third case where the

glaucoma also antedated the intracapsular operation, glaucoma persisted after the extraction and required a secondary operation.

Detachment of the retina was not observed in a single re-examined eye.

Three cases of *retinitis pigmentosa* were operated on. The re-examination showed no change but increased deterioration of sight and greater contraction of field

Detachment of the choroid observed in a number of cases after operation never persisted.

Blood staining of the hyaloid from hyphema at the time of operation occurred in a number of cases and was unusual as the blood color in contact with the hyaloid remained unchanged for a long time, often for several months.

Inflammatory reactions on the part of the iris and ciliary body in these intracapsular cases presented the following changes: The pupillary margin becomes attached to the underlying hyaloid to a varying degree in the form of posterior synechia. The hyaloid shows corresponding faint opacities which may extend over the entire pupillary membrane, the pupil under these conditions is distorted and somewhat updrawn (3 cases). If the reaction is greater the cornea clouds or more correctly speaking the initial corneal opacity, the so-called keratitis striata, steadily increases (2 cases). There is only moderate ciliary congestion and the symptoms are not marked. The periphery of the cornea becomes vascularized, the pupil contracts and is updrawn, tension is not particularly affected. The clinical picture is rather that of a nutritional or degenerative process. One naturally asks whether traction on the ciliary processes in the subluxation manœuvre and subsequent extraction is a factor. I do not think it is, if the eye is a normal one. In the two cases in which this occurred, the patients were old

and feeble, and in one acute glaucoma had preceded the cataract for some years. In using the blunt capsule forceps one can gauge the amount of traction exercised on the ciliary processes, and it is my practice if the suspensory ligament does not readily tear, to desist and apply the toothed capsule forceps.

Fuchs in an article on "Erkrankung der Hornhaut durch Schadigung von hinten" (*v. Graefe's Archiv,* Vol. xcii, 1916, p. 145) on page 208 speaks of sclerosis of the cornea in old people after operations. The opacity of the cornea was superficial, suggestive of epithelial dystrophy and in the later stages clouding occurred from lamellar deposits on the cornea. In other cases swelling (Quellung) of the corneal lamellæ took place rarely with hyaline deposits. Fuchs regards the clinical cause of this sclerosis to be a nutritional disorder after intraocular inflammation or operation. While one case developed corneal dystrophy as was reported in the original paper, the cases to which I have just referred and which numbered two, the opacity of the cornea was deep and there were no superficial changes in the corneal epithelium.

In general on looking over the *late results* after this form of intracapsular extraction it seems that if the primary result is good, excellent vision is retained as the cases show that were re-examined from 10 to 15 years after operation and that the patients have surprisingly little trouble from their eyes. There is no evidence of degeneration of the vitreous which led to pathological changes in the eyeball. The freedom from vitreous disturbance in these cases shows the correctness of the belief that occasional but definite reaction and damage to the eye occur from retained capsule and cortex or from one or more needling operations. There is a remarkable freedom from glaucoma, from retinal detachment and from the sequellæ of iridocyclitis except for the serious but fortunately rare complication of sclerosis of the cornea.

(From Memoirs of the Royal Academy of Surgery, I, Tome II, Paris, 1748.)

ON A NEW METHOD OF CURING CATARACT BY EXTRACTION OF THE CRYSTALINE.

By M. Daviel.

(Translation by the late Dr. D. W. Greene of Dayton, Ohio.)

It is not astonishing that diseases of the eye, especially Cataract, have been so little studied, and treated with so little success, if one reflects that, by a sort of fatality, the surgery of this organ has been, it may be said, abandoned to Empirics.

Skilful men of the past century have liberated us from the error of the ancients as to the nature of the Cataract. The ancients believed that Cataract was formed by a membrane, and the membrane was formed by a thickening of the aqueous humour. But now we know that Cataract consists in an opacity of the crystaline lens, and as this is well known, and contested by no one, I will not undertake to give the proof. This discovery is principally due to M. Lasnier, member of the College of Surgeons of Paris, long before M. M. Maitre Jaux and Brisseau knew of the fact, but it was essentially conformed by them. (*See* Researches on the origin and the progress of Surgery Vol. II, p. 204.)

Some authorities have written on this disease, but very few have performed the operation which it required, and there are but few surgeons of note and standing who have applied themselves to it.

If I used the ordinary language of oculists, I should distinguish several kinds of Cataract but as this multiplication of division appears to me useless, I will admit only two, a true or benign kind, and a false or complicated kind.

True Cataract is an opacity of the crystaline, entire or in part, and unaccompanied by any other disease of the eye.

It is not the colour of the crystaline which determines the benign species; for that, the eye must be healthy otherwise, that the pupil dilates to one half or a third or a quarter, and that the patient can distinguish light or shadow.

False Cataract (the bad kind) is opacity of the crystaline with immobility of the pupil, which is either too dilated or too contracted. The patient cannot distinguish the shadow of any object; and these symptoms announce very often the gutta serena. There may be also severe pain in the head, an obstinate ophthama etc. (Glaucoma).

The ancients who always regarded Cataract as a membrane, invented means of couching it, in harmony with their opinion of its nature. Some employed a round needle about which they imagined they could wind this supposed membrane like a ribbon. Others devised very pointed needles in order to make a smaller wound in the sclerotic, some made use of a cutting needle to divide the tendrils, which, according to them, attached the Cataract to the ciliary processes. Finally, Freytagius invented a species of spring forceps with needle points. With this instrument he proposed to extract the membraneous Cataract from the eye.*

In 1745, being at Marseilles and believing that pointed and cutting needles were the cause of the accidents that occurred in the ordinary couching, I desired a flat needle blunt at the point in the form of a small spatula. I believed that I could succeed better in depressing the Cataract after the puncture than with the ordinary needle; but experience taught me to the contrary, and the operation which I am about to describe has contributed not a little

---

* *See* the different needles for the extraction of Cataract figured in *Heister, Institute Chir. in Vol. I*, p. 580, 1750.

to cause reflections to which I owe the method which I now employ.

A hermit of Provence having been operated on unsuccessfully for Cataract on the right eye, came to me at Marseilles and asked me to operate on the left one. I was no more successful than my predecessor. Making use of the ordinary needle, cutting on the side, I not only could not depress the Cataract but it happened that several portions of the crystaline passed into the anterior chamber which I saw filled with blood, so that I could not see my needle, and I was obliged to withdraw it without being able to complete the operation. This accident decided me, following the example of M. Petit* to open the transparent cornea, in order to evacuate the blood the fragments of the lens which had passed into the anterior chamber. This I did by passing a curved needle into the chamber. I enlarged the first opening into the cornea with curved scissors. By this means all that was in the anterior chamber was evacuated, the pupil seemed clear and the patient immediately distinguished objects which were presented to him.

But as the eye had been too much manipulated by the first operation I had made, the second failed, being followed in two days with suppuration of the organ. The failure was doubtless caused by the dragging on the interior membrane and disturbances of the vitreous humour.

The case which had fallen into my hands, made me form the resolution not to operate any more except by opening the cornea and thus to reach the lens in its capsule, in order to make it pass through the pupil into the anterior chamber and thence to remove it from the eye. I performed this operation for the first time, on a woman. I opened the

---

*M. Petit practised in 1708, section of the cornea for extraction of the lens which had passed into the anterior chamber. *See* Memoires de l'Academie Royale des Sciences, 1708.

cornea as I have described, afterward passing the little spatula over the upper border of the Cataract, I detached it and drew it in pieces with this instrument out of the eye. The pupil appeared clear, the patient had not the slightest accident, and fifteen days afterward was entirely cured.

This success encouraged me to continue this method. I succeeded with it in four other cases, but it did not apparently reach perfection, in several respects since having been followed in several other cases, by results which were not so happy. I felt then the necessity of trying some new mode, at least to be able to compare the different methods and find if possible one exempt from the too frequent accidents.

I decided to perform the operation with two instruments, the first with steel shaped like a delicate bistoury should serve to open the slerotic at the usual point; through this opening I introduced the spatula toward the upper part of the lens between it and the posterior surface of the iris, and then depress the Cataract with greater facility and promptitude.

A large number of operations made in this way, several of them impressed by distinguished masters of our art have been followed by good success. I believe myself justified in assuming that this method was preferrable to the other, that it would bear comparison in regard to the instruments employed as well as to the technique with all of those which have heretofore been devised.

I have made use of all the different kinds of needles; I have also varied the operation, sometimes directing the needle behind the lens, in order to rupture the posterior face of the capsule, and push the lens into the vitreous humour; sometimes I have tried to open the capsule in its inferior part in order to press the Cataract by this opening into the vitreous

humour. Again I have tried to pass the little spatula over the anterior part of the Cataract which I depressed easily; but I observed that the operation in this latter mode did not succeed perfectly only when the capsule of the crystaline was thin and very delicate; for then the lens depressed into the vitreous humous does not easily rise again, and so there results the same accidents which follow all kinds of operations. It is not the same when there is a tough membrane, a soft Cataract, and at the same time the vitreous humour a little too thick, then the irritation of the membrane caused by the needle and the necessary disturbance of the vitreous humour, occasioned often grave accidents, sometimes even suppuration and atrophy of the organ.

Although I had tried, thus to say, all the modes for operating for Cataract without being satisfied with success obtained, I projected further trial in order to learn precisely what injuries of the interior parts of the eye would result from operation made with any sort of a needle. The results of my observations are very different; in fact, after some cases of good results, the pupil being clear, the lens was found at the lower part of the vitreous humour without any derangement of the interior part; but in other cases, the fragments of the lens, broken off by the needle, passed through the pupil into the anterior chamber and in these cases the more I moved the needle in the eye the less it became clear. Often I found it extremely difficult to make the lens come out of the capsule and finally it has happened to me to find it pushed in between the retina and the choroid, these two membranes torn in several places.

Henceforth I doubted no longer that the derangement of the different parts that I had observed on the eyes of cadavers, derangement of many varieties, were the cause of the disorders which the living experienced only too frequently, and I believed myself obliged to consider that they depended

not only on the introduction of a needle into the eye whatever shape it may have but much more on the resistance of the membrane and above all on the lens according to the place it may occupy after the depression.

In truth, with but little reflection on the form of different needles, it is easily to be seen that those which are fine and pointed only pierce and that not having sufficient surface they cannot bear sufficiently on the Cataract to push it down to the bottom of the vitreous humour, or at least they should only occasion the accidents which result from a piercing of delicate parts. In general, needles with an edge divide vessels and thus often cause an infusion of blood in the eye which prevents the completion of the operation, and those which are flat, blunt and rounded may bruise and tear the internal membrane and thus cause accident. Independent of what may be attributed to the needle, it is very plain that the lens injures by its presence the different parts of the eye, dependent as I have just stated, upon the different locations in which it may be after depression; I omit also accidents that the most perfect operator cannot avoid, with whatever care he may exercise.

In spite of all, I believe that I should continue to prefer my last method, which consists in employing a cutting instrument, followed by a flattened needle to depress the Cataract, until the idea of the operation made on the Hermit had reached in my mind a certain degree of maturity. But the case I am going to relate decided me.

On the 8th of April 1747, I was called to an individual in whom the Cataract appeared benign, and the eye in favourable condition for the operation. I began by operating on the left eye in which the Cataract appeared to be the most solid; however, it was not possible to depress it. The pupil was irregular after the operation and the patient could see absolutely nothing. I proceeded then to the right eye

with which I had equal trouble. Not being able by any effort, I decided to open the cornea as I had done with the Hermit, I dilated the opening, I elevated the flap with a small forceps, and I passed through the pupil my little spatula and with it drew from the posterior chamber, all the pieces of the lens which had been separated by the first operation. This extraction was followed by the escape of a portion of the vitreous humour which had been disturbed by the preceding operation; but in spite of this, the patient perceived objects well after the operation, there were no bad consequences and the cure followed soon.

Since that time, and for the three following years, I practised this operation some time, in order to accustom myself to it, but it was only during a journey which I made to Mannheim, to treat the Princess Palatine of Deux-Ponts for a disease of the left eye, that I definitely resolved not to operate for Cataract in future except by extraction of the lens.

I had occasion to stop some time at Liege. I made there six operations by this method with entire success, and in one which I made at Cologne, on a priest, the success was much more striking since the Cataract was as soft as jelly. This priest could say mass fifteen days after the operation.

M. de Vermale, associate of the Academy and Chief Surgeon to the Elector of the Palatinate, has given an account of my operation which he witnessed at Mannhein, in a printed letter, addressed to M. Chicouyean, first physician of the King. Since that time, I have continued to perform this operation and I can count to-day the 16th of November 1752, two hundred and six operations of which one hundred and eighty two have been successful. This, I think, is a pretty

---

*His first 206 extractions without cocaine and without antiseptics with roughly 17 per cent. failures was very good—*H. Smith.*

good showing for an operation which is, thus to say, only in its infancy.

Here is the technique. When it is recognized that Cataract exists, it matters little so far as concerns this operation, of what nature it may be, soft, hard, of different color. The operation will equally succeed, provided that the eye be, in other respects, healthy; because the object of the operation is the extraction of the lens from its capsule; this *is easily done by the procedures which I am going to detail.*

I prepare the patient after the ordinary well-known manner. On the day of the operation, I lay out the dressings, which consist of bandages, compresses, small pieces of linen, plaster in oval shape, small sponges, pledgets of cotton, *warm water and wine.*

The instruments which I employ are (Plate XIX) a pointed needle, cutting and curved, having the form of a lancet, designed to make the first opening (Fig. 97). A blunt needle, cutting, and also curved, with which to enlarge the *opening* (Fig. 2). *Two pairs of convex scissors, curved,* (Fig. 3) a small spatula, gold, silver or steel, lightly curved, to lift up the cornea (Fig. 4). Another small pointed needle, cutting by two edges to open the membrane which covers the lens anteriorly (B). A small curette gold, silver or steel to facilitate sometimes the exit of the lens, or to draw away fragments of this body, when such remain in the pupils. A small forceps for removing portions of membrane which may present themselves.

All these instruments are arranged in order on a tray, and entrusted to the hands of a student, who will give them *to the operator as he needs them.*

Everything thus disposed of, the patient is placed in a chamber moderately lighted, so that the pupil may not be made to contract too much, and that the light may not

enter the eye too forcibly after the operation and thus dazzle or injure it.

The patient is seated on a rather low chair or on a stool; the operator sits in front of the patient, somewhat more elevated, so that in operating, he can rest his elbow on his knees. The patient's other eye is covered with a bandage, then an assistant, standing behind the patient rests one hand on his forehead and extends two fingers to the upper lid and places his other hand under the chin.

The surgeon depresses the lower lid (Plate XX A) and taking the first needle introduces it into the anterior chamber near the sclerotic, avoiding meanwhile wounding the iris, carries it as far as the upper edge of the pupil, he withdraws it gently and takes the blunt needle, with which he enlarges the incision by carrying this needle to the left and right so as to open the cornea the form of a crescent, following its circular form (C. C.). But as the cornea will be then somewhat lax; the surgeon takes the curved scissors (D) introduces the blunt blade between this membrane and the iris and completes the section on one side and the other carrying the incision on each side a little above the pupil. It must be observed that the curve of the scissors should correspond with that of the globe and that thus to correspond with the curve of the cornea, there should be two pairs, one for each side.

The surgeon takes next the little spatula, (F) with which he lifts up gently the flap of the cornea (G) and divides with the pointed and cutting needle the capsule of the lens. Sometimes it is necessary to remove this membrane entirely if it should be thick and wrinkled for fear that it may block the pupil; this membrane being well divided it can be removed with the forceps.

After having divided the capsule which envelopes the lens care should be taken to introduce the spatula between this body and the iris in order to entirely detach the Cataract and facilitate its exit, then the flap allowed to fall in order to finish the operation.

It is now that the surgeon should exercise all his prudence *since the veil which excluded the light is drawn.* For this the globe of the eye should be gently pressed, without fatiguing it, (See Plate II the finger applied) in this way rupture of the posterior layer of the lens, which serves as a dike, is avoided and thus escape of the vitreous humour prevented; with joy the pupil is seen to enlarge *little by little,* the lens having presented its edge glides into the anterior chamber and then unto the cheek. Then the pupil clear, the veil which prevented light is removed and the patient, just before plunged in darkness, sees again the light with as much astonishment as satisfaction.

The iris sometimes prolapsed by passage of the lens, is now restored, and the patient bandaged so as to prevent too great impression of light.

If the cataract was so soft and glairy that it broke and burst *the pieces could be removed with the little curette which the* surgeon should pass around the pupil as many times as necessary; after which the flap of the cornea should be exactly replaced, then the eye is dried with a soft fine sponge, moistened with warm water and a few drops of brandy. A piece of plaster is applied over a pledget of cotton and the whole covered by a bandage loosely applied. The patient's head is covered with a napkin, he is put to bed in a dark room lying if possible on the back and in a curtained bed. The eye is to be fomented with an.....decoction two or three times daily, or as may be necessary. Bleedings and rigid diet are not to be forgotten and the patient treated in every way according to ordinary rules.

Whatever preference I believe due to this method of operation, I cannot deny that it may have its special accidents; but they are of such a nature as to be easily remedied and some of them can be prevented. For example, there may be an escape of a portion of the vitreous humour during the operation, but this may almost surely be prevented, by pressing but lightly when the lens is extended. Cases may be met with in which it appears necessary to apply stronger pressure and if the capsule is adherent to the iris the adhesions may be broken up with the spatula and the pupil prepared little by little for the exit of the lens.

If it happens that from a wound of the iris, blood is forced into the anterior chamber, it escapes easily by the incision, and the operation is in no manner prevented. This accident happened to me when operating in the presence of M. M. le Drau, Morand, La Faye and several others. The eye was none the worse for it and the patient saw with it as well as with the other which was operated on soon after.

That the whole aqueous humour escapes immediately is a necessary inconvenience, and is without consequence; but if the needle which opens the cornea is withdrawn too quickly, the iris may come with the aqueous humour and this membrane is caught between the two edges of the wound. It is very easy to disengage it, by elevating gently the cornea with the spatula sometimes even the natural movements of the eye causes it to return. In the course of the case also the iris may prolapse through the opening and form a staphyloma, but this can be remedied by causing the iris to retract and this accident is almost certainly avoided by avoiding too tight bandaging. The accident is generally the result of too great pressure.

I think it will be admitted without hesitation that these accidents are of trifling moment in comparison with those which may follow the usual operation, a comparison of the methods will show more considerable advantages:—

1. *In operating by the old method it is necessary to* wait until the Cataract is ripe, and often it does not become so; *by this method the Cataract may be extracted early, and* without waiting for maturity.

2. In depressing the Cataract although solid, it may rise up again after the best performed operation and even a long time after and it cannot be denied that this accident happens sometimes. Here, on the contrary, we can be sure of a Cataract which is removed from the eye; there can be no re-ascent.

3. By the ordinary method the Cataract passes sometimes entire or in part, by the pupilliary opening into the anterior chamber; this happens sometimes at the time of the operation, and it has been known to occur several years afterwards. The cornea not being opened the lens is a foreign body in the anterior chamber, where its presence may be very inconvenient, and even cause the loss of the eye, or at least demand another operation. By my method the Cataract is entirely withdrawn from the eye, it having been made to pass through the pupil.

4. In operating upon a soft Cataract by the ordinary method, the operation often fails of perfect success, by fragments of the torn membrane, and also some portions of the lens which may block the pupil and oppose to the rays of light the same obstacle as the entire Cataract. By my method I have extracted soft Cataracts, I have removed some that resembled hydatids, and I have detached those which were adherent.

5. In order to depress the Cataract by the old method, it is necessary to pass into the vitreous humour and to break up the ciliary bodies which are sometimes torn by the more or less repeated movements of the needle, and this cannot take place without serious consequences, nor can it be avoid-

ed even by employing a blunt and dull needle. It is easy to see that this accident cannot take place by my method.

I believe I have said enough to prove the excellence of this method, and that it deserves the preference. It has received the endorsement of masters of the art before whom I have operated, and some of them have adopted it. It only remains for me to prove that I am the originator of this operation, of which it seems (by what motive I do not know) some wish to dispute the discovery.

The ancients have all held that Cataract was a membrane formed in the anterior chamber from the aqueous humour, that it has been recognised that Cataract consists in an opacity of the crystaline lens. It is useless, then, to look for extraction of the Cataract in any of the ancient writers. It may be objected perhaps that the ancients holding Cataract to be membraneous, had designed extraction of the membrane, and that this is proven by the writings of several Arabian authors, such as Avicenna and Rhases. It is not difficult to reply to this. Admitting this operation to have been performed it would only be a membrane which was removed, and this would not at all diminish the merit of extraction of the lens, which is quite a different matter.

In admitting the passage from Avicenna which M. Thurant, Bachelor of Medicine of the Faculty of Paris, cites in his thesis, 1752, on extraction of the Crystaline, nothing can be found in it which takes away from me the merit of the discovery. Here is the quotation from Avicenna.—

"Here Latin——to Al-Buwineus——then M. Thurant remarks afterward that: Agua.....

For in examining the text, no description at all is to be found of Cataract as we understand it, and even should I admit that Avicenna has spoken of a Cataract, and of its

extraction, had he left for us any clear and express description of the performing of the operation? Ought I not to have the honor of having renewed it, and of having published the details of practising it?

It is only necessary then to give attention to the testimony of those writers who have treated of extraction of the Cataract. I know only two, M. M. Freytag and Heister. The first had only in view membraneous Cataract, and he has been satisfactorily refuted by M. Heister, who throws doubts upon his operation. The second M. Heister, says in his Surgery (Part 2, Sect. 2, Chap. 55, p. 577-8) that it has been reported to him that M. Taylor an English occulist, had boasted, *gloriatum esse*, of being able to extract Cataracts adherent behind the iris by an incision made in the cornea; but M. Heister says nothing more, announces only a hearsay and a possibility. It is true that M. Thurant adds to this statement of M. Heister that M. Taylor really performed this operation several times in the year 1737; but I fear this is a gratuitous allegation, and I believe myself able to furnish proof of this.

M. Taylor being in Vienna in 1750 operated in the presence of the celebrated Van Saretenb a member of this Academy and M. Taylor cannot be suspected of the negligence of having ignored the operations which he had performed; M. Van Suriten would certainly have been informed of them, nevertheless in a letter of April 1751, in response to one M. de Vermale had written him, in sending a copy of his dissertation, not only does he make no mention of M. Taylor, but also admitting that by following my method many difficulties are avoided, he adds:—"The sole difficulty is to make the lens extrude, above all when of considerable size and at the same time tolerably hard, for it seems to me that then some violence will be done to the iris; there are cases in which the pupil is small and not very dilatable; meantime

multiplied successes of an operation make all objections to it vanish and a skilful hand accomplishes many things which present great difficulties to others. If M. Van Suriten had seen this operation performed, he would not have expressed himself thus.

This celebrated physician is not the only one who has accorded me the honour of this operation; I must add the favourable report which M. Walken, physician of the Elector of the Palatinate has made, and the testimony of M. Manchard, Professor of Medicine at Tubingen first physician to the Duke of Vitemburg, and incontestably the most renowned oculist of Germany.

I expect from the public that justice which I have the right to hope for, and I have believed that I could not do better, as a means of gaining it than to trust my discovery to the annals of the Academy, and I conclude by giving notice that this memoir is, properly speaking, only an abridgement of what I hope to publish in a complete treatise on diseases of the eye.

REMARKS ON THE MEMOIR OF M. DAVIEL.

I.

It was natural that the Academy should occupy itself with the success of M. Daviel. So for assurance it has made researches, the first of which were as to the operations at Rheins, to the number of forty three, in November 1751. To this end a letter was addressed, Jan. 15. 1753 to M. Cague, one of its correspondents and a resident of Rhein. He replied that he could not report as to the conditions of all the patients of M. Daviel, several not being in the city. From an examination which he has made of thirty four of these examinations, he has found that seventeen had been perfectly successful There were eight in which success was

mediocre, and nine in which loss of sight followed. Of this number six of the eyes operated had the pupil immovable (Sans resort) and in two, there was a staphyloma which had gradually disappeared.

II.

M. Garangeot had assured the Academy that he had performed this operation on one eye of a soldier with good success. He made use of a lancet and of scissors for section of the cornea, and of a curette to dislodge the superior part of the lens.

III.

The number of instruments used by M. Daviel for dividing the cornea has been objected to, for he made use of four, which much prolonged the operation. M. Palucci, surgeon to their Imperial Majesties has proposed a single instrument, and one was presented to the Academy by M. LaFaye, another of the same kind was presented by M. Poyet, surgeon of the Hotel Dieu.

INDEX

[*The figures refer to pages*]

A

Accidents, during operation, 125
Acoin, 40
Adrenaline, 61
Afghan war knife, 71
After-cataract *from capsulotomy*, 44, 46
extraction of, 196
making the hole in, 194
the nature of, 189, 190
and needling, 45
needling in, 194
proper time of treatment, 192
risks of operation on, 191
the treatment of, 187
After-complications—
choroidal hæmorrhage, 181
glaucoma, acute, post-*operative*, 185
iritis and iridocyclitis, 179
late pain, 187
prolapse of iris, 171
retinal detachment, 183
septic infection, 184
the treatment of, 171
Ambidexterity in incision, 81
Anæsthetic, *the choice of*, 61
general, 61
local, 61
Atkins, Thomas, 8
Atropine, 38, 94
in cataract complicated by glaucoma, 53
on pupil before operation, 60
in the treatment of cataract, 24, 25
Avicenna, 276

B

Bear, G. J., 206
Barraquer, and pneumatic forceps, 56, 116
Barraquer's claims *re.* cristfaco, 150
operation, a study of, 129
pump, 145
routine incision, 89
vacuum spoon, Author's view of, 123
Black cataract, 19

C

Cataract, artificial ripening of, 47
anterior polar capsular, 26
anterior polar subcapsular, 21
black, 19
calcification in, 20
in children, 54
classification of, general, 8
circumscribed, 21
complicated, 29
complicated by—
Bright's disease, 37
choroiditis, disseminated, 35
conjunctivitis, chronic, 31
corneal opacity, 31
dacryoystitis, 31
diabetes of later life, 37
diseases of choroid, 34
diseases of retina, 34
glaucoma, 32
treatment of, 51
gout, 37
lens, couched, 36
myopia, high, 36
night-blindness, 34
posterior synechiæ, 32

Cataract complicated by— (*Contd*)
retinitis pigmentosa sine pigmento, 37
synechiæ, posterior, 32
synechiæ of old iritis, 51
in children, treatment of, 54
conception of, old, 264, 265
congenital, primary, 20
in diabetes of youth, 29
discoform, 17
extraction of, 55
false, 265
following iridocyclitis, 28
glaucomatous—
diagnostic importance, 27
signs, 27
hard, 16
hypermature, 17
from heat exposure, 28
hypermature, 14
treatment of, 50
ab initio, 17
hard, 17
Morgagnian, 16
immature—
and capsulotomy, 48
and needling, 49
signs of, 12
treatment of, 13, 43
incipient or prodromal stage, 10
diagnosis of, 12
signs of, 11
symptoms of, 10
treatment—
abortive, of, 38
Author's method of, 40
case reports on, 42
intumescent, 14
from iridocyclitis, treatment of, 51
in juveniles—
main types of, 22
treatment of, 54
lamellar, 21
mature, 14
treatment of, 50
Morgagnian, 15
Morgagnian—
diagnosis of, 15

Cataract, Morgagnian— (*Contd*)
signs of, 14
reaction of pupil in, 6
treatment of, 16
naked-eye examination of, 3, 4
posterior polar, 21
primary, classification of, 8
primary senile, sub-classification of, 9
with scotomata, retinal, 35
secondary, 23
traumatic, 23
true, 265
from ultra-violet light, 28
in young adults, treatment of, 54

Canthotomy, external, 62

Capsule burst during delivery, 126
forceps—
construction and correct use of, 160

Capsulotomy operation (*see* Daviel's operation)
and after-cataract, 44, 46
in glaucomatous cataract, 51
vs. intracapsular extraction, 210
technique of, 165

Children, cataract in, treatment of, 54

Choroid, detachment of, 262

Choroidal disease with cataract, 34

Choroditis, disseminated, with cataract, 35

Cocaine, 61
in the treatment of cataract, 24

Complicated cataract, 29

Complications during operation, 125

Congenital cataract, 20

Conjunctivitis, chronic, and cataract, 31

Conjunctival tear, during operation, 125

Control of orbicularis, Author's claims *re.*, 70

Corneal opacities, 31
ulcerations, 228, 229

Cruickshank, Capt., I M S., 146
and facœrisis, 151

Curare, 92

Czermack's flap, 84, 85
operation and prolapse of iris, 84
size of incision, 86

D

Dacryocystitis, 31

Diabetes of youth and cataract, 29
of later life and cataract, 37

Disciform cataract, 17

Darien of Paris, 39

Daviel's operation, 163
accidents in, 274
advantages claimed, 275
Authors views on, 123
case report of, 270
claims of, 206
claims to originality, 276
evolution of, 265
incision, size of the, 88
technique of, 164
his own technique, 271

Daviel's memoir, remarks on, 278
original article, translation of, 264

De Wecker's scissors, 98

Douche, McKeown's, 167

Down's mercury vacuum apparatus, 143

Dressings, application of, 125

E

Eason, Mr, 237

Elschnig, 260

Erisiphæ, 100

Erisifaco, 129
and Barraquer's claims examined, 145
and Barraquer's claims—
Author's conclusion *re.*, 159 observations on, 150
regulation of, in practice, 138
vibration, claims of, 137

External canthotomy, 62

Extraction, intracapsular—
details of vision, 237
and escape of vitreous, analysed, 242
late results of, 258
proper incision for, 79
size of incision, 86
vs. capsulotomy, 210

Eye, clinical examination of, 1
a soft, 128

F

False cataract, 265

Facœrisis and Capt. Cruickshank, 151
observation of practical working, 143

Field of operation, preliminary cleaning of, 64

Fisher, Dr. W. A., 80

Fixation forceps, 72

Flap of Czermack, 84, 85

Forceps, capsule, 160
fixation, 72
Hess's, 98
how to hold, 72
Kalt's, 123
pneumatic, Barraquer's, 56, 116

Freedland, Fergus, 221

Freytag, 277
Fuchs, Prof. Elder, 146

G

Gallemaerts, 136
Glaucoma, acute, complicating soft cataract, 15
as a late result of intracapsular extraction, 261
complicating cataract, 32
treatment of, 51
iridectomy in, 220
in traumatic cataract, 25
treatment of, 219
trephining in, 221
Gout, complicating cataract, 37
Graefe's knife, 71, 75, 84

H

Hard cataract, 16
Heister, 277
Herman, 206
Hess forceps, 98
iridectomy, 97
Herbert, 221, 222
Holland, Dr. H T., 213
Hulen, Dr. Vard, 159
Hutchinson, Sir Jonathan, 205
Hyaloid, blood staining of the, 262
Hypermature cataract, treatment of, 50

I

Immature cataract, treatment of, 43
Incision and ambidexterity, 81
Barraquer's, 88
Czermack's, 86
Daviel's, 88
Knapp's, 88
making the, in intracapsular extraction, 74

Incision—(*Contd.*)
on the left eye, 81
proper, its value in extraction, 79
the situation of, 82
the size of, in intracapsular extraction, 86
Indian method of expression of lens, 102
Inflammatory reaction and intracapsular extraction 262
Instruments, sterilization of, 62
Interstitial keratitis, 228, 232
Iridectomy, justification of, 89
in cataract complicated by glaucoma, 51
Hess's, 97
in glaucoma, 220
some technical points *re.*, 223
the technique of, 66
Iridocylitis, 179
Iris, prolapse of, 177
methods of prevention, 91
Iritis, pathology of, 224
treatment of, 225

J

Juveniles, cataract in, 22
treatment of, 54

K

Kalt forceps, Author's view of, 123
Keratitis, interstitial, 228, 232
punctata, 225
Knapp, Dr. Arnold, 211
original article of, 258
incision of, 88
and the use of capsule forceps, 116
Knife, Afghan war, 71
Graefe's, 71, 75, 84
how to hold, 72

L

La Fay of Paris, 206, 279
La Grange of Bordeaux, 220
La Grange's operation, 224
in cataract complicated by glaucoma, 51
Landolt's optotype, 244
Lasnier, Capt., 264
Leeches in the treatment of cataract, 25
Lens, capsule, strength of the, in facœnsis, 140
couched, 128, 206
complicating cataract, 36
couching, the history of, 201
dislocation of, in the capsule, 99
delivery as a "tumbler," 110
expression of, 67
Indian method of, 102
hard, evolution of alternative technique for, 114
method of expression from without, 102
removal of in the capsule, 99
soft, delivery of, 110
upright, delivery of, 104
Lids, the closure of, after operation, 124
Light, the recognition of, 5
Lister, Capt. A E., 242

M

Malingering with night-blindness, 7
Manchard, Prof. M, 278
Mature cataract, treatment of, 50
McKeown's douche, 167
McNamara, Col M. C, 207
Mercury, cyanide of, 39, 40, 230
oxycyanide of, 40
perchloride of, 65
in traumatic cataract, 25
Morgagnian cataract, hypermature type, 16
lens, delivery of, 110
Molroney, Col, 209
Myopia, 41, 60
high, complicating cataract, 36

N

Nasal sepsis and cataract, 29
Needling in after-cataract, 45, 194
cataract complicated by glaucoma, 52
immature cataract, 49
Night-blindness with cataract, 34
as a source of malingering, 7
reaction of pupil in, 6
Novocain, 61, 92

O

Opacity, corneal, 31, 228, 231
Operating table, 62
Ophthalmia, sympathetic, 23, 222
Ophthalmoscopy, indirect, 11
Opium pupil, characteristics of, 13
Optotype, Landolt's, 244
Oral sepsis and cataract, 29
Orbicularis, control of the, 65
control, Author's claims *re*, 70

P

Pagenstecher, 206
Palucci, M, 279
Pannus, 228, 231
Post-operative care *re.*—
dressings and bandages, 173
diet, 175
drugs, 175

Post-operative care *re.*—(*Contd.*)
friends and relatives, 175
posture, 174
spectacles, 176
time of discharge, 176
Posterior synechiæ and cataract, 32
Potassium bromide, 59, 94
Poyet, M., 279
Preparation of patient before operation, 59
Presbyopia, 38
Prolapse of iris and Czermack's operation, 84
Pump, vibratory, 129
description of, 130
working of, 131
Barraquer's, 145
Pupil, reaction of, 5, 6
in night-blindness, 6

Q

Quinine urea-hydrochloride, 92

R

"Rawals," 201
Retina, detachment of, 262
Retinal disease with cataract, 34
scotomata, 35
Retinitis pigmentosa, 262
pigmentosa sine pigmento, 37
Rhases, 276
Richter, A. C., 206
Ripening, artificial, of cataract, 47

S

Scissors, De Wecker's, 66
Sclerectomy, anterior, 220
Scotomata, retinal, with cataract, 35
Sedatives before operation, 59
Sepsis, nasal, and cataract, 29
oral, and cataract, 29
Silver nitrate, 26
Snellen's test-types, 243
Soft cataract (*see* Cataract, Morgagnian)
Speculum, selection of, 64
Stanceleau, 99
Statistics of cataract extraction, 212
Sterilization of instruments, 62
Stoewers, 159
Sympathetic ophthalmia, 23, 222
Synechiæ, posterior, 226
of old iritis complicating cataract, treatment of, 51

T

Table, operating, 62
Talking to patient during operation, 70
Taylor, M., 277
Tension, estimation of, 4
Test-types, Snellen's, 243
Toilet of wound after operation, 123
Trachoma, treatment of, 226
Traumatic cataract, 23
atropine in, 24, 25
cocaine in, 24
complications of, 23
glaucoma in, 25
leeches in, 25
mercury in, 25
treatment of, 24
types of, 23

Trephining in glaucoma, 221
True cataract, 265

U

Ulceration, corneal, 228, 229
Urra, Munoz, 260

V

Vacuum apparatus, Down's, 143
Van Saretenb, 227
Van Suriten, 277
Von Graefe, 219
Von Mahrenheim, 206
Vision, details of, in intracapsular extraction, 237
distant, gradual failing of, 10, 38
Vitreous, escape of, 274
after-effect of, cases analysed, 251
tabulated reports of, 242
during operation, 126

W

Walken, M., 278
Wound, toilet of, after operation, 123
Wright of Columbus, 209

Y

Young adults, cataract in treatment of, 22

Z

Zonule, strength of the, in facœrisis, 141